

# Managing children with Thickened Pituitary Stalk (TPS) and/or Idiopathic Central Diabetes Insipidus (ICDI): A Single Centre Experience on 63 children

<sup>1</sup>Manuela Cerbone, <sup>2</sup>Ash Ederies, <sup>1</sup>Laura Losa, <sup>1</sup>Carolina Moreno, <sup>1</sup>Kristi Sun and <sup>3</sup>Helen A Spoudeas

<sup>1</sup>London Centre for Paediatric Endocrinology, Neuroendocrine Division, University College and Great Ormond Street Hospitals, London, UK, <sup>2</sup>Neuroradiology Department, Great Ormond Street Hospital, London, UK

## BACKGROUND

Children with TPS and/or ICDI present to different (endocrine, oncology, ophthalmology) specialists. Their rarity, absence of agreed radiological criteria or consensus guidance, make their management (to exclude an occult malignancy) problematic. Biopsy is too dangerous and cases may remain undiagnosed or evolve over decades.

## OBJECTIVE

1. to longitudinally characterize a large childhood cohort presenting with TPS and/or ICDI
2. to assess clinical, visual and endocrine correlates over time

## PATIENTS AND METHODS

### SEARCH CRITERIA:

We searched the terms “thickened pituitary stalk” or “idiopathic diabetes insipidus” in electronic radiology and clinical document libraries at our split-site centre (UCLH/GOSH) over the last 30 years.

### PATIENTS:

Data from 63 patients presenting with TPS (n:12), ICDI (n:20) or both (n:32) were collected and MRI scans reviewed.

In 9 patients the diagnosis was clear at presentation. Within the remaining 54 occult cases: 10 had TPS, 18 ICDI and 26 TPS+ICDI.

## RESULTS

- Patients with TPS were older at presentation than those with ICDI and TPS+ICDI ( $p < 0.04$ ) (Table 1).
- Tissue histology was available only in 10 to 37.5% of patients. A “watch and wait strategy” was adopted in the majority of TPS patients and in half of TPS+ICDI patients (Table 1).
- TPS+ICDI patients were more likely (38.5%) than ICDI (5.6%) and TPS (none) to have histiocytosis. Tumours were identified in 26.9% TPS+ICDI and 27.9% ICDI,  $1.0 \pm 1.4$  and  $1.9 \pm 2.4$  years later respectively, but not in TPS. 80% TPS cases remained unexplained (vs 61.1% ICDI and 34.6% TPS+ICDI) at a shorter follow-up (Figure 1).
- Patients’ main presenting features are shown in Figure 2.
- Multiple anterior pituitary deficits evolved with time across groups (GHd, 45-58%, TSHd 19-30%, ACTHd 13-21%, GnRHd 7-17%) but visual deficits, present in 8-23% at presentation, increased only in TPS+ICDI (7.6 to 34.6%) (Table 2).

TABLE 1

	TPS	ICDI	TPS+ICDI	p value
N	10	18	26	
M/F	4/6	7/11	15/11	ns
Age at presentation (mean±SE) (years)	9.8±4.9	5.5±4.4	6.2±3.4	<0.04
Age at last follow-up (mean±SE) (years)	13.1±5.9	11.4±6.6	13.8±5.0	0.0004
Length of follow-up (mean±SE) (years)	2.5±1.6	5.2±5.1	5.8±3.9	<0.08
Tissue histology available (biopsy or surgery) (%)	10	22.2	37.5	ns
Watch and wait strategy (%)	90	72.2	53.8	ns

FIGURE 1

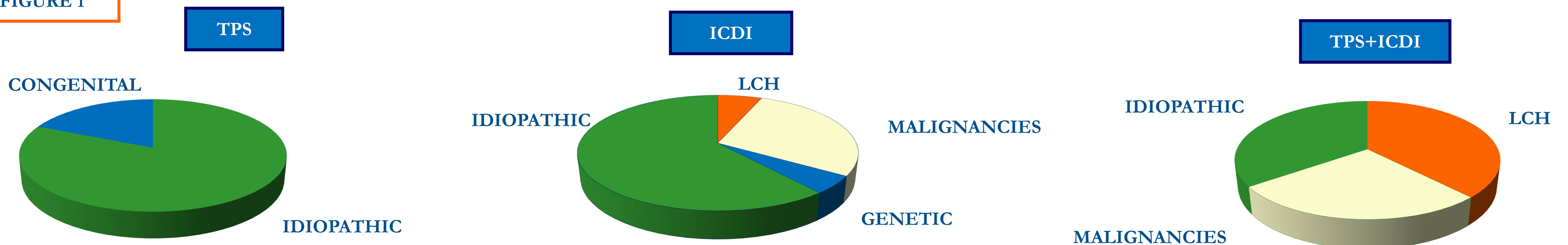


FIGURE 2

Main presenting features within the 3 groups

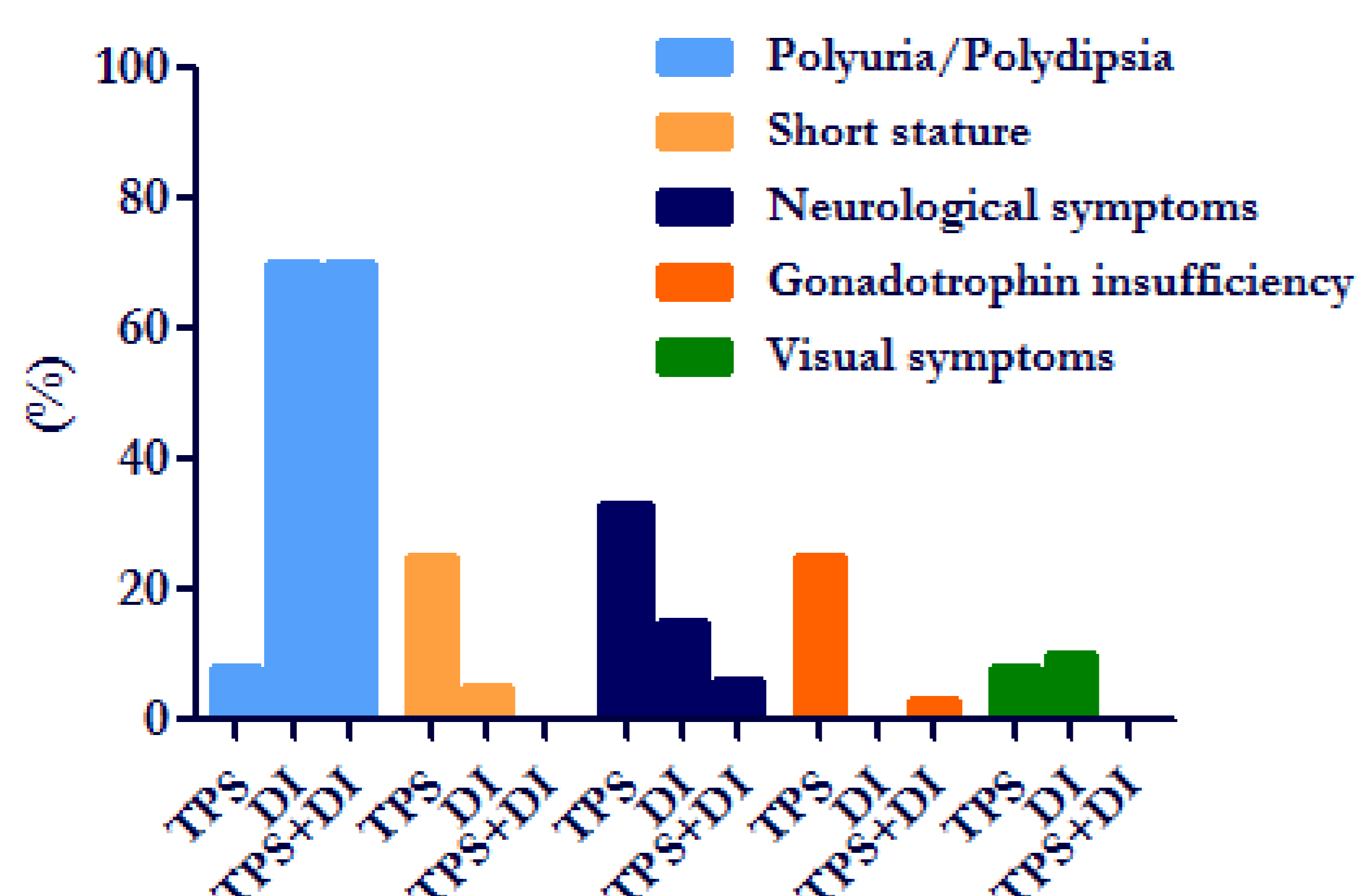


TABLE 2

Endocrine and visual details within the 3 groups

	TPS	ICDI	TPS+ICDI
Visual deficits at presentation (%)	10	22.3	7.6
Visual deficits at last follow-up (%)	10	22.3	34.6
<i>Endocrinology at endocrine assessment</i>			
GHd (%)	62.5	33.3	41.7
ACTHD (%)	-	13.3	25
TSHD (%)	-	26.7	29.2
DI (%)	-	100	96.2
GnRHd (%)	-	-	20.2
Hyperprolactinemia	11.1	6.7	8.3
<i>Endocrinology at last follow-up</i>			
GHd (%)	62.5	41.2	70.8
ACTHD (%)	-	29.4	33.3
TSHD (%)	12.5	33.3	42
DI (%)	12.5	100	100
GnRHd (%)	14.3	6.3	29.2
Hyperprolactinemia	-	-	4.2

## CONCLUSIONS

Longitudinal endocrine and visual assessment of all patients with TPS and ICDI is important. ICDI is a negative prognostic factor for malignant disease, whilst the combination with TPS is more often associated with histiocytosis. TPS alone is unlikely to lead to malignancy but should be prioritized for endocrine follow-up.