

Anthropometry and glucose homeostasis in a patient with Donohue Syndrome: effect of continuous subcutaneous rIGF-I therapy

Plamper M¹, Schreiner F¹, Gohlke B¹, Woelfle J¹

¹Pediatric Endocrinology und Diabetology Division, Children's Hospital, University of Bonn, Germany



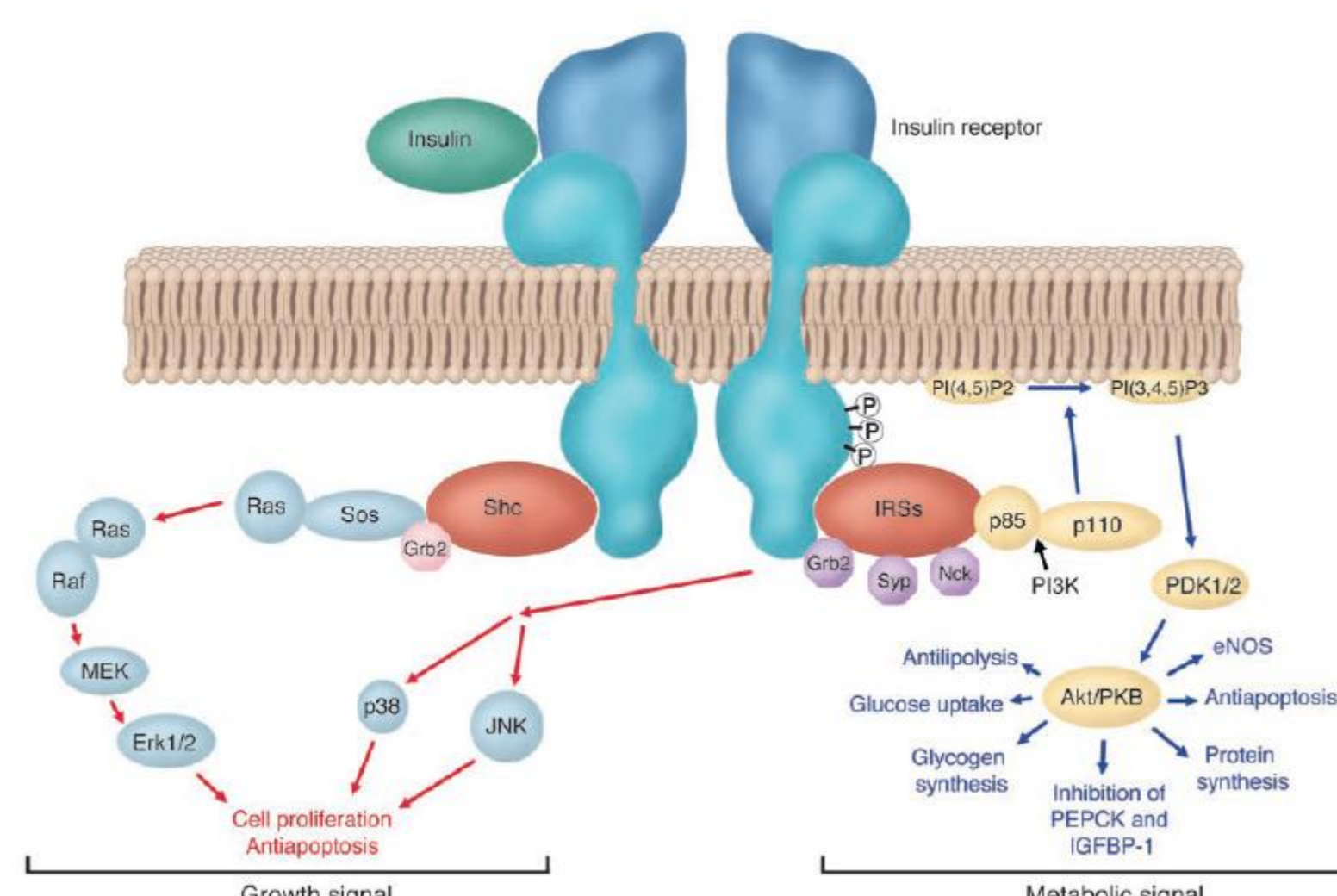
Conclusion

Using subcutaneous rIGF-I (mecasermin) application we observed a significant improvement in glucose homeostasis and a moderate weight gain in a patient with Donohue Syndrome. We therefore suggest that a trial with continuous mecasermin application via insulin pump should be considered in patients with homozygous insulin receptor mutations and poor disease control under BID or TID rIGF-I treatment.

Background

Donohue Syndrome (DS) is caused by autosomal-recessive loss of function mutations of the insulin receptor gene. It is associated with diabetes mellitus unresponsive to conventional insulin therapy due to most severe insulin resistance. Patients exhibit IUGR and postnatal failure to thrive. They develop a characteristic facies, hypertrichosis and acanthosis nigricans. Insulin secretion is elevated, postprandial hyperglycemia is sometimes followed by fasting hypoglycemia. Most patients die within the first two years of life, because of respiratory infections. To date, no causal therapy is available.

Insulin receptor



Van den Berghe G, J Clin Invest. 2004

Case report

The patient was born at term in Libya with a birth weight of 1300g. Postnatally, he developed postprandial hyperglycemia. Despite high-caloric nutrition he exhibited severe and progressive dystrophy. Mutation analysis revealed a homozygous mutation (591delC);p.(A198Pfs*84) in exon 2 of the INSR gene.

Diagnosis: loss of function mutation of the insulin receptor gene → **(Donohue syndrome)**

Presentation in our hospital was at 12 month of age with a weight of 3300 g. HbA1c was 10%, IGF-I and IGF-BP3 were below detection limits.

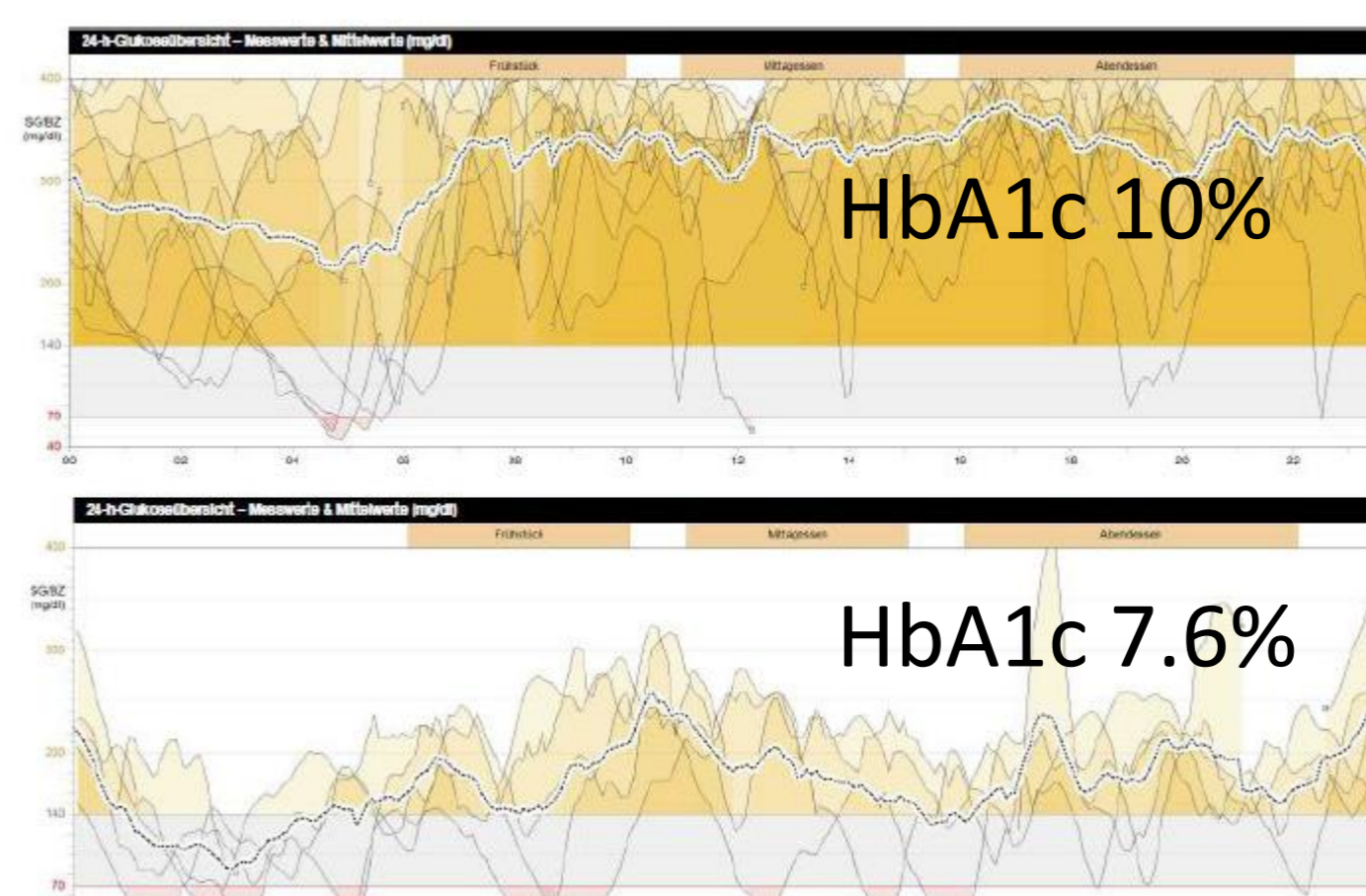
We started a probatory therapy with rIGF-I (mecasermin) s.c. twice daily (max. 0.5 mg/kg/d).

Since we were unable to achieve satisfactory glucose control we decided to switch towards continuous subcutaneous rIGF-I therapy via insulin pump. Mecasermin dosage was adapted throughout the day (total 1.8 mg/day). A critical adverse effect of this regime was the development of adenoid hyperplasia, requiring adenotonsillectomy after 9 months of therapy. Within this time, we saw an improvement of HbA1c from 10 to 7.6% and a weight gain from 3.3 to 5.2 kg body weight. Unfortunately, the patient died at an age of 23 months in Libya during the course of a respiratory infection.

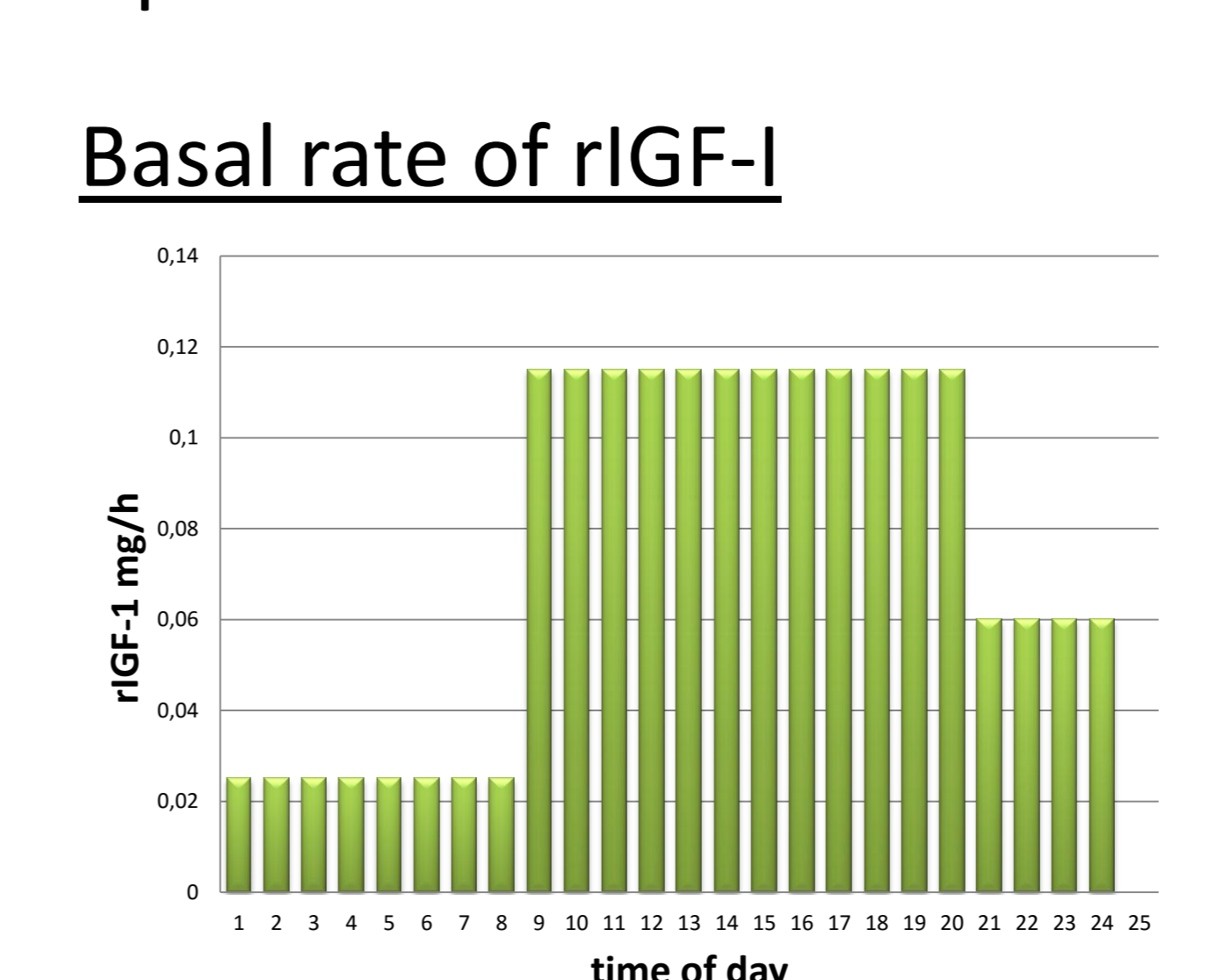
Glucose homeostasis during treatment

CGMS measurement

December 2013



September 2014



rIGF-1 therapy

2.5 mg (=0.25 ml) r-IGF I (10 mg/ml) and 1.25 ml physiological salt solution were mixed, so that 2 mg rIGF-I in an insulin pump reservoir corresponded to 120 IE. An rIGF-I basal rate was programmed.

Dosage was 1.8 mg rIGF-I/24 h (dependent on actual weight between 0.55 mg/kg/d and 0.34 mg/kg/d). IGF-I values and electrolytes during rIGF-I therapy were always within normal range.