

Sleep-Related Breathing Disorders in Pycnodysostosis

*Serap Turan*¹; *Zeynep Atay*¹; *Yasemin Gökdemir*²; *Nilay Bas*², *Belma Haliloğlu*¹; *Saygın Abalı*¹; *Serpil Baş*¹; *Refika Ersu*²; *Abdullah Bereket*¹

Marmara University, ¹Pediatric Endocrinology, ² Department of Pediatric Pulmanology

Istanbul, Turkey

Background

Pycnodysostosis is an autosomal recessive disease characterized by short stature, osteosclerosis, acroosteolysis, increased bone fragility and characteristic facial features (Figure 1).

In these patients maxillary and mandibular hypoplasia, flattening of the mandibular angle, long soft palate, narrow palate structure can lead to pharyngeal narrowing and obstructive sleep apnea syndrome (OSAS) (Figure 2).

Objective

To evaluate sleep disordered breathing in children with pycnodysostosis.

Method

Demographic data, pediatric sleep questionnaire (PSQ) scores, polysomnography results and treatments of pycnodysostosis patients who were followed by Pediatric Endocrinology Department in Marmara University were evaluated.

Results:

Patients: 7 girls, one boy with genetically proven pycnodysostosis

- Mean age was 12.2 ± 4.2 years
- Mean age at diagnosis was 6.5 ± 4 years
- Habitual snoring was reported in 7 (87%) patients
- Apnea during sleep was reported in 3 (37.5%) patients
- Two patients had adenoidectomy and one had tonsillectomy.
- 4 patients (50%) received growth hormone.

- Mean PSQ score: 0.41 ± 0.19 (Normal <0.33)
- Polysomnography: OSAS in 6 patients (75%)
 - ✓ 2 (25%) severe
 - ✓ 4 (50%) mild
 - ✓ In 5 of 6 patients with PSQ score greater than 0.33
 - ✓ 1/2 patients with PSQ score less than 0.33: mild OSAS
- OAHl (Obstructive Apnea Hypopnea index) ranged between 0-15.1 (median 2.9)
(1-5; mild, 5-10; moderate, >10; severe)
- Mean SpO₂ value: $94.5 \pm 1.6\%$
- Lowest SpO₂ value was $90.5 \pm 3.5\%$
- BPAP was started in 3 patients

A

B

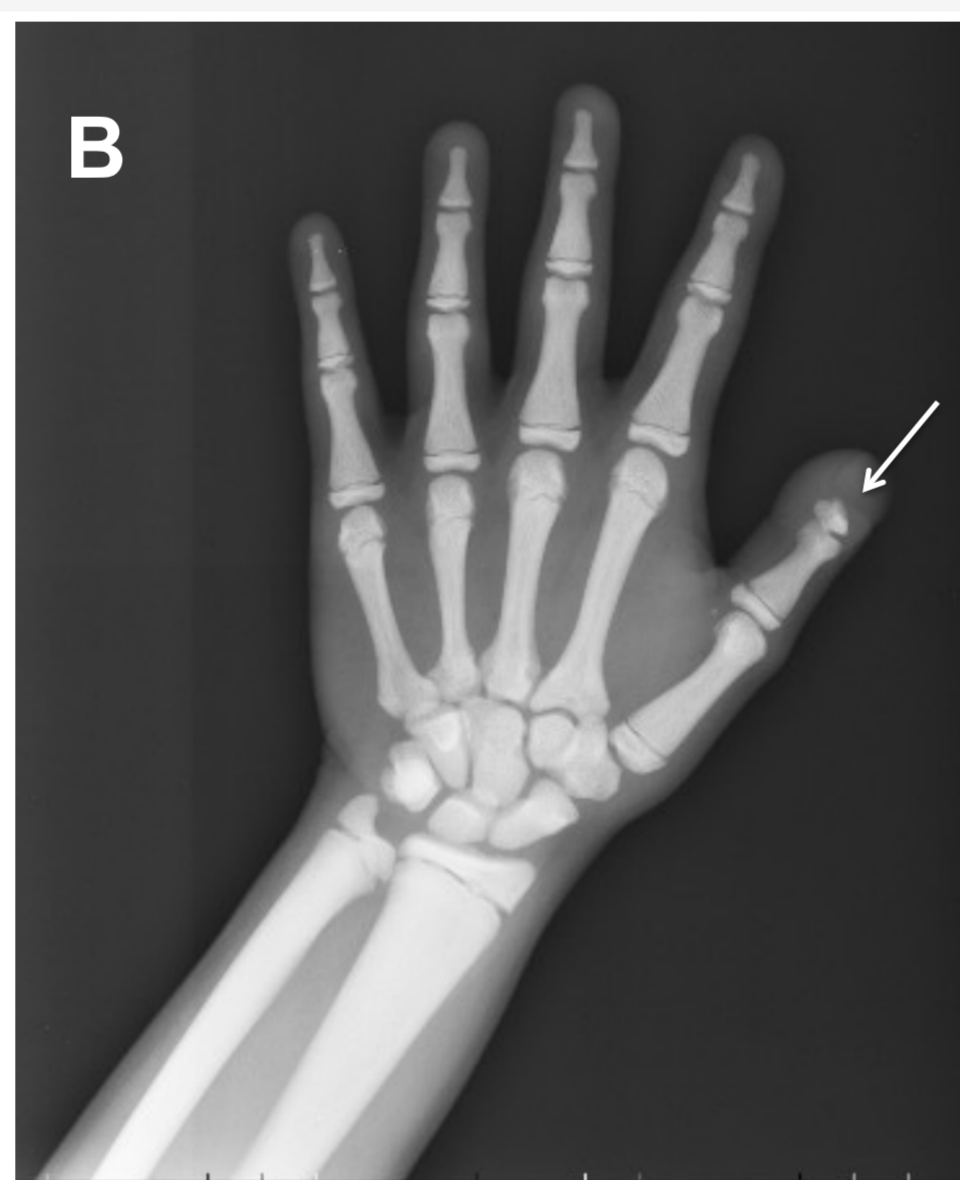


Figure 1: A-Dysmorphic facial features of the patient with pycnodysostosis. Please note maxillary and mandibular hypoplasia, prominent forehead and beaked nose. B-Skeletal features of pycnodysostosis: Osteosclerosis and acro-osteolysis (Arrow).

Figure 2: Oral features in Pycnodysostosis: crowding of the teeth due to maxillary and mandibular hypoplasia, long soft palate, narrow palate causing respiratory obstructive problems and chewing problems as well

Conclusion

Sleep related breathing disorders are frequent in pycnodysostosis and although PSQ can be used to screen, polysomnography should be offered to all patients with pycnodysostosis