

# Growth Hormone Deficiency (GHD) in a child with de novo 2q31.1 microdeletion

I. Kaloumenou<sup>1</sup>, F. Karachaliou<sup>1</sup>, E. Vlachopapadopoulou<sup>1</sup>, A. Fotinou<sup>2</sup>, S. Michalacos<sup>1</sup>

<sup>1</sup>P & A Kyriakou' Children's Hospital, Endocrinology Department-Unit Growth and Development

<sup>2</sup>P & A Kyriakou' Children's Hospital, Microbiology, Athens, Greece

## Background

•The clinical phenotype of the chromosome 2q31 deletion syndrome consists of a variety of limb abnormalities and other skeletal defects, craniofacial dysmorphic features, developmental delay, generalised hypotonia, short stature and other not specific internal organ anomalies, heart and brain defects, ocular and urogenital anomalies.

•Remarkably, the spectrum of upper/lower limb anomalies can range from ectrodactyly/monodactyly through syndactyly, brachydactyly to camptodactyly or clinodactyly.

## Objective and Hypotheses

To describe a patient with 2q31.1 microdeletion syndrome and short stature, diagnosed with growth hormone deficiency.

## Methods

• We describe a 5 ys and 4 months girl with generalized developmental delay, growth retardation, short stature, motility disorders, mild tremor upper limb, craniofacial dysmorphic features (microcephaly, high arched palate, downslanting palpebral fissures, micrognathia).

• She had moderate intellectual disability with slow developmental milestones.  
• She was unable to concentrate and therefore attended special education.

•She is the first child of healthy and non-related parents and she was born by caesarean section at the 35<sup>th</sup> week of gestation. Birth weight was 2.380 kg, length 47 cm and head circumference 32.5 cm.

•She had a surgery for strabismus at the age of 1 year and urinary reflux stage III at the left kidney and no heart defects.

•Radiographs of the hands and feet showed camptodactyly, clinodactyly of the fifth fingers of the upper extremities, bilateral hypoplastic middle phalanges particularly of the fifth fingers of the upper and lower extremities and low degree of syndactyly.

• **MRI imaging** revealed a complex brain anomaly with mild hypoplasia of the right cerebellar hemisphere, slight abnormality of the upper vermis lobules without typical features of cortical dysplasia and a projection portion of the right temporal lobe at the level of the superior cerebellar tank.

•EEG sleep was normal

•She was referred to our endocrinology department because of the severe growth retardation and more specifically short stature (weight: 12.8 kg <P3, height: 99 cm <<P3, head circumference: 45 cm <<P3).

## Results

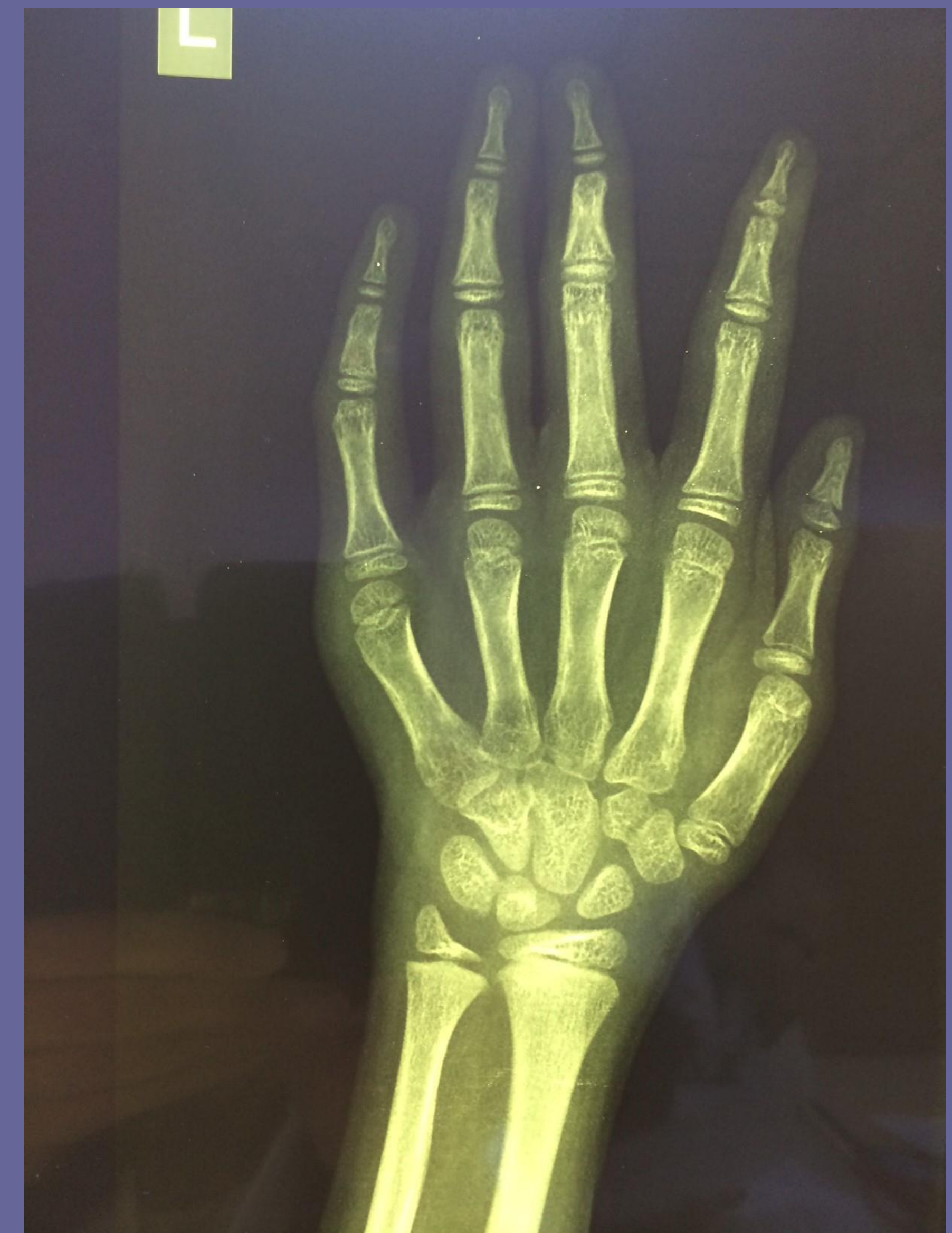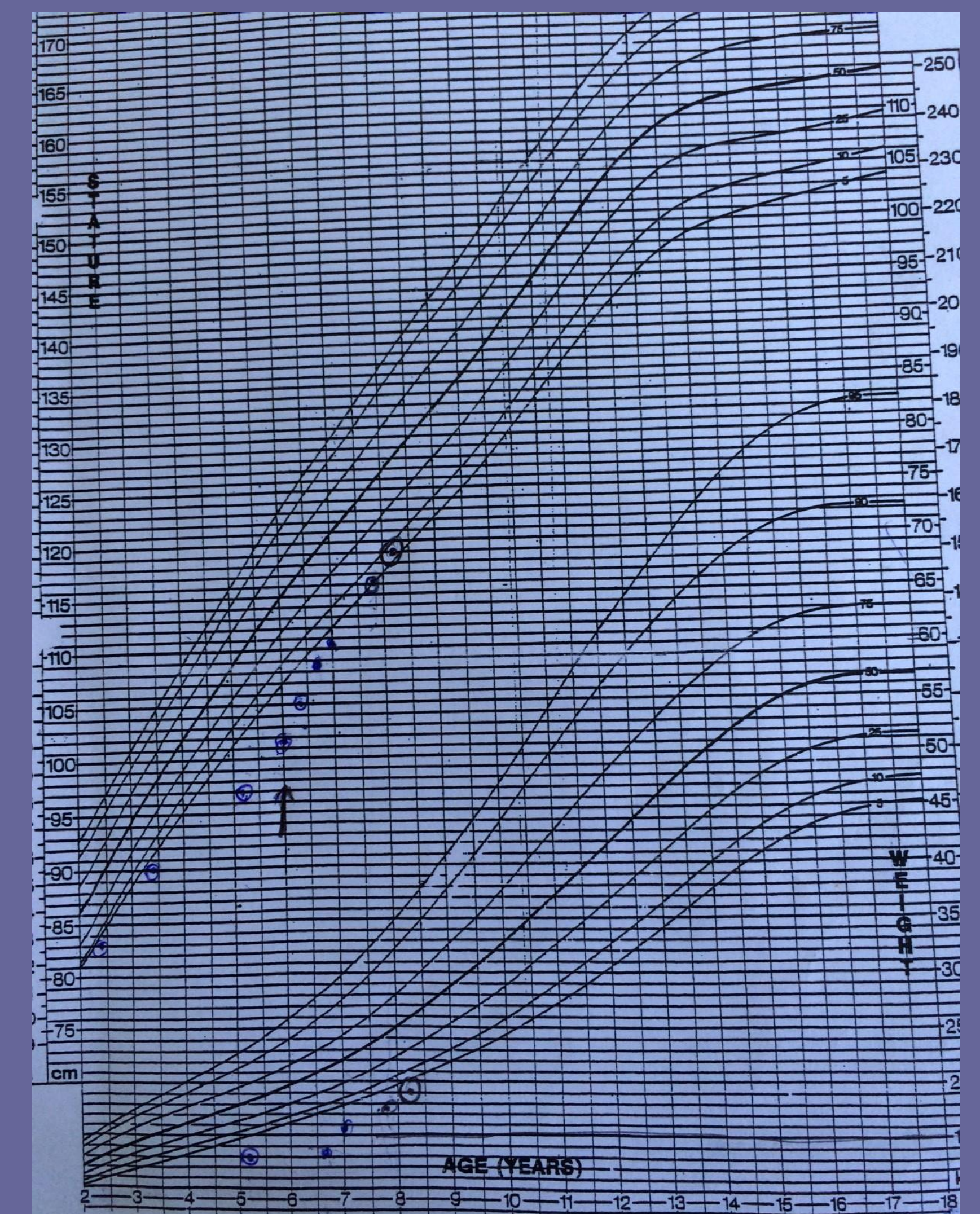
No chromosomal abnormalities were detected by conventional karyotyping 46, XX. Array CGH revealed a de novo 2q31.1 microdeletion.

•Endocrinological evaluation revealed Growth Hormone Deficiency.

•She was started on recombinant growth hormone (160 µg/kg/week) and during the first 8 months of treatment she showed an increase in height velocity from a pretreatment value of 3.5cm/y to 9cm/y (NCHS Growth Charts).

### REFERENCES

1. Dimitrov B, et al 2q31.1 microdeletion syndrome: redefining the associated clinical phenotype. J Med Genet 2011.
2. Boles RG, et al Deletion of chromosome 2q24-q31 causes characteristic digital anomalies: case report and review. Am J Med Genet 1995
3. Goodman FR, et al 117-kb microdeletion removing HOXD9-HOXD13 and EVX2 causes synpolydactyly. Am J Hum Genet 2002
4. Svensson AM, et al Detection of a de novo interstitial 2q microdeletion by CGH microarray analysis in a patient with limb malformations, microcephaly and mental retardation. Am J Med Genet A 2007.
5. Dimitrov B, et al 2q31.1 microdeletion syndrome: redefining the associated clinical phenotype. J Med Genet 2011.
6. Pescucci C, et al 2q24-q31 deletion: report of a case and review of the literature. Eur J Med Genet 2007



## Conclusions

• Hormonal evaluation and more specific growth hormone assessment is crucial for patients with chromosome impairment and short stature.

• In the literature there are published almost 40 patients with this syndrome. 2q31.1 microdeletion is a well defined and clinically recognizable contiguous gene syndrome mapped to a specific genomic locus with specific clinical features that can lead to the appropriate diagnosis.

• In recent years, the spectrum of available methods for the characterization of chromosomal aberrations has significantly increased. Micro-array technologies now allow the rapid fine mapping of small genomic imbalances, as it was in our case.

• We describe this case because of the rarity of this syndrome and its association with growth hormone deficiency, which to the best of our knowledge has not been reported before.