

A Pediatric Case Of Cushing's Disease Presenting With Diabetic Ketoacidosis

Gonul Catli^a, Ozgur Tanrisever^b, P Sule Can^a & Bumin Nuri Dundar^{a,c}

^aPediatric Endocrinology Unit, Tepecik Training and Research Hospital, Izmir, Turkey; ^bDepartment of Pediatrics, Tepecik Training and Research Hospital, Izmir, Turkey, ^cDepartment of Pediatric Endocrinology, Katip Celebi University, Izmir, Turkey

BACKGROUND

Cushing syndrome (CS) is a rare endocrine disorder in childhood with an incidence of 2-5 per million. In childhood the most common cause of CS is the administration of high dose topical, inhaled or oral corticosteroids. The major cause of endogenous Cushing syndrome is Cushing's disease, which results due to excessive ACTH secretion from pituitary cells (corticotroph adenoma).

AIM

Diabetes mellitus (DM) accompanying CS is frequently (20-60%) reported in adult studies; however, this association is unusual in childhood. Although diabetic ketoacidosis (DKA) is rarely reported in adults with CS, up to now, pediatric CS presenting with DKA has not been reported. In this report, we describe a pediatric case of Cushing's disease presenting with DKA

CASE REPORT

A 16-year-old adolescent girl presented with the complaints of polyuria, polydipsia, weight gain, and amenorrhea.

On physical examination;

Weight: 95 kg (>95p, 2.19 SDS),

Height: 158 cm (10-25p, -0.71 SDS),

BMI:38.1 kg/m² (>95 p, 2.32 SDS).

•She had moon face appearance, buffalo hump, purple colored striae on the skin and acanthosis nigricans.

On laboratory examinations,

•Hyperglycemia (venous blood glucose= 556 mg/dL),

•Metabolic acidosis (PH: 7.13, HCO₃: 7.5 mmol/L)

•Urine, ketonuria (3+) and glucosuria (3+).

•HbA1c: 10.4%, C-peptide: 11.4 ng/mL (normal, 0.9-7.1).


•Anti-insulin and anti-glutamic acid decarboxylase were negative.

Treatment

Based on these clinical and laboratory findings the patient was diagnosed with DKA. After the recovery of ketoacidosis by intravenous hydration and regular insulin infusion (0.1 IU/kg/h), intensive insulin treatment with insulin Lispro and insulin Glargine was initiated and metformin (2x1000 mg) was added.

Diagnosis

Obesity+ Diabetes Mellitus + Clinical features of Cushing syn.



Suspected of Cushing Syndrome (figure 1)

Progress

After glycemic control was achieved, a transsphenoidal adenomectomy was performed. After transsphenoidal surgery the patient was weaned off insulin and her diabetes was under control with diet and metformin treatment.

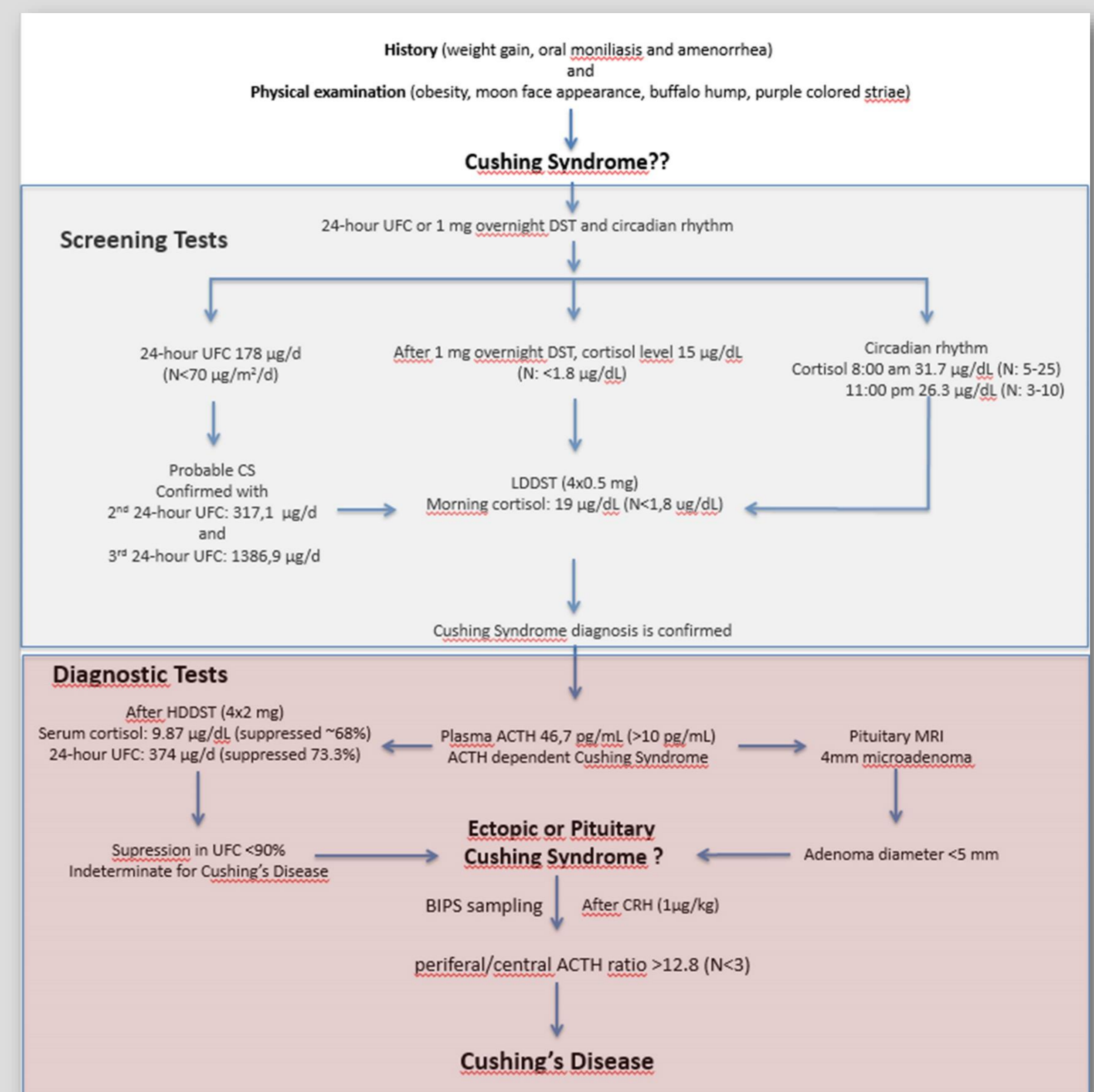


Figure 1. Diagnostic work-up of the patient

UFC: urinary Free Cortisol, DST: Dexamethasone Suppression Test, LDDST: Low Dose Dexamethasone Suppression Test, HDDST: High Dose Dexamethasone Suppression Test, MRI: Magnetic Resonans Imaging, BIPS: Bilateral Inferior Petrosal Sinus

DISCUSSION

- On pancreatic beta cells glucocorticoid receptors are present and glucocorticoids were shown to cause beta cell dysfunction and reduce insulin sensitivity.
- Diabetes occurs as a consequence of an insulin-resistant state together with impaired insulin secretion, which are induced by glucocorticoid excess.
- Commonly, infectious diseases or ingestion of large volumes of sugar-containing soft drinks are proposed to lead to diabetic ketosis or ketoacidosis in patients with CS.

In our patient we hypothesize that increased counter regulatory hormones (cortisol) which cause an acute halt of insulin secretion by temporary pancreatic beta islet dysfunction in addition to insulin resistance could have led to the development of DKA.

CONCLUSION

Although rare in childhood and adolescence, CS should be considered in the differential diagnosis of patients who present with signs of obesity and diabetes. With this report, we emphasize that related to the duration of hypercortisolemia, children with CS may also present with diabetes and DKA.