

# Subcutaneous fat necrosis causing prolonged hypercalcaemia in a neonate: An unusual case

U. Niranjana<sup>1</sup>, N. Brooke<sup>2</sup>, V. Desai<sup>2</sup>, A. Natarajan<sup>2</sup>

Sheffield Children's Hospital NHS Trust<sup>1</sup>, Doncaster Royal Infirmary<sup>2</sup>

## Introduction

Subcutaneous fat necrosis (SCFN) is an uncommon inflammatory disorder of the adipose tissue. Hypercalcaemia secondary to SCFN is a well recognised entity but reported cases with persistence of symptoms requiring prolonged treatment as in our case are rare.

We present a neonate who developed severe hypercalcaemia secondary to subcutaneous fat necrosis at 2 weeks of age which proved difficult to manage until 7 months of age.

## Case report

The term baby (4.3kg) had significant hypoxia (pH 6.8) at birth with meconium aspiration requiring intensive care treatment.

On day 10 she was noted to have firm palpable subcutaneous erythematous plaques all over her back suggestive of Subcutaneous fat necrosis.

Her bloods revealed hypercalcaemia (aCa 3.05mmol/L) and she required intravenous fluids, diuretics and low calcium milk (locasol).

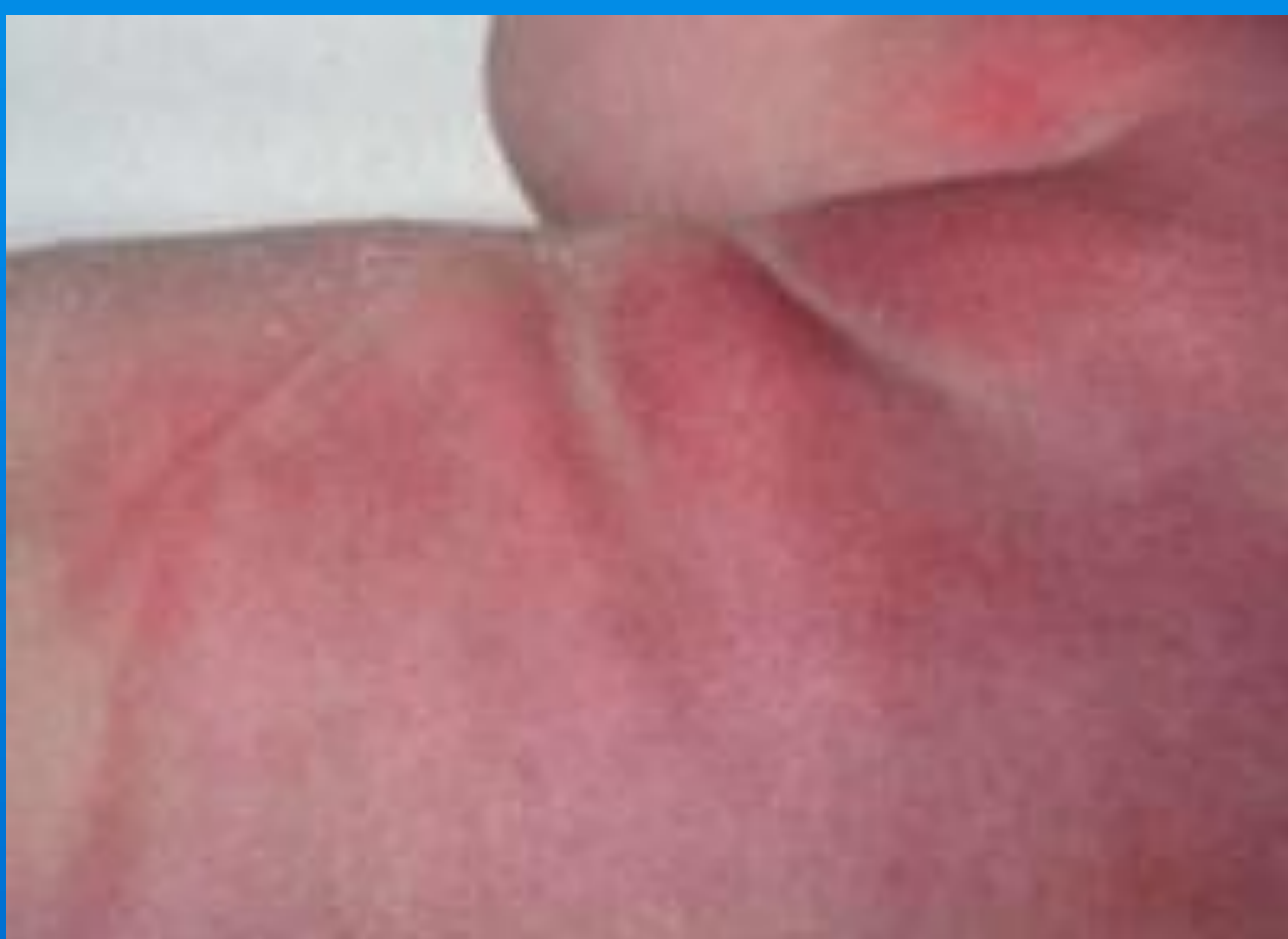

Fig 1 – Subcutaneous fat necrosis – erythematous plaques

Permission obtained from parents for the pictures

## Investigations

Test	Result	Test	Result
Corr Ca <sup>+</sup> (mmol/L)	3.91	PTH (pmol/L)	2.6
PO <sub>4</sub> (mmol/L)	1.8	25 – OH Vit D (nmol/L)	85.9
Alk phos (IU/L)	174	1,25- dihydroxy Vit D (pmol/L)	155.9

- Renal USS was normal.
- Investigations to rule out other causes of hypercalcemia were normal.

## Diagnosis

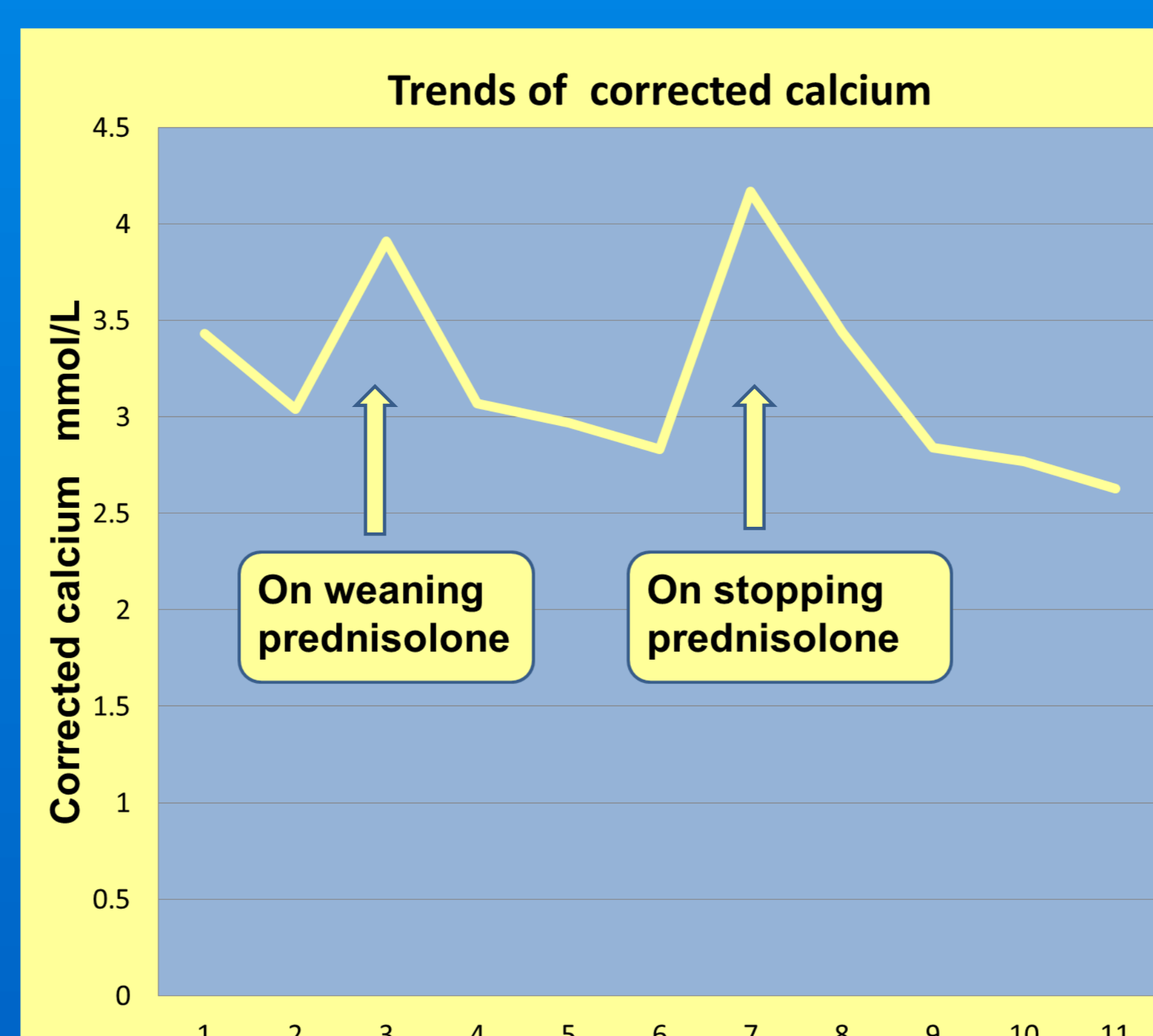
Extremely high 1,25 Dihydroxy vitamin D levels with hypercalcemia and clinical presentation confirmed her diagnosis of subcutaneous fat necrosis.

## Treatment

She was treated with prednisolone (2mg/kg/day) in addition to low calcium milk (Locasol) due to persistent hypercalcaemia (aCa 3.53mmol/L) with good effect.

Attempts to wean her from prednisolone resulted in recurrence of hypercalcaemia (aCa 4.17 mmol/L)

## Trends in Calcium levels in our case



## Treatment

She required close monitoring of her calcium levels and regular renal ultrasound scans. Parent were informed to return for early assessment if she became symptomatic.

Eventually at 7 months the prednisolone and low calcium feed were weaned (latest Ca 2.83 mmol/L).

She is currently thriving with normal development. The skin lesions resolved completely at 7 months of age.

## Discussion

There are limited reports about the severity and duration of hypercalcaemia secondary to subcutaneous fat necrosis. There are suggestions that it may be related to the extensity of the skin lesions.

In our case the skin lesions resolved only by 7 months of age.

In resistant cases corticosteroids, calcitonin and bisphosphonates are the treatment of choice.

The reason for differing the use of bisphosphonates in this case was the exquisite steroid sensitivity which our patient demonstrated.

## Conclusions

Hypercalcaemia though rare, is a serious complication of subcutaneous fat necrosis.

It can present late or persist for a longer duration as in our case.

Prolonged follow up with diligent management is essential.

## References

- Akcay, Ahmet, et al. "Hypercalcemia due to subcutaneous fat necrosis in a newborn after total body cooling." *Pediatric dermatology* 30.1 (2013): 120-123.
- Zifman, Eyal, et al. "Subcutaneous fat necrosis and hypercalcemia following therapeutic hypothermia—a patient report and review of the literature." *Journal of Pediatric Endocrinology and Metabolism* 23.11 (2010): 1185-1188.