P1-D2-9

Mast cells in human adrenal gland during fetal development

[1]Naccache A, [1] Duparc C, [1]Louiset E, [2] Laquerrière A, [1]Lefebvre H, [1,3]Castanet M

[1]INSERM U982, Institute for Biomedical Research and Innovation, University of Rouen, Mont Saint Aignan; [2]Department of anatomo-pathology & [3]Pediatric Department, Charles Nicolle Hospital, Rouen, France;

mireille.castanet@chu-rouen.fr

ABSTRACT

We previously found that mast cells are expressed in human adult adrenal gland with a possible role in aldosterone secretion in adrenocortical neoplasms responsible for primary adrenal hyperaldosteronism.

To now investigate human developing adrenal gland for the presence of mast cells, immunochemistry studies were performed on paraffin-embedded adrenal glands from 16 weeks of gestation (WG) to the term.

Results: Tryptase positives cells were firstly detected at 20 WG with a peak of density at 28-31 WG. Double immunostaining with 3βHSD characterizing the definitive and transition zones and CYP17 (or 17 α-hydroxylase) characterizing the transition and fetal zones revealed that mast cells are mainly located in the subcapsular definitive zone with no correlation in term of timing of expression either with CYP17 present at all studied stages or with βHSD firstly detected quite earlier at 18 GW.

In addition, Shh positives cells were detected from the first studied stages and are co-localised with tryptase positive cells but still without correlations of kinetic expression.

In conclusion, we demonstrated for the first time, that mast cells are expressed in human fetal adrenal gland from the second trimester of pregnancy. However no clear evidence of relationship was found with steroidogenic enzymes and/or stem cells kinetic expression. Further studies need to be performed as investigation of CYPB2 expression to suggest an eventual role of mast cells in aldosterone production and to better understand the role of these intra-adrenal mast cells in the fetal development.

INTRODUCTION

Mast cells are known to be localized in adult adrenal gland.

We previously found that masts cells are much more prominent in adrenocortical aldosterone-producing adenomas and that they may play a role in aldosterone secretion through the serotonin signaling.

Similarities exist between normal fetal adrenal cortex and adrenal cancers, which probably occur through process of dysregulation and dedifferenciation.

Hypothesis

We thus hypothesized that mast cells could appear early during fetal adrenal gland development and might play a role in fetal aldosterone secretion.

Fetal adrenal gland development

The fetal adrenal cortex consist of a small outer definitive zone, and a larger inner fetal zone

a transitional zone between those 2 zones exist and produces cortisol towards the end of the fetal development.

Type of the steroidogenic hormone secreted in each zone is depending of the localization of the enzyme expression.

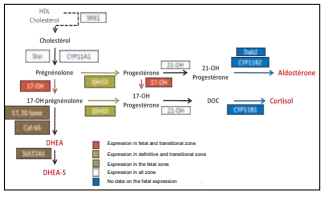

Aim of the study

We aimed to search for mast cells in human fetal adrenal gland and to analyze their localization and kinetic of expression to provide arguments in favor of mast cells involvement in fetal adrenal development.

Material and methods

Human tissue collection

Human fetal tissue (*n*=30) from 16 to 40 GW (gestational weeks) were collected from medical and surgical terminations of pregnancy and/or from premature infants died during the first days of life.

Specimens for immunohistochemistry were fixed within 4% paraformaldehyde before processing and embedding in paraffin wax. Sectioning took place at 5-µm intervals.

Immunochemistries

Immunochemistry studies were performed using the following antibodies according to our local protocols.

Antibodies	Specificity of immunostaining
Tryptase	Mast cells
CD34	Vascularisation
CD117	C-kit proto-oncogene
3βHSD	Definitive and transitional zones
17-OH	Fetal and transitional zones
CYP11B2	Aldosterone synthase
Ki67	Proliferation cells
Shh	Progenitor cells

RESULTS (1)

Mast cells expression in human fetal adrenal gland

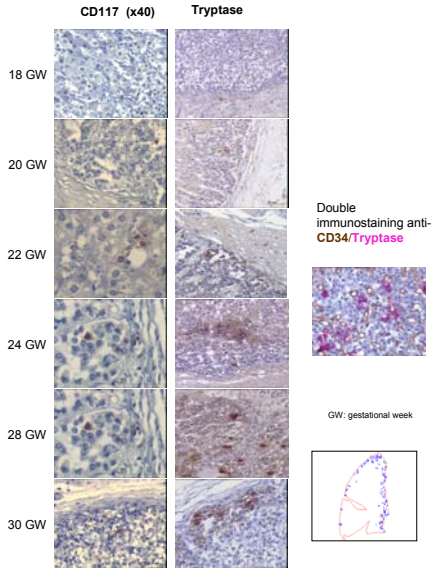

Tryptase immunostaining reveals mast cells in fetal adrenal gland from 20 GW localized in intra-tissular and subcapsular definitive zone

RESULTS (2)

Steroidogenic enzymes expression during human fetal adrenal gland

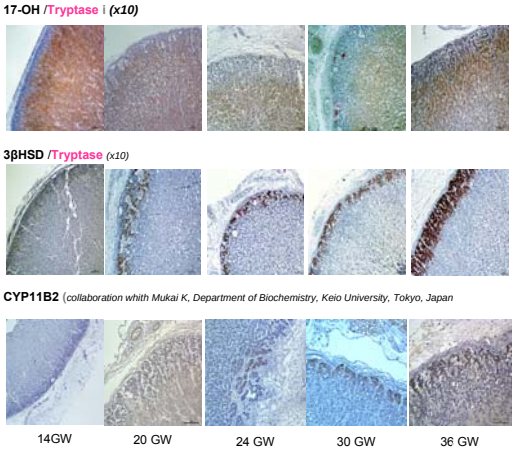

Tryptase immunostaining co-localizes with 3βHSD in the definitive zone where CYP11B2 is expressed from the 24th week of gestation.

Kinetic of mast cells and Ki67 expression during adrenal gland development

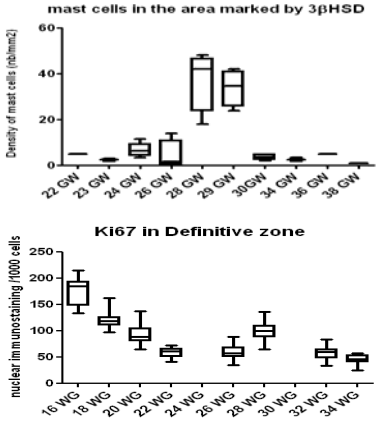

A pic of density of mast cells appears at 24-29th weeks of gestation, after the pic of proliferative markers expression.

Expression of progenitors cells and proliferative markers during fetal adrenal development

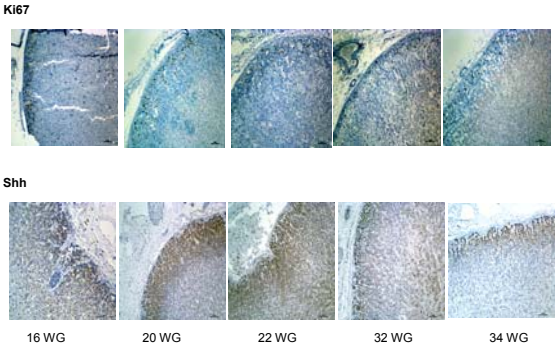

Shh and Ki67 are expressed in the 3 fetal adrenal zones from the first stage of gestation.

Shh expression moved to the subcapsular zone in the later stages of pregnancy.

CONCLUSION

		14 GW	16 GW	18 GW	20 GW	22 GW	24 GW	26 GW	28 GW	30 GW	32 GW	34 GW	36 GW	38 GW
Tryptase	ZD	-	-	+/-	+	+	++	+ ?	++	++	+	+	+	+
	ZT				+	+	+	+	+	+	+	-	-	-
	ZF	-	-	-	-	-	-	-	+	+	+	-	-	-
3βHSD	ZD	-	+/-	+/-	+	+	+	+	+	+	+	+	++	++
	ZT				+	+	+	+	+	+	+	+	++	++
	ZF	-	-	-	-	-	-	-	-	-	-	-	-	-
17-OH	ZD		-	-	-	-	-	-	-	-	-	-	-	-
	ZT				+	+	+	+	+	+	+	+	+	+
	ZF		+	+	+	+	+	+	+	+	+	+	+	+
CYP11B2	ZD			-	-	-	+/-	+	+	+	+		+	++
	ZT				-	-	-			-	-		-	-
	ZF		-	-	-	-	-			-	-		-	-
SRB1	ZD			-	-	+	+/-		+/-	+/-	+/-	+	+	-
	ZT				-	+	+/-		+/-	+/-	+/-	+	+	+
	ZF	+	+	+	+	+	+		+	+	+	-	-	-
Shh	ZD	+	+	+	+	+	++			++	++	++	++	+
	ZT				+	+	++			++	++	++	++	
	ZF	+	+	+	+	+	+			+	+	+	+	

ZD: définitive zone; ZT: transitional zone; ZF: fœtal zone; (-) no staining (+/-) weak staining, (+) evident staining, (++) strong staining
Transitional zone appears at 20 Gestational week

- ❑ The present study constitutes the first **demonstration of the presence of mast cells in human fetal adrenal gland from the second trimester of pregnancy in the subcapsular zone of the cortex**.
- ❑ Double immunostaining did not allow us to found evidence for relationship with the 3βHSD or 17OHP enzymes and/or stem cells kinetic expression. However **CYP11B2 (or aldosynthase) expression is detected from the 24 weeks of gestation** that could suggest a role of mast cells in aldosterone synthesis. Moreover, proliferative markers decreased from the 22th week of gestation, concurrently to mast cells that could suggest a role in that process.
- ❑Therefore **mast cells could be as a new mechanism involved in adrenal development.** However, further studies specially in animal model need to be performed to better understand the role of mast cells in adrenal development.

Referencies

- Kemona P, Flück CE. Adrenal gland development and defects. *Best Pract Res Clin Endocrinol Metab.* 2008; 22(1):77-93.
- Duparc, C. *et al.* Regulation of aldosterone secretion by intraadrenal mast cells: potential role in the physiopathology of aldosterone-producing adenoma.(2011)
- Raica, M., Cimpean, A. M., Nico, B., Guidolin, D. & Ribatti, D. A comparative study of the spatial distribution of mast cells and microvessels in the fetal, adult human thymus and thymoma. *International Journal of Experimental Pathology* 91, 17–23 (2010)
- Nakamura Y, Maekawa T, Felizola SJ, et al, Adrenal CYP11B1/2 expression in primary aldosteronism: Immunohistochemical analysis using novel monoclonal antibodies; *Mol Cell Endocrinol. 2014,* 14;392(1-2):73-79.