

Testes in infants with Prader-Willi syndrome: hCG treatment, surgery and histology

N.E. Bakker^{1,2}, K.P. Wolffenbuttel³, L.H.J. Looijenga⁴, A.C.S. Hokken-Koelega^{1,2}



¹Dutch Growth Research Foundation, Rotterdam, ²Dept. of Pediatrics, Div. of Endocrinology, ³Dept. of Urology, ⁴Dept. of Pathology, Erasmus University Medical Center, Rotterdam, The Netherlands.



n.bakker@kindengroei.nl

Conclusion

HCG treatment results in an anatomical lower testis position in most infants with PWS, with 23% of testes attained a stable scrotal position. Seventy-six percent required an additional orchidopexy to ensure a stable scrotal position.

Background

Boys with Prader-Willi syndrome (PWS) often have undescended testes. Prospective studies on treatment of cryptorchidism in boys with PWS are lacking.

Aim

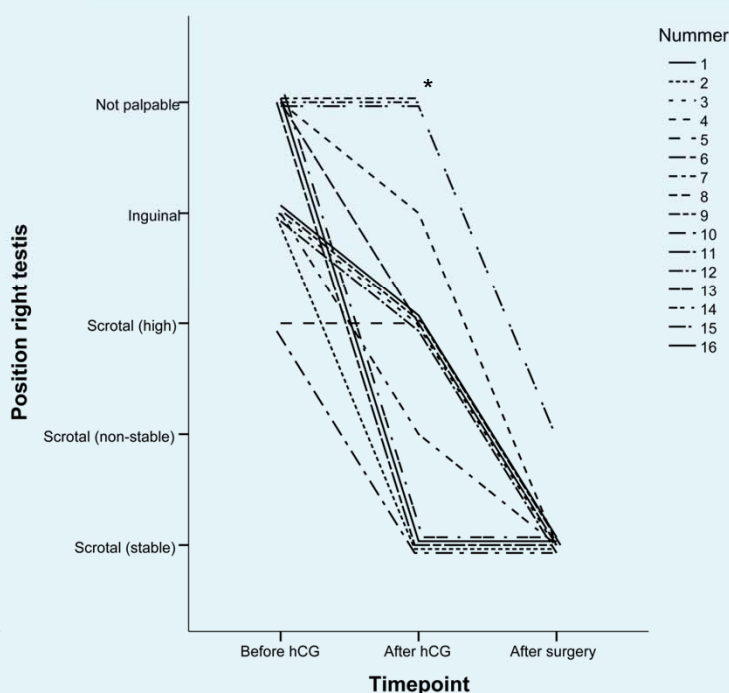
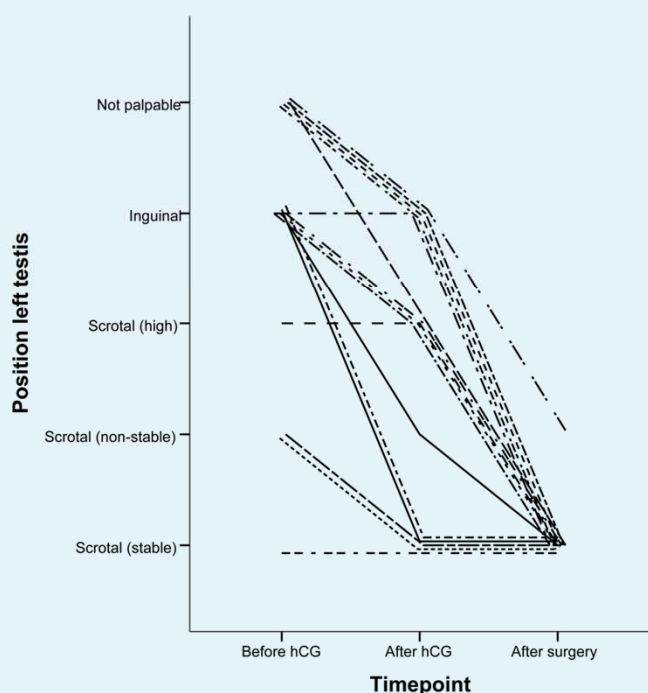
To evaluate the effects of human Chorionic Gonadotropin (hCG) treatment on testis position. In those who underwent orchidopexy, biopsy was taken and testis histology studied.

Patients and Methods

Sixteen male PWS infants with cryptorchidism, median (interquartile range) age 1.6 (1.2-1.8) years, underwent an hCG stimulation test. After a positive test, hCG treatment was initiated (250-500 IU depending on age, intra-muscular, 6 weeks, twice a week).

Position of the testes before and after hCG treatment and after surgery.

*One vanished testis and one atrophic abdominal testis.



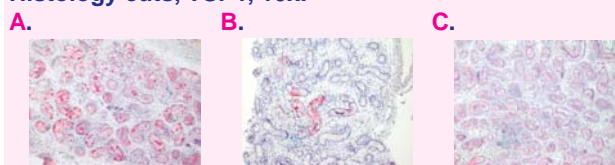Results

Of 29 testes that could respond to hCG, 23% reached a stable scrotal position, 62% a lower position and 14% didn't change position. Thus 22 testes required an additional orchidopexy.

Of the 17 obtained biopsies in 12 infants, 2 had germ cells in > 60% of seminiferous tubules, 3 in 30-60%, 7 in < 30%, 4 had Sertoli cell-only syndrome and 1 was a vanished testis.

In infants who underwent orchidopexy, a younger age, higher Inhibin B levels and a higher testosterone increase after hCG stimulation were associated with a higher number of germ-cell containing tubules.

Histology cuts, TSPY, 10x.



- A. Testis biopsy from a 15 months old boy with PWS. > 60% germ-cell containing tubules. Germ cells stain red.
- B. Testis biopsy from a 4 years old boy with PWS. < 30% germ-cell containing tubules.
- C. Testis biopsy from a 4 years old boy with PWS. Sertoli cell only.