



Università degli Studi di Messina
Dipartimento di Scienze Pediatriche Mediche e Chirurgiche

Acute adrenal failure in a term newborn with congenital cytomegalovirus infection

Lucia Marseglia¹, Tommaso Alterio¹, Lauretta Manti², Tommaso Aversa¹, Calafiore Maria Rosa¹,
Eloisa Gitto¹, Malgorzata Wasniewska¹

¹Department of Pediatric, Gynaecological, Microbiological and Biomedical Sciences, ²Department of Diagnostic Imaging, University of Messina,

Background

Bilateral adrenal hemorrhage is rare in the neonates and more rarely does it manifest itself as acute adrenal insufficiency (AI). Cytomegalovirus (CMV)-associated AI is a well-known in adults with acquired immunodeficiency syndrome. AI is not a common finding in children with congenital CMV infection.

We describe herein the case of a newborn infant presenting with adrenal hematomas (AH), AI and congenital CMV infection.

CASE REPORT

A 20 day-old female was referred to Neonatal intensive Care Unit with **lethargy, poor feeding, paleness and hypotension**. She presented **metabolic acidosis, hyponatremia, hyperkalemia and anaemia**. The abdominal US revealed **bilateral heterogeneous soft-tissue mass lesion in adrenal glands**, consistent with AH. Hormonal evaluation revealed: **altered circadian rhythm of cortisol, markedly elevated plasma adrenocorticotrophic hormone levels; reduced cortisoluria; normal 17-hydroxyprogesterone level**.

Replacement **therapy with gluco- and mineralocorticoids** was rapidly initiated, followed by resolution of clinical picture of AI. Serial ultrasound examination showed complete regression of AH within 5 weeks.

Cranial US revealed the picture of **“candlestick” lenticulostriate vasculopathy**, commonly found in infants with congenital CMV infection. **Anti-CMV IgM and IgG antibody index** values were elevated and quantitative CMV viral load in blood and urine showed significant viremia. **Maternal serology** was negative for anti-CMV IgM but positive for anti-CMV IgG. Serology was negative for human immunodeficiency virus (HIV).

Chorioretinitis was observed on ophthalmologic examination and **hearing loss** was diagnosed by auditory brainstem evoked response testing.

Ganciclovir therapy was started and continued for 6 weeks. The steroid dosage was tapered over the course of 3 months and gradually discontinued.

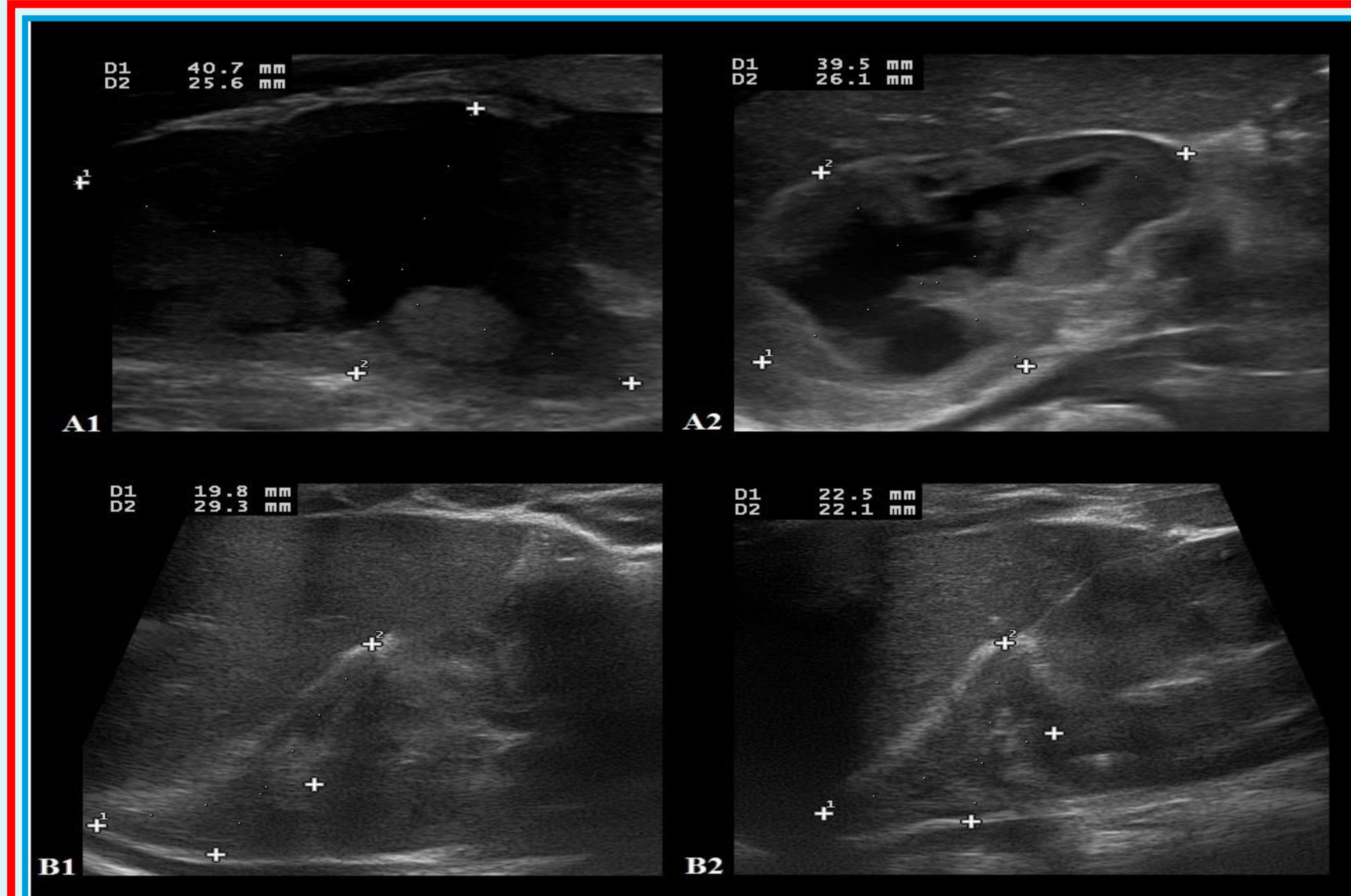


Fig 1

A1: Left adrenal gland measuring 40.7 x 26.5 mm and left AH measuring 29.0 x 20.9 mm
A2: Right adrenal gland measuring 39.5 x 26.1 mm and left AH measuring 26.1 x 16.7 mm
B1: Left adrenal gland measuring 19.8x29.3 mm after haemorrhage resolution
B2: Right adrenal gland measuring 22.5x22.1 mm after haemorrhage resolution

	Time 8:00 am	Time 16:00 pm	Time 24:00 pm	Normal range of basal values
Cortisol (µg/dl)	9.34	2.58	2.41	6.7-22.6
ACTH (pg/ml)	415.0	274.0	104.0	0.0-50.0

Table 1. Patient's altered circadian rhythm of cortisol and ACTH

Conclusion

- 1) This is, to our knowledge, **the first reported case of acute AI in a HIV negative newborn with bilateral AH and congenital CMV infection.**
- 2) On the basis of this case history, we suggest to **investigate adrenal function in CMV-infected newborns who present with unexplained electrolyte imbalances, weight loss, or hypotension.**

