



A CASE WITH ACRODYSOSTOSIS ASSOCIATED WITH HORMONE RESISTANCE

Selma Tunç¹, Korcan Demir¹, Filiz Hazan¹, Özgür Kırbıyık², Eren Soyaltın¹, Özlem Nalbantoğlu¹, Melek Yıldız¹, Hüseyin Anıl Korkmaz¹, Behzat Özkan¹

¹Pediatric Endocrinology, ²Division of Medical Genetics, Dr. Behçet Uz Children's Hospital, ³Division of Medical Genetics, Tepecik Training and Research Hospital, İzmir

Acrodysostosis

- Rare, <50 patients in literature
- Heterozygote mutations in *PRKAR1A* or *PDE4D*
- Characteristic features
 - Short tubular bones in hands and feet
 - Cone-shaped epiphyses
 - Broad nasal root
 - Various abnormalities of mandibula, skull and spine
 - Short stature
 - Mental retardation
 - Might be confused with pseudohypoparathyroidism due to hormone resistance (*PRKAR1A*).

12-year-old ♂

Complaint / History

- Shortness in hand and foot fingers since birth
- No additional complaint, no similar patient in the family

Past medical history

- Normal birth weighing 2800 g
- Poor school performance

Family history

- Parents were not relatives but from the same village

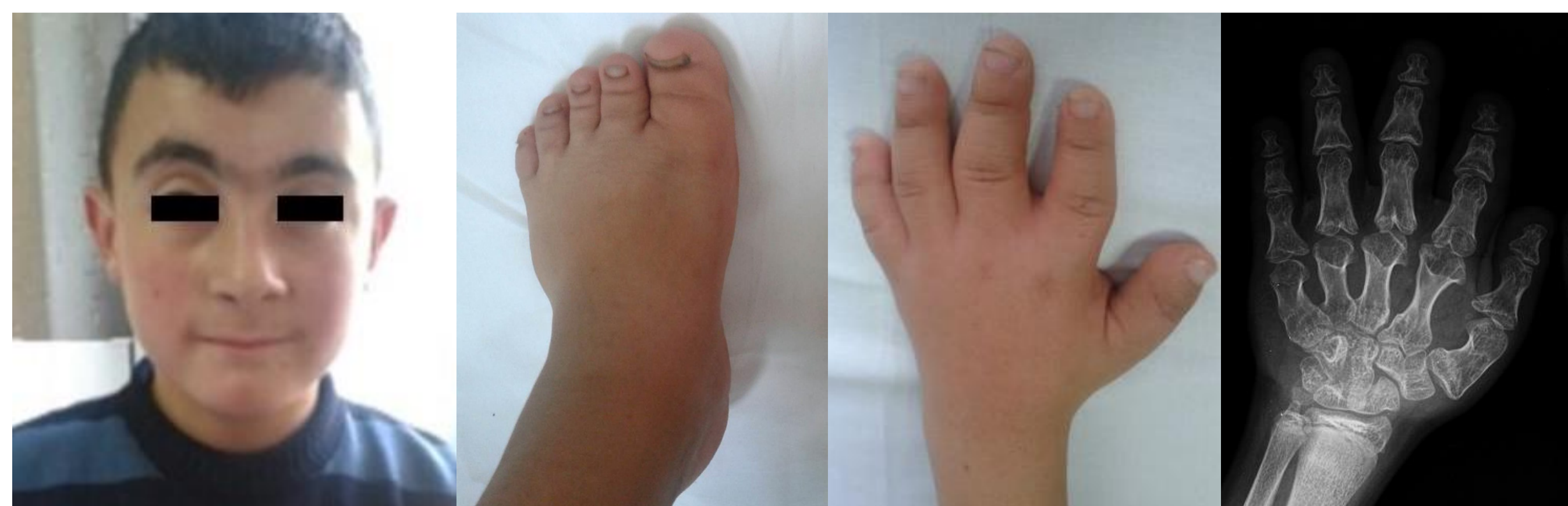Physical examination (see Figures)

- Weight 45 kg (SD score 0.50)
- Height 143.7 cm (SD score -0.83)
- Upper/lower segment 0.95, normal 1.05 – 0.82
- Synophrys, curved eyebrows, low-set ears and short hands and feet
- Testes 8 cc/ 10 cc
- Bilateral optic atrophy, more apparent on the left

Imaging/laboratory

- Cone-shaped epiphyses and short tubular bones in hands and feet (Figures)
- Bone age was compatible with chronological age

Figures

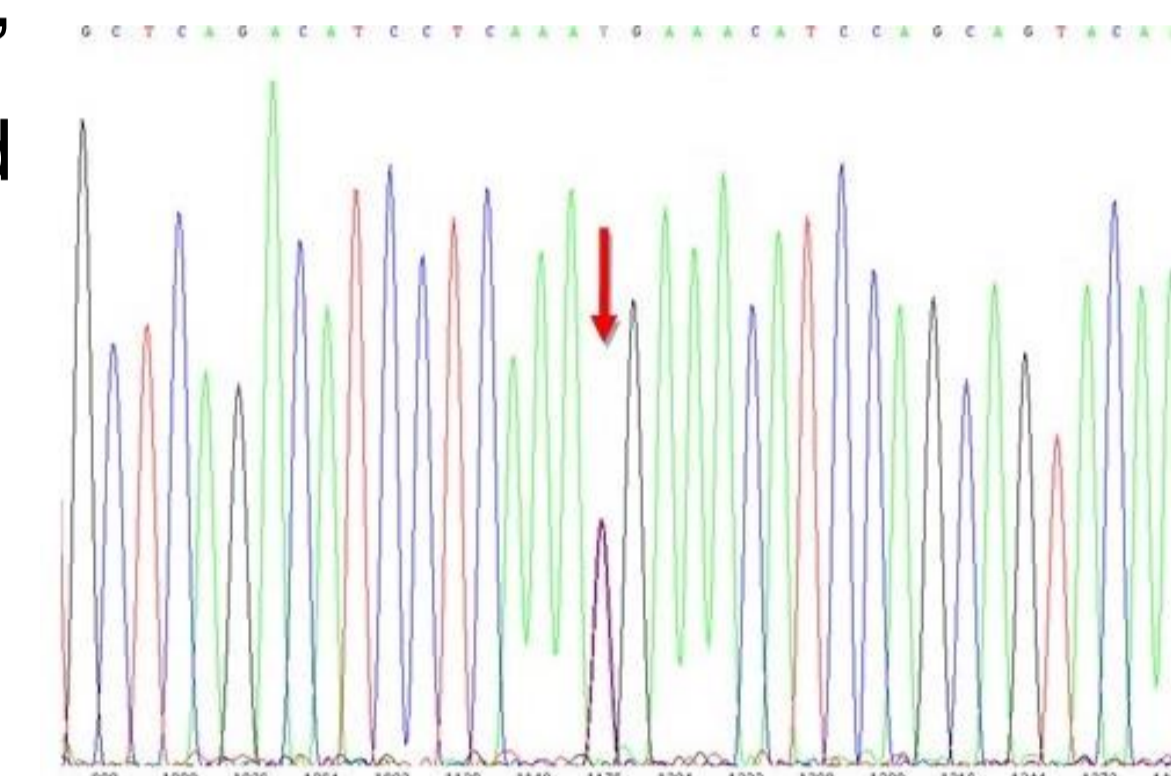


Laboratory Analysis

	Result	Normal interval
Calcium	9.5 mg/dl	8.8-10.8
Phosphorus	6 mg/dl	2.8-4.1
ALP	304 IU/L	0-500
PTH	441 pg/ml	19.8-74.9
25(OH) D	12.4 ng/ml	20-80
sT3	4.7 pg/ml	2.7-4.9
sT4	1.02 ng/dl	0.8-1.6
TSH	11.5 mIU/ml	0.9-4.4
Anti TG	negative	negative
Anti TPO	negative	negative
Thyroid USG	2.79 ml (SD score -1.52), gland echogenicity was slightly decreased, no nodules	

Genetic Analysis

- Division of Medical Genetics, Tepecik Training and Research Hospital
- Heterozygous c.1102C>T (p.R368X), 11th exon of *PRKAR1A*.



Discussion

- Most patients are determined as sporadic though they are inherited as acrodysostosis autosomal dominant.
- Hormone resistance can be detected together with acrodysostosis.
 - Dysfunction of cAMP regulator protein kinase A due to heterozygote *PRKAR1A* mutations
 - First reported in 2011
- Given elevated PTH and TSH levels and optic atrophy in our patient, *PRKAR1A* mutation was suspected and a known mutation was identified.
 - It is the first acrodysostosis case diagnosed with *PRKAR1A* mutation in our country

Conclusion

Acrodysostosis may accompany hormone resistance and should be kept in mind in the differential diagnosis of pseudohypoparathyroidism.

References

1. Linglart A et al. J Clin Endocrinol Metab 2012;97:2326-2328.
2. Kirnap M et al. Hormones 2013; 2(2): 309-311.
3. Atabek ME et al. J Pediatr Endocrinol Metab 2007;20(6):739-41.

