

NOVEL HETEROZYGOUS ACAN MUTATIONS IN SHORT STATURE: EXPANDING THE CLINICAL SPECTRUM

Lucia Sentchordi (1,2), Jimena Barraza (2,3), Carlos Iván Rivera (2), M. Victoria Marcos (4), M. Consuelo Sanchez (4), Elena Vallespín (2,3), Angela del Pozo (2,3), Karen E. Heath (2,3) 1) Hospital Universitario Infanta Leonor, Madrid, Spain; 2) Institute of Medical and Molecular Genetics (INGEMM & UMDE), IdiPAZ, Hospital Universitario la Paz, UAM, Madrid, Spain; 3) CIBERER, ISCIII, Madrid; 4) Consorci Sanitari de Terrassa, Terrassa, Spain
We have nothing to disclose

INTRODUCTION: Mutations in aggrecan (*ACAN*) have been identified in two dominant skeletal dysplasias, Spondyloepiphyseal dysplasia Kimberley type (SEDK) and Familial osteochondritis dissecans, and in a severe recessive dysplasia, Spondyloepimetaphyseal dysplasia aggrecan type (SEMD). Recently, **heterozygous *ACAN* mutations** have been reported in a few families with **idiopathic short stature, advanced bone maturation and premature growth cessation**. We report on two families with heterozygous mutations in *ACAN* with different phenotypes.

PATIENTS:

Case 1: 18-year old male (Fig 1) with short stature (height: 149.5 cm, -4.3 SD), lower limb shortening (sitting height 81.1 cm, arm span 159 cm) frontal bossing and relative macrocephaly (HC 58.5 cm, +1.2 SD). No hand anomalies. He had a poor pubertal growth spurt with no evidence of advanced bone age during childhood. His mother's height 132.7 cm (-5.3 SD), limb shortening, macrocephaly and brachydactyly (Fig 1). She reported growth cessation after menarche at 9 years old. The skeletal survey in both mother and son shows short femoral neck with no other anomalies (Fig 2). Four generations on the maternal side have short stature and a similar phenotype.

Case 2: 3 year old girl (Fig 1) with short stature (-3.14 SDS), relative macrocephaly, midfacial hypoplasia, flat nasal bridge, frontal bossing, acromicria and short feet. Skeletal survey revealed advanced bone maturation (BA 6 years, CA 3 years), metacarpal and metatarsal shortening and cone-shaped phalanges (Fig 2). No other anomalies were detected. Endocrine diseases have been ruled out. Her mother (patient 2b) heights 145.9 cm (-3 SDS), and has a similar facial aspect without acromicria. She stopped growing at 10 years old. Familial history includes short stature in four generations (heights -2.9/-5.8 SD).

METHODS: Both patients were analysed using a custom designed skeletal dysplasia NGS panel, SKELETALSEQ.V3 (315 genes). Candidate variants were confirmed by Sanger sequencing, as was family testing.

Fig 1: Pedigrees and clinical images of the two cases. Pedigrees of case 1 (A) and 2 (B); Growth curves for cases 1 and 2 (C). Images of case 1, aged 18 years (D) and case 2, aged 3 years (E,F,G), both showing shortened limbs. Side and frontal facial images of case 2 (F,G) and her mother (H,I) showing frontal bossing and midfacial hypoplasia. Case 1 has normal hands (J), whilst his mother has brachydactyly (K). Case 2 has brachydactyly (L) whilst her mother has normal hands (M).

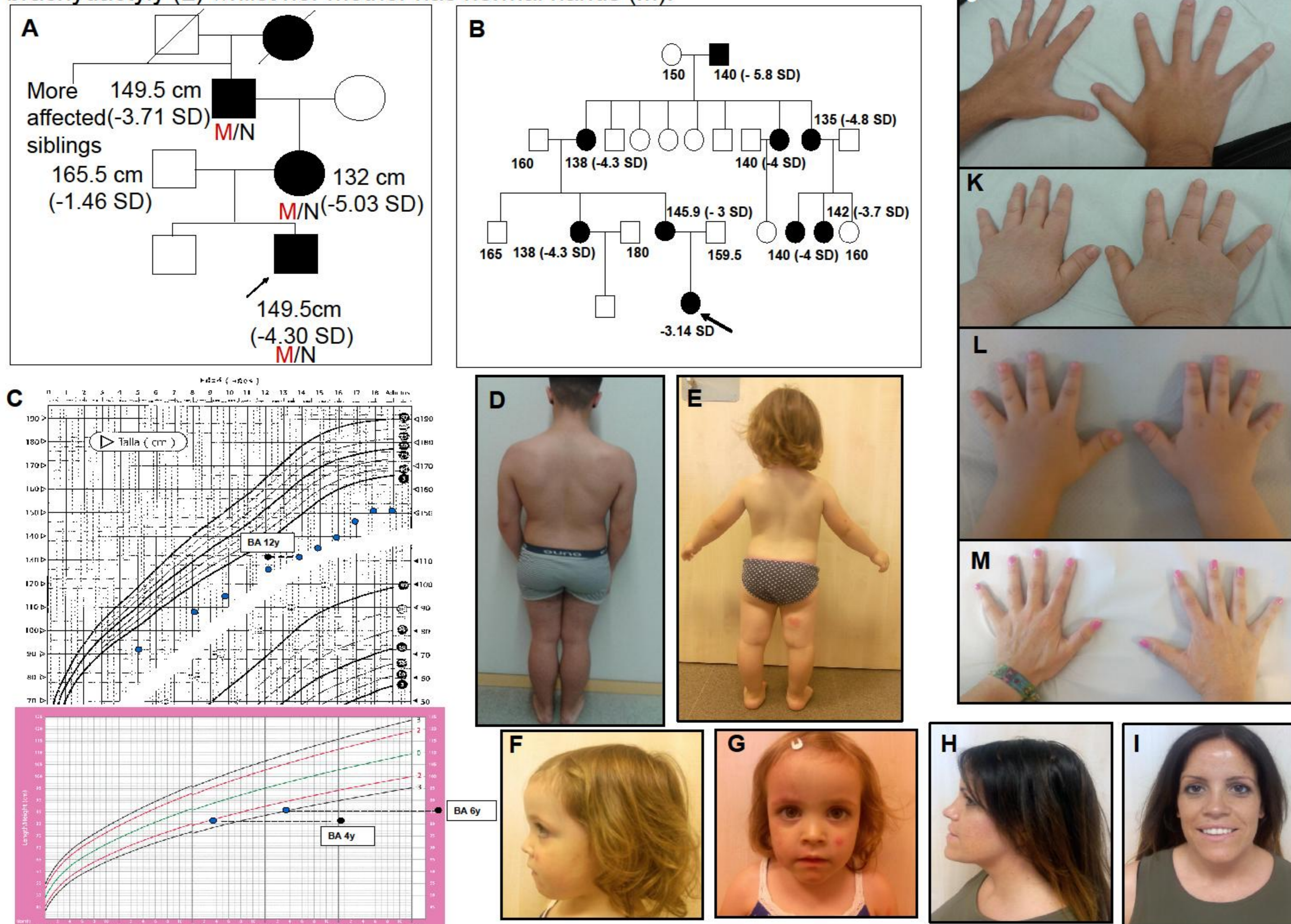
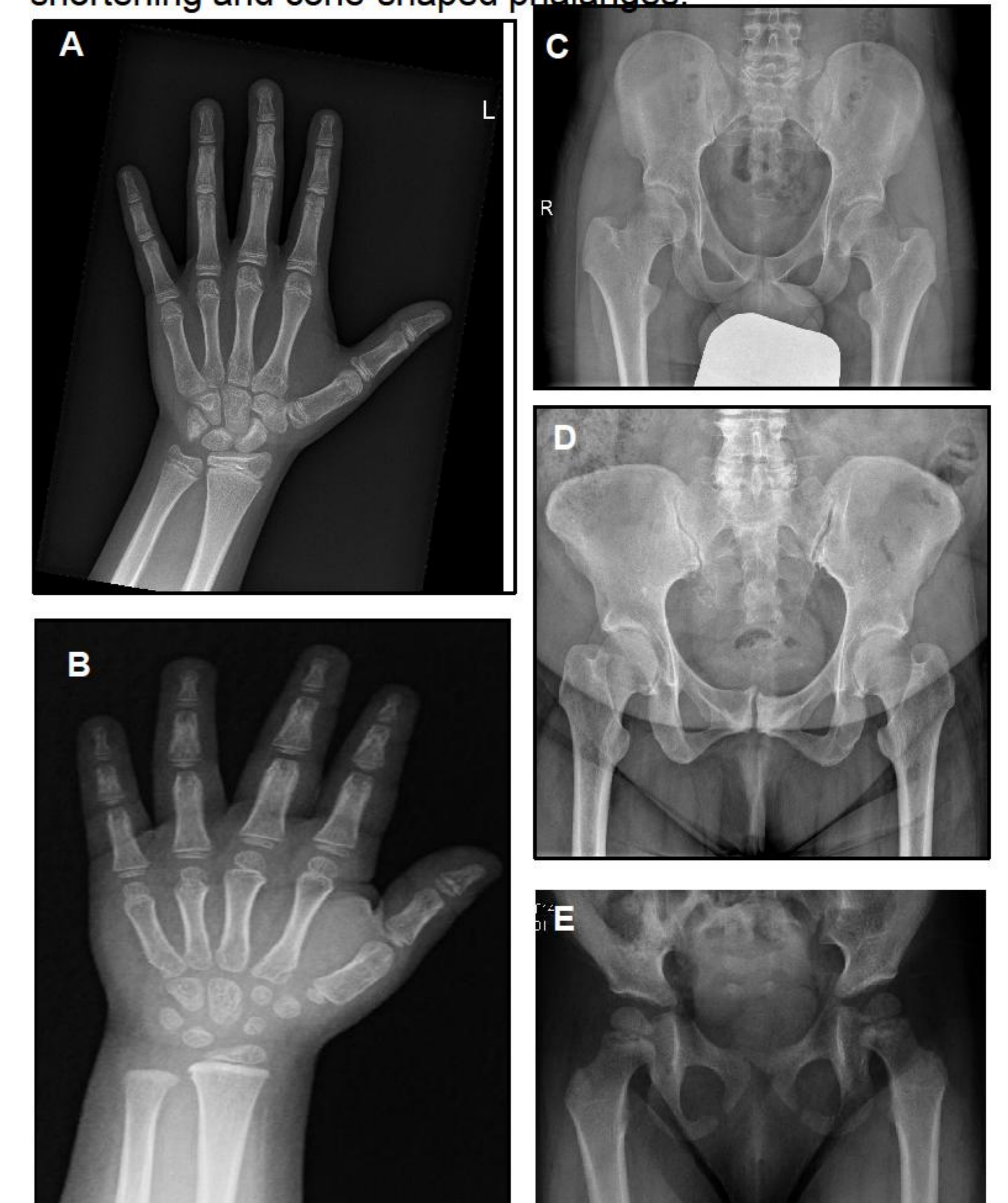


Fig 2: Hand and hip radiographs. Case 1 (A) at aged 14 years, (C) 18y and his mother (D). Case 2 (B, E) at aged 3 years. Case 1 has normal bone maturation and short femoral necks. Case 2 has advanced bone maturation (BA 6 years, CA 3 years), metacarpal and metatarsal shortening and cone-shaped phalanges.



RESULTS: Two novel heterozygous stop mutations in *ACAN* were identified in the two families: c.7276G>T in exon 16 (p.(Glu2426*)) in case 1 and c.61G>T in exon 1 (p.(Glu21*)) in case 2. Both mutations were also present in their similarly affected mothers and relatives.

CONCLUSIONS: Two novel *ACAN* mutations have been identified in patients with moderate short stature, mild dysmorphic features and mild skeletal abnormalities. Whilst the phenotype is similar in both cases and in recently reported cases, case 1 did not show signs of advanced bone age, nor acromicria, thus, broadening the spectrum of disorders caused by mutations in *ACAN*. Thus, *ACAN* should be considered a candidate gene in cases with short stature and accelerated skeletal maturation. Further cases are required to aid our knowledge into the molecular pathology of *ACAN* mutations and SD.

REFERENCES: 1- Quintos JB, Guo MH, Dauber A. Idiopathic short stature due to novel heterozygous mutation of the aggrecan gene J Pediatr Endocr Met 2015; aop. 2- Nilsson O, Guo MH, Dunbar N, Popovic J, Flynn D, Jacobsen C, Lui JC, Hirschhorn JN, Baron J, Dauber A. Short Stature, Accelerated Bone Maturation, and Early Growth Cessation Due to Heterozygous Aggrecan Mutations. J Clin Endocrinol Metab, August 2014, 99(8):E1510-E1518

