

A novel entity characterized by growth hormone deficiency (GHD) and central precocious puberty (CPP) in two siblings, in the absence of central nervous system (CNS) abnormality

Voutetakis A, Chiotis D, Dracopoulou-Vabouli M, Magiakou A, Chrousou G, Chrousos GP, Dacou-Voutetakis C

First Department of Pediatrics, Athens University, School of Medicine, Greece

The authors have no disclosure to declare

Introduction

The association of GHD with CPP has been reported in individuals with CNS abnormalities (congenital or acquired). In only two cases this complex was identified as an isolated, sporadic disorder. The aim of the study is to present the familial occurrence of combined GHD and CPP in the absence of CNS abnormality, suggesting a genetic disorder, inherited as an autosomal dominant trait.

Subjects and methods

Both siblings, a female and a male, were examined for short stature at the age of 11 and 8.2 years, respectively. No morphological abnormalities were present in either child. Reportedly, the girl presented signs of puberty at the age of 6 yrs and menarche at 7.8 years. The diagnosis of idiopathic CPP had been made but she received no therapy. At the time of presentation in our clinic (age 11 yrs) the girl had Tanner V stage of breast and pubic hair development. Her height was **122 cm** (height SDS – 8) with closed epiphyses, the Target Height being **148.5 ± 4.5 cm**. The endocrine work-up disclosed GHD with no response to GHRH but no other hormonal deficiencies. The karyotype was 46XX (Table 1).

The boy's height at presentation (age 8,2 yrs) was 107 cm (height SDS – 4.6). The testes size was 2 ml and pubic hair development was Tanner stage 1. The endocrine work-up disclosed GHD with no response to GHRH (Table 1). rhGH was initiated with good response (Figure 1). Upon follow-up testicular size of 4 ml was noted at age 10 yrs and the serum testosterone was 153 ng/dL (prepubertal value <40). The GnRH test results (Figure 2) were diagnostic of CPP. Puberty arrest was achieved with GnRHan given from age 10 10/12 yrs to 13 9/12 yrs. rhGH was continued up to the age of 17 yrs. He reached a final height of 170 cm, the Target height being 161.5 ± 4.5 cm (Figure 1).

In both siblings, pregnancy and delivery were normal with BW 4200 gr in the girl and 2700 in the boy. Progress in school was good in the boy but not the girl.

Brain and pituitary MRI disclosed no abnormalities. **Evoked optic potentials were normal.**

Growth hormone test in the parents: In the father (Height 160 cm), the peak growth hormone value during glucagon test was 2.2 ng/ml. Precocious puberty in the father could not be documented. In the mother (Height 150 cm), the peak growth hormone during glucagon test was 26 ng/ml (Table 1).

Table 1. Hormonal evaluation in the two siblings (female – male) and their parents.

Subjects	Peak GH (ng/ml)			Prolactin (ng/ml)	Brain MRI	Karyotype
	Glucagon	L DOPA	GHRH			
female	0.7	0.8	0.5	13	Normal	46XX
male	<0.5	<0.5	1.1	3.8, 6.4	Normal	*ND
mother	26				*ND	*ND
father	2.2				*ND	*ND

*ND: Not done

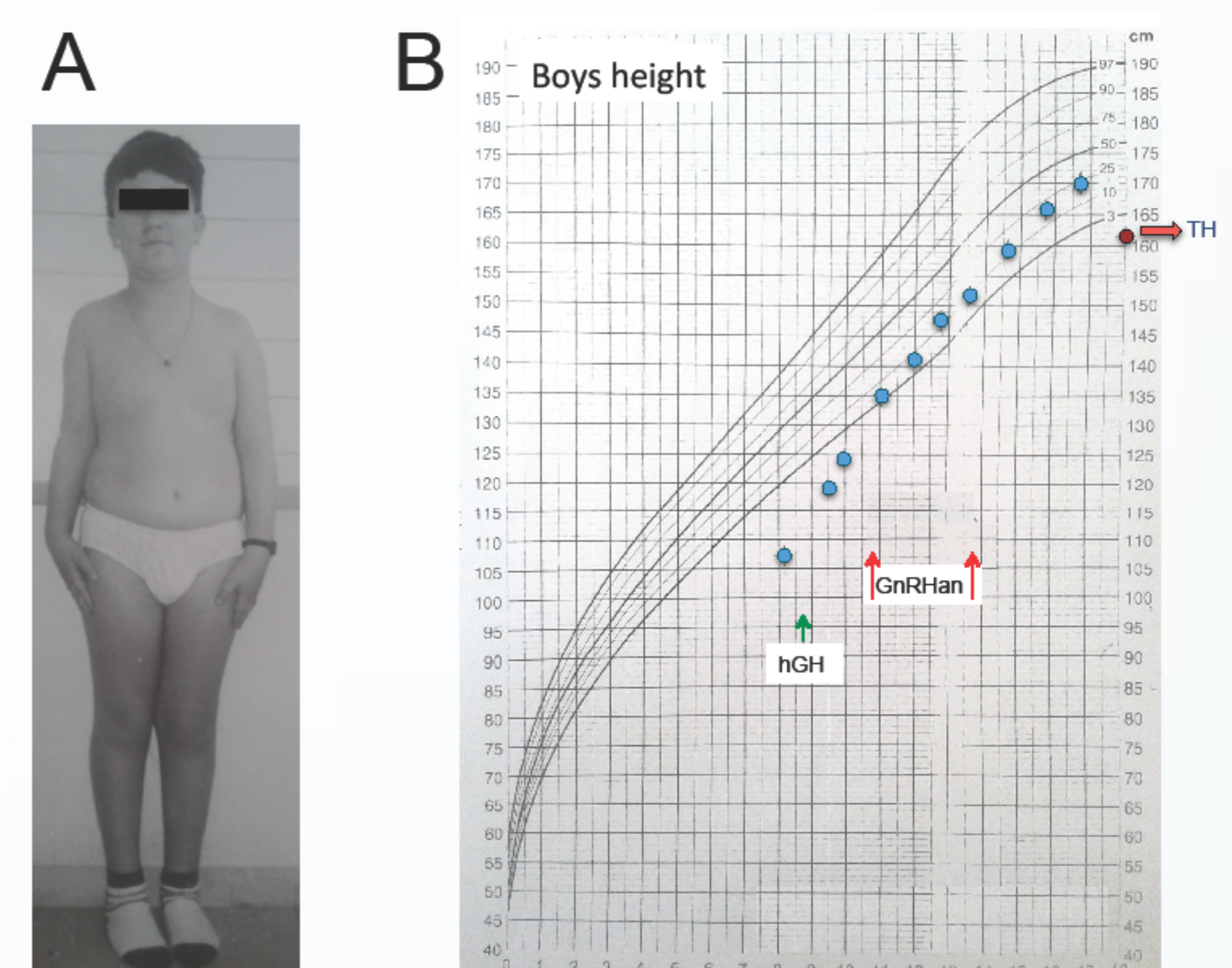


Figure 1. The boy at age 10yrs (A) and his Growth chart (B)




Figure 2. GnRH test before and during GnRHan therapy

Discussion and Conclusions

The combined defect of GHD and CPP in two siblings and documented GHD in their father, most likely, represents a novel nosologic entity possibly inherited as an autosomal dominant trait. It could represent a contiguous gene syndrome as it occurs in rare cases of Prader Willi Syndrome (PWS) presenting GHD and CPP, contrasting the usual occurrence of hypogonadism in this syndrome.

Alternatively, this complex of anomalies could be attributed to a mutated transcription factor related to pituitary cells lineage and acting in a diverse manner; loss or gain of function.

The recognition of such natural prototypes can act as the key to understand growth and pubertal development. Moreover, such defects must be recognized promptly and treated appropriately to avoid extreme shortness as it occurred in one of our two patients ending with a final height of 122 cm.