



54th Annual Meeting 1-3 October
ESPE 2015 BARCELONA
 European Society for Paediatric Endocrinology



Mariella Valenzise 1, Concetta Sferlazzas 1, Federica Porcaro 1, Maria Francesca Messina 1, Malgorzata Wasniewska 1, Maurizio Cinquegrani 2, Filippo De Luca 1.

1 University of Messina, Department of Pediatrics, Messina, Italy

2 University of Messina, Department of Clinical and Experimental Medicine, Messina, Italy

Competing interests: The Authors declare that they have no competing interests.

BACKGROUND

Hypothyroidism may be also a rare cause of acquired hypoceruloplasminemia. It has recently been underlined a role for thyroid hormone in the normal development regulation of ceruloplasmin (cp).

CASE PRESENTATION

A 3-year-old Caucasian girl was admitted to our clinic for recurrent pericarditis, fatigue and muscle weakness. Her family history was remarkable for Hashimoto's thyroiditis and Graves disease. Her recent personal history was significant for weight gain, swelling of the face and chronic constipation. On physical examination she had pale and round face with a normal thyroid size. Cardiovascular and abdominal examination were normal. Echocardiogram showed minimal dissection of pericardium. On laboratory evaluations an increase of transaminases about twice upper limit of normal was highlighted with low levels of cp equal to 12 mg/dl (normal range 20-60 mg/dl) and low serum copper 59 ug/dl (normal range 70 – 140 ug/dl). In order to exclude a Wilson disease, patient underwent to ophthalmologic evaluation and abdominal ultrasound that resulted normal. Thyroid study showed high levels of thyroid stimulating hormone (TSH) (338.000 mIU/ml), low levels of free thyroxine (FT4) (3.2 pmol/L) and positivity of anti-thyroid peroxidase antibody (anti-TPO) (2373.00 UI/ml). Ultrasonography showed a mild enlargement of gland volume and a three grade ultrasound pattern according Sostre classification. Levo-thyroxine replacement was started and blood tests performed four week after starting therapy pointed out a normalization of thyroid function and cp levels.

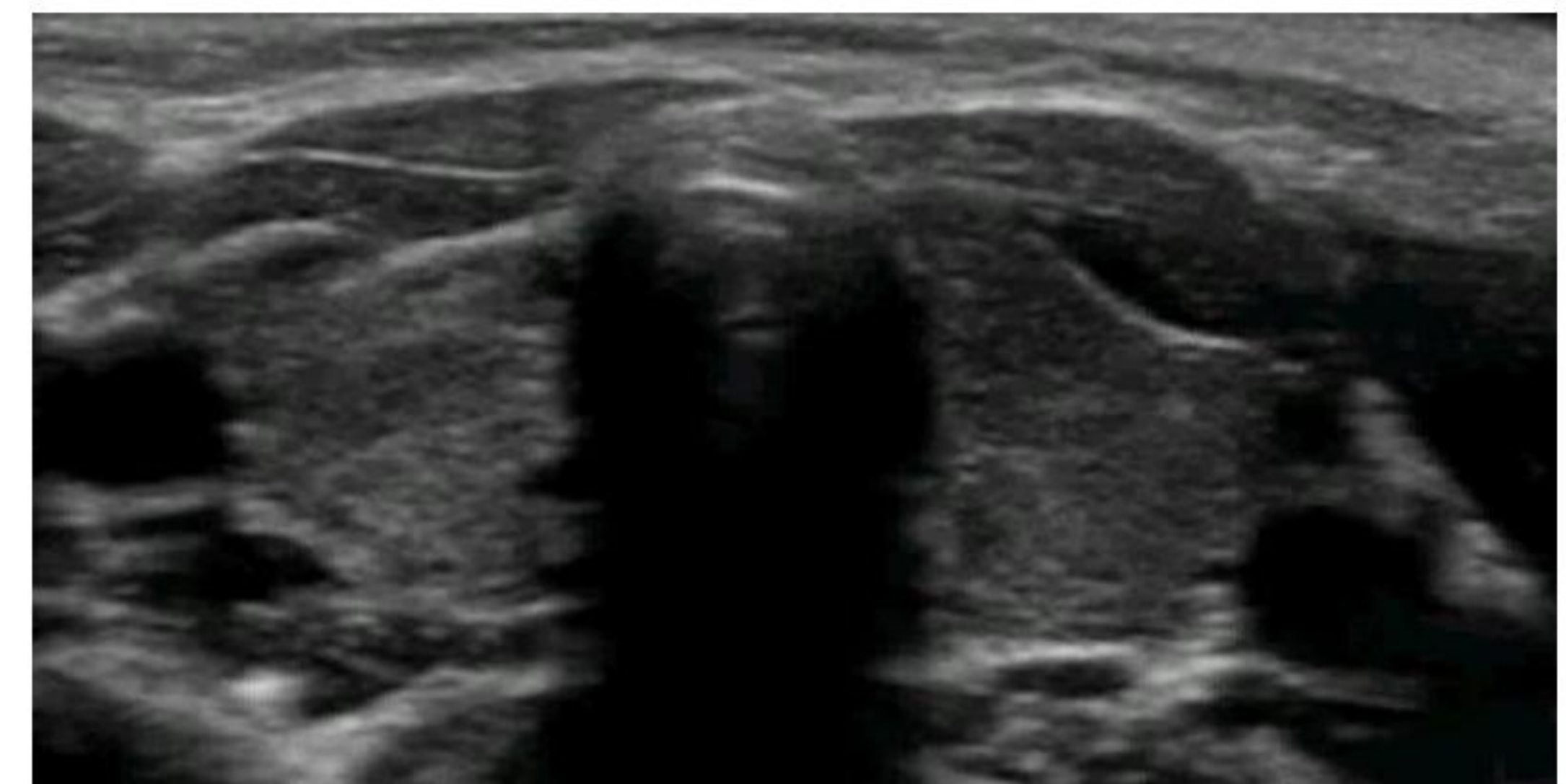


Figure 1. Thyroid ultrasound evaluation: three grade according Sostre classification.

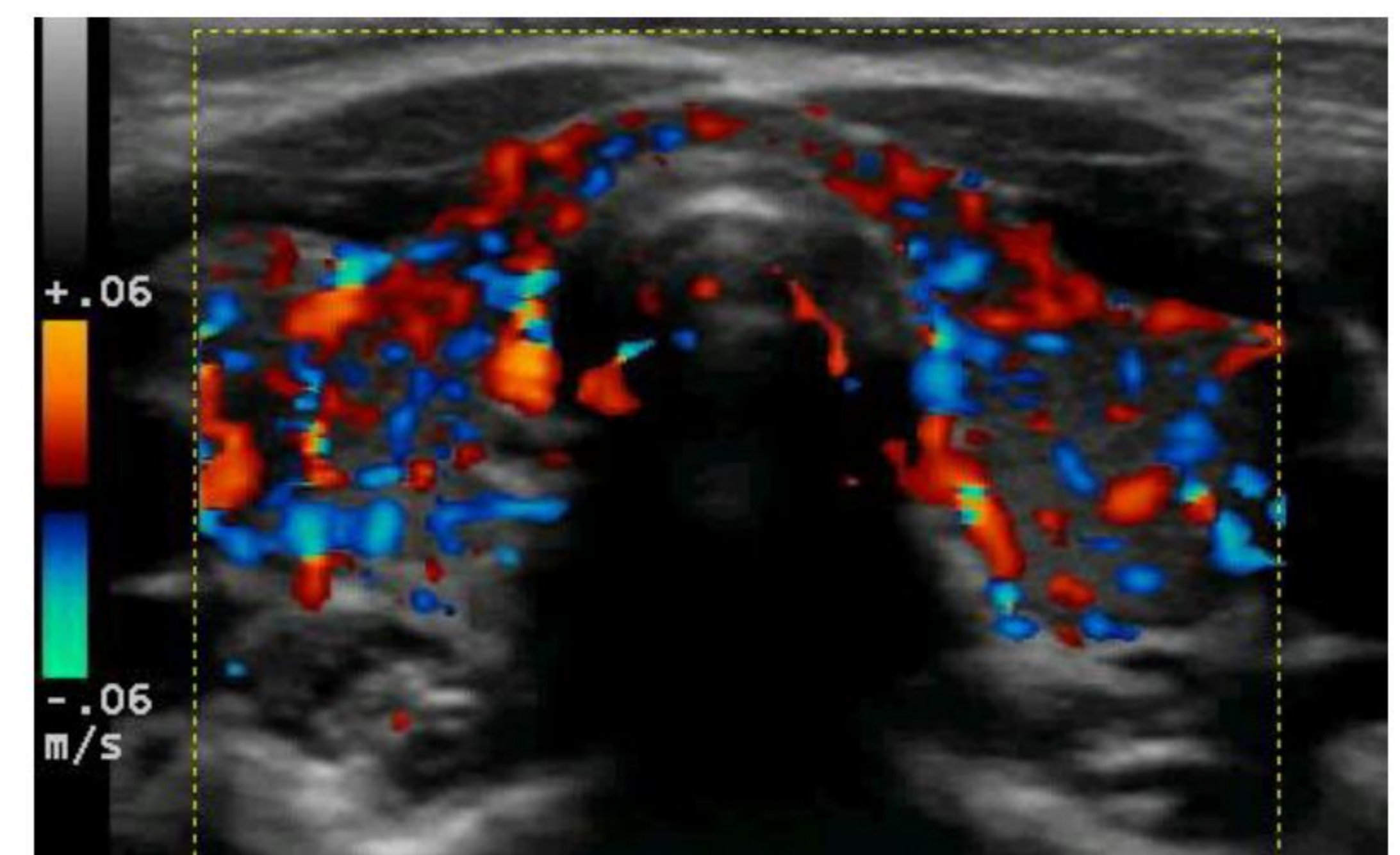


Figure 2. Color-doppler and Power-doppler images show gland hypervascularity

CONCLUSIONS

Thyroid hormones regulate positively serum copper levels inducing the hepatic expression of the two Cu-transport protein ATP7A and ATP7B as well as the major Cu-transport protein cp [1]. To the best of our knowledge the association of Hashimoto's Thyroiditis and hypoceruloplasminemia has not been reported to date. Our case confirms the role of thyroid hormones in the normal developmental regulation of cp and underlines that clinicians could suspect hypothyroidism in patients with hypoceruloplasminemia without Wilson's disease signs.

1] Ficht CA, Song Y, Levenson CW. Developmental regulation of hepatic ceruloplasmin mRNA and serum activity by exogenous thyroxine and dexamethasone. *Proc Soc Exp Biol Med* 1999; 221 (1): 27 – 31.

