

# Characterization of Ovarian Adrenal Rest Tumors in Children and Adolescent Females with Congenital Adrenal Hyperplasia due to 21-hydroxylase Deficiency

SU Zhe, LI Yan-hong, MA Hua-mei, DU Min-lian

**SU Zhe : Shenzhen Children's Hospital, Shenzhen, P.R. China, 518038**  
**Other authors: The First Affiliated Hospital of Sun Yat-Sen University, Guanazhou, P.R. China, 510080**

## Objectives:

To summarize the characterization of OART in children and adolescent females with congenital adrenal hyperplasia (CAH) due to 21-hydroxylase deficiency (21-OHD).

## Methods:

We have diagnosed 4 cases of CAH 21-OHD with OART in the recent 5 years and summarized the characterizations.

## Results:

The 4 cases of CAH 21-OHD included 3 salt wasters and 1 simple virilizers. OART were diagnosed at the age of 8.9 years, 15.8 years, 21.4 years and 9.3 years, respectively. There were histories of CAH poor control before the diagnosis of OART. The diagnosis could be confirmed before the operation in only 1 case. The diagnosis could not be made until the exploratory surgery in the other 3 cases. The follow-up periods of OART were 4.8 years, 4.7 years, 3.8 years and 2.7 years, respectively. Removal of OART resulted in symptoms relieved at least partly.

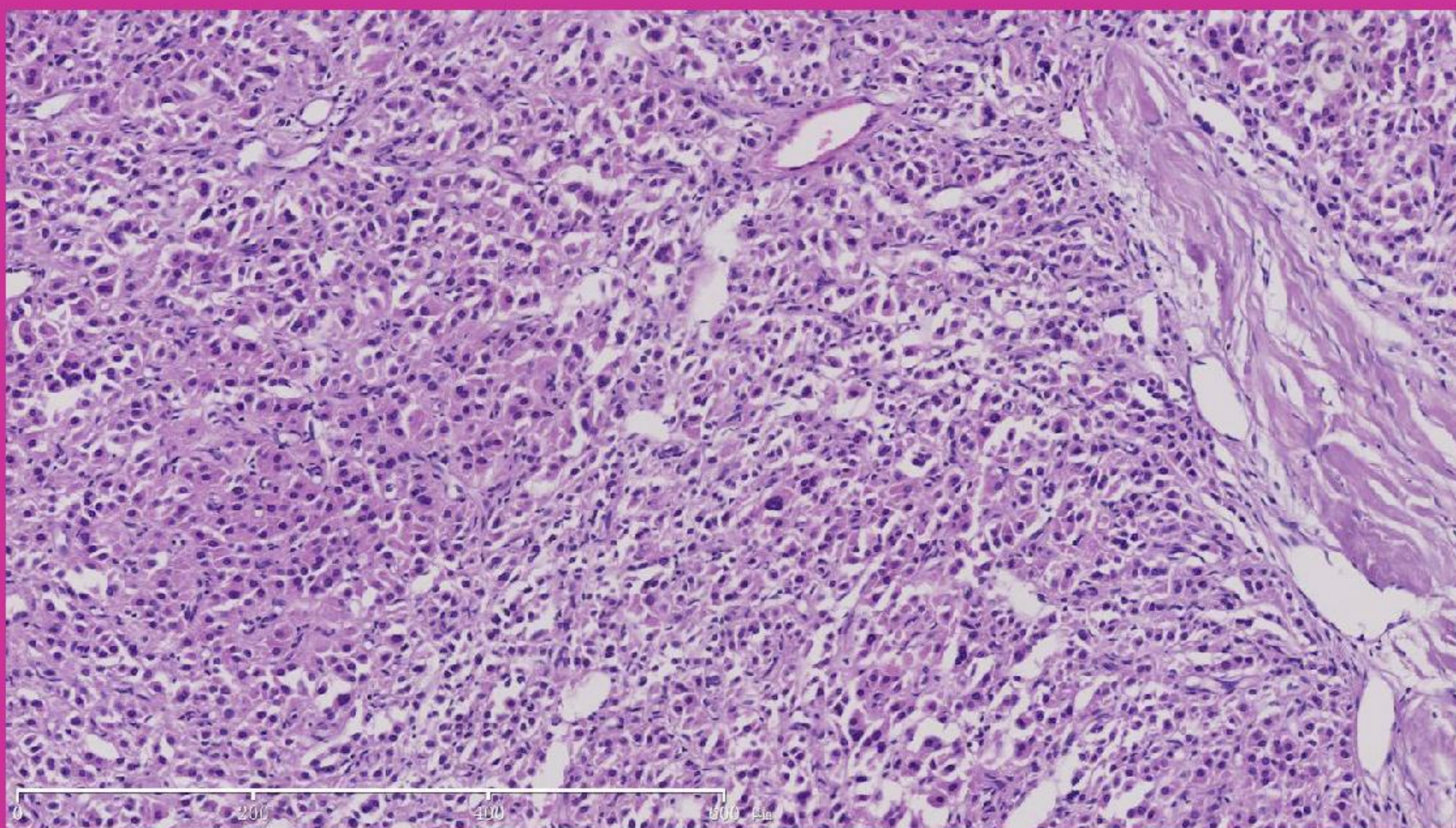


Fig 1: H&E staining of case 3 ( ×100 )

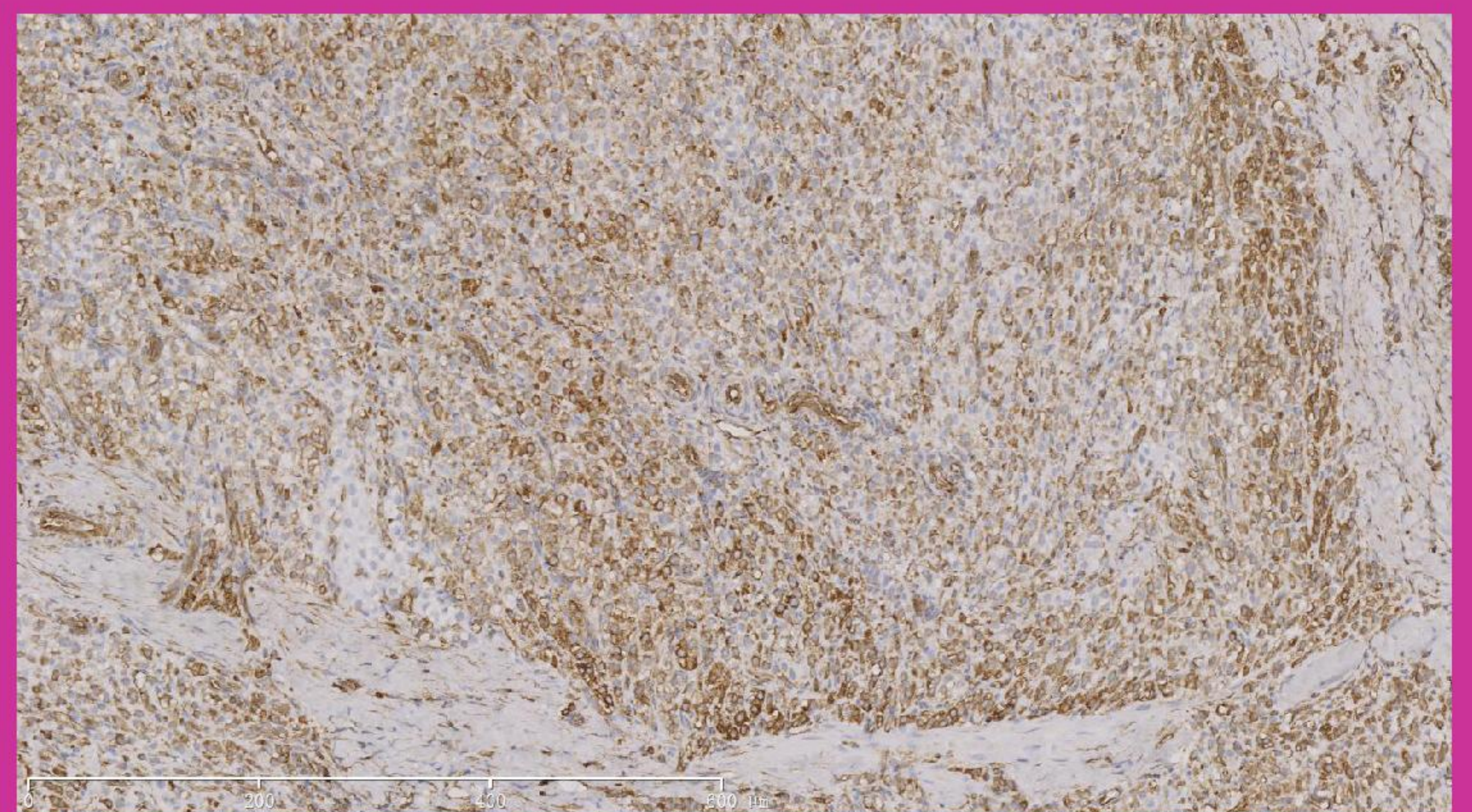


Fig 2: IHC of case 3: OART cell positive for CD56. ( ×40)

## Conclusions:

The diagnosis of OART is much more difficult than TART. Doctors should think about OART in CAH 21-OHD patients with poor control. In difficult cases of CAH with negative imaging finding may need further exploratory surgery. Removal of the OART resulted in symptoms relieved at least partly.

## References:

Thomas TT, Ruscher KR, Mandavilli S, et al. Ovarian steroid cell tumor, not otherwise specified, associated with congenital adrenal hyperplasia: rare tumors of an endocrine disease. J Pediatric Surgery, 2013, 48: e23-e27.

