

Conservative treatment of neonatal Cushing's syndrome in McCune Albright syndrome, a 2 year follow-up



Wilhelmina Children's Hospital

N.H.G. van Nieuwaal¹ MD, H.L. Claahsen - van der Grinten MD, PhD², R. Houwen MD PhD³, A.A. Verrijn Stuart¹ MD PhD

¹ Department of Pediatric Endocrinology, University Medical Center Utrecht, ² Department of Pediatric Endocrinology, Radboudumc Nijmegen, ³ Pediatric Gastroenterology University Medical Center Utrecht Netherlands

Introduction

McCune Albright syndrome (MAS) is defined by the classic triad of precocious puberty, fibrous dysplasia of bone and café au lait skin pigmentation. [1] However, the clinical spectrum is often more variable due to mosaic distribution of the postzygotic GNAS-mutation.

Hypercortisolism occurs in a minority (5%) of patients. It is most frequently caused by nodular adrenal hyperplasia and can be life-threatening. Decisions on whether clinical management should be conservative or should involve active intervention are challenging.

Patient description

We report a male neonate (birth weight 2560 grams; -2,5sd) with café au lait skin pigmentation as described in MAS and neonatal cholestatic liver disease of unknown origin.

At the age of 4 months he developed a Cushingoid appearance, failure to thrive (height 54.4cm -3.2 sd and weight for height 3800gr -1.0sd) and hypertension (Figure 1 and 2). Blood and saliva GNAS mutational analysis were both negative, but a mutation could be confirmed in tissue obtained during previous liver biopsy.

Diagnostic work-up at the age of 4 months showed elevated saliva cortisol levels (table 1), normal urinary cortisol excretion (120 – 240 nmol/l ref value 90-450 nmol/l). Cortisol levels were unsuppressed after a low and high dose dexamethason test suggesting an adrenal origin (table 2). MRI showed unilateral enlargement of the adrenal gland.

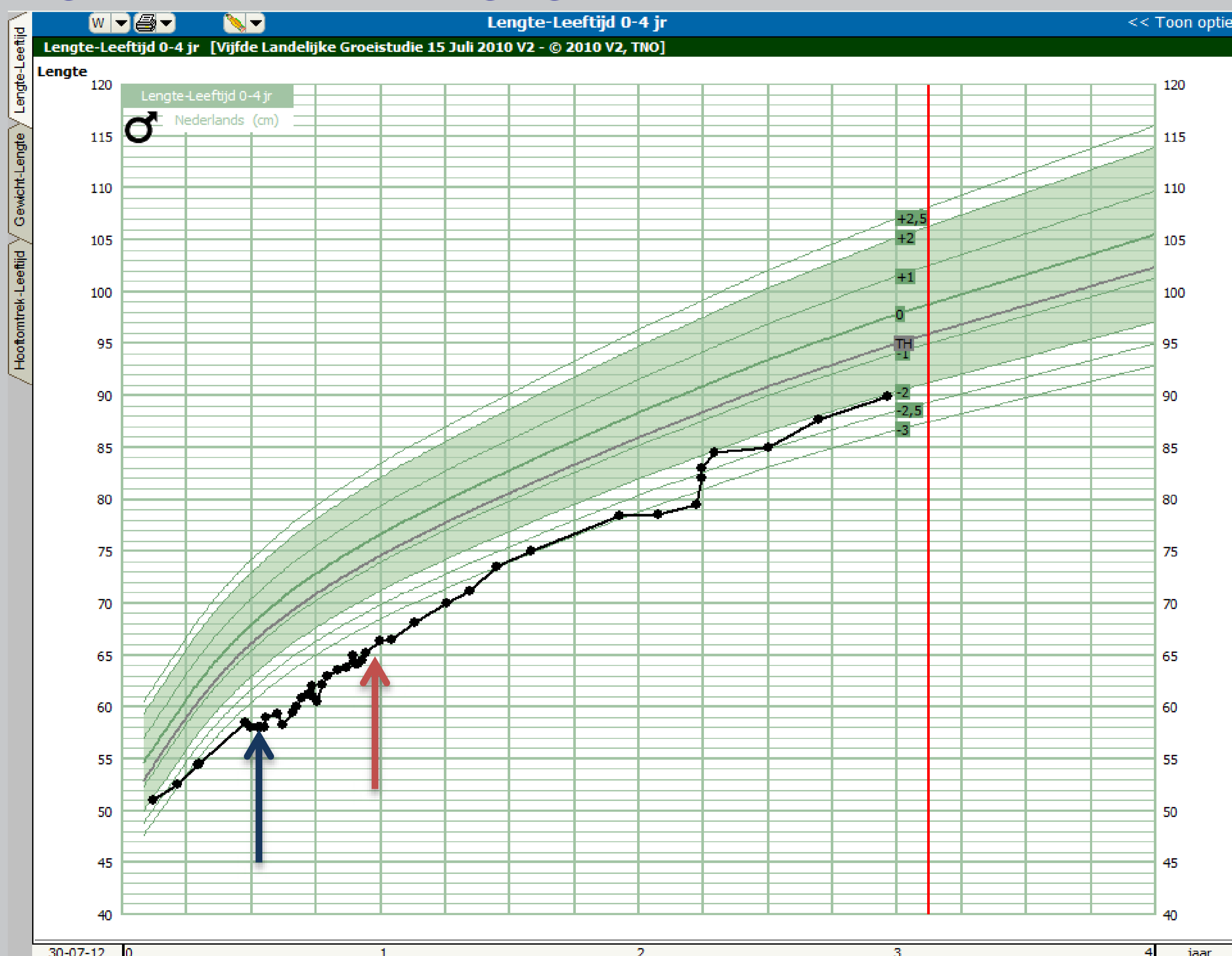
Metyrapone treatment was initiated at the age of 6 months with a maximum dose of 65 mg/kg/day. However, treatment response was difficult to assess and as reports raised concerns towards the effect on white matter [3], after 6 months treatment was stopped. Subsequently, growth and biochemistry were regularly assessed while the clinical condition allowed a conservative approach.

At the age of 15 months height growth spontaneously improved (from 3.5 SD to -2SD; target height -0.8sd). There were no signs of other hormonal involvement in MAS (normal thyroid function and IGF1 levels). A low dose ACTH test (1 ugr) by the age of 1,5 years showed an adequate adrenal reserve (0.59 umol/l) at 60 min. Saliva cortisol levels normalized (table 1). There were no signs of developmental delay and blood pressure normalized. At the age of 2,8 years signs of fibrous dysplasia, requiring orthopedic treatment was diagnosed. Furthermore elevated serum aminotransferases persisted without liver failure

Figure 1: Photographs at different ages*

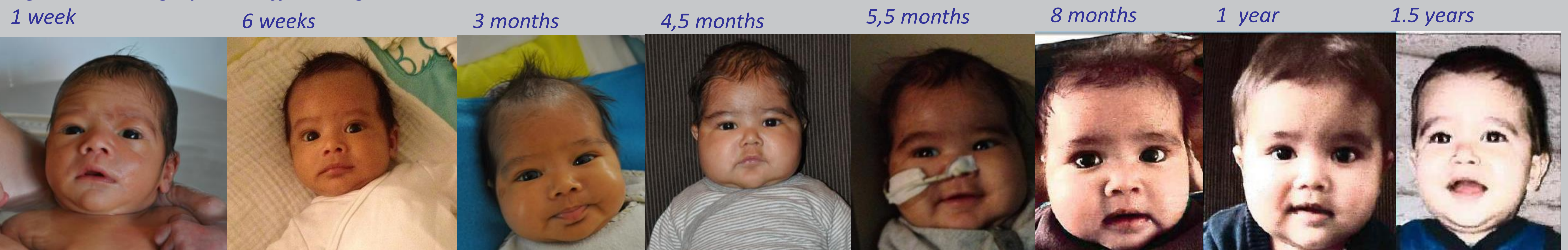

Figure 2: Growth chart: height growth



= Start Metyrapone

= Stop Metyrapone

Table 1: Saliva cortisol levels

	Ref values	Age of 4 months	Age of 2.5 years
Morning	9-29 nmol/l	26 nmol/l	9.5 nmol/l
Midday	4-12 nmol/l	28 nmol/l	11 nmol/l
Midnight	1-6 nmol/l	22 nmol/l	6.1 nmol/l

Table 2: Results after dexamethason suppression test before Metyrapone treatment

Age of 4 months	ACTH	Serum cortisol
Low dose (30 ugr/kg/day 48 hrs)	4 ng/l	0.60 umol/l
High dose (120 ugr/kg/day 48 hrs)	3 ng/l	0.59 umol/l

Discussion

In view of the present case, conservative treatment can be considered in neonatal Cushing syndrome in MAS. Brown et al reported a lower likelihood of spontaneous resolution in patients with liver disease [2]. Why spontaneous resolution occurs in some cases is a matter of further research. Probably this is the result of apoptosis of the mutated cells in the fetal zone of the adrenal cortex after the postnatal period [4]. Adrenal function must be monitored closely.

Conclusion

Conservative treatment of neonatal Cushing syndrome in MAS allows partial or complete recovery of Cushing syndrome, although close monitoring is required.

References

- Dumitrescu CE, Collins MT. McCune-Albright syndrome. *Orphanet J Rare Dis.* 2008 May 19;3:12.
- Brown RJ, Kelly MH, Collins MT. Cushing syndrome in the McCune-Albright syndrome. *J Clin Endocrinol Metab.* 2010 Apr;95(4):1508-15. 2009-2321.
- Ranke MB. *Diagnostics of Endocrine Function in children en adolescents 2003*
- Bocian-Sobkowska J, Woniak W, Malendowicz LK 1998 Postnatal involution of the human adrenal fetal zone: stereologic description and apoptosis. *Endocr Res* 24:969-973

(* informed consent to publish this photographs was obtained from his parents)

