

Discrepancy in bone age rating using manual Tanner-Whitehouse II and automated bone age determination in a child who was later diagnosed with metaphyseal chondrodysplasia

Niels H. Birkebæk Department of Pediatrics, Aarhus University Hospital, Denmark

Michel B. Hellfritsch Department of Radiology, Aarhus University Hospital, Denmark

Background

In the last 50 years bone age has been manually evaluated by a radiologist, using the method of Tanner-Whitehouse (TW) or Greulich and Pyle. Recently automated image analysis has been introduced for bone age determination. The automated method shows good agreement with manual evaluation; further, the precision of the automated method may be higher compared to the manual method

Objective and hypothesis

To report on the discrepancy of bone age determination using the manual TW2 method and the automated – boneXpert – TW3 method in a patient who later was diagnosed with metaphyseal chondrodysplasia.

Methods

A 4.8 year old girl with nanismus was admitted with a height of 92 cm ($-3\frac{1}{2}$ SD) and a weight of 15 kg (-1.5 SD). Her birth weight was 3.6 kg and birth length was 48 cm. Parents were ethnic Danish and 183 cm and 180 cm, respectively. The girl suffered no chronic diseases, had normal thyroid function, a normal growth provocative test and a normal female karyotype. She had a manually and automated bone age determination at the ages of 5.9 and 8.5 years. Further, she had a whole body X-ray examination and genetic examination.

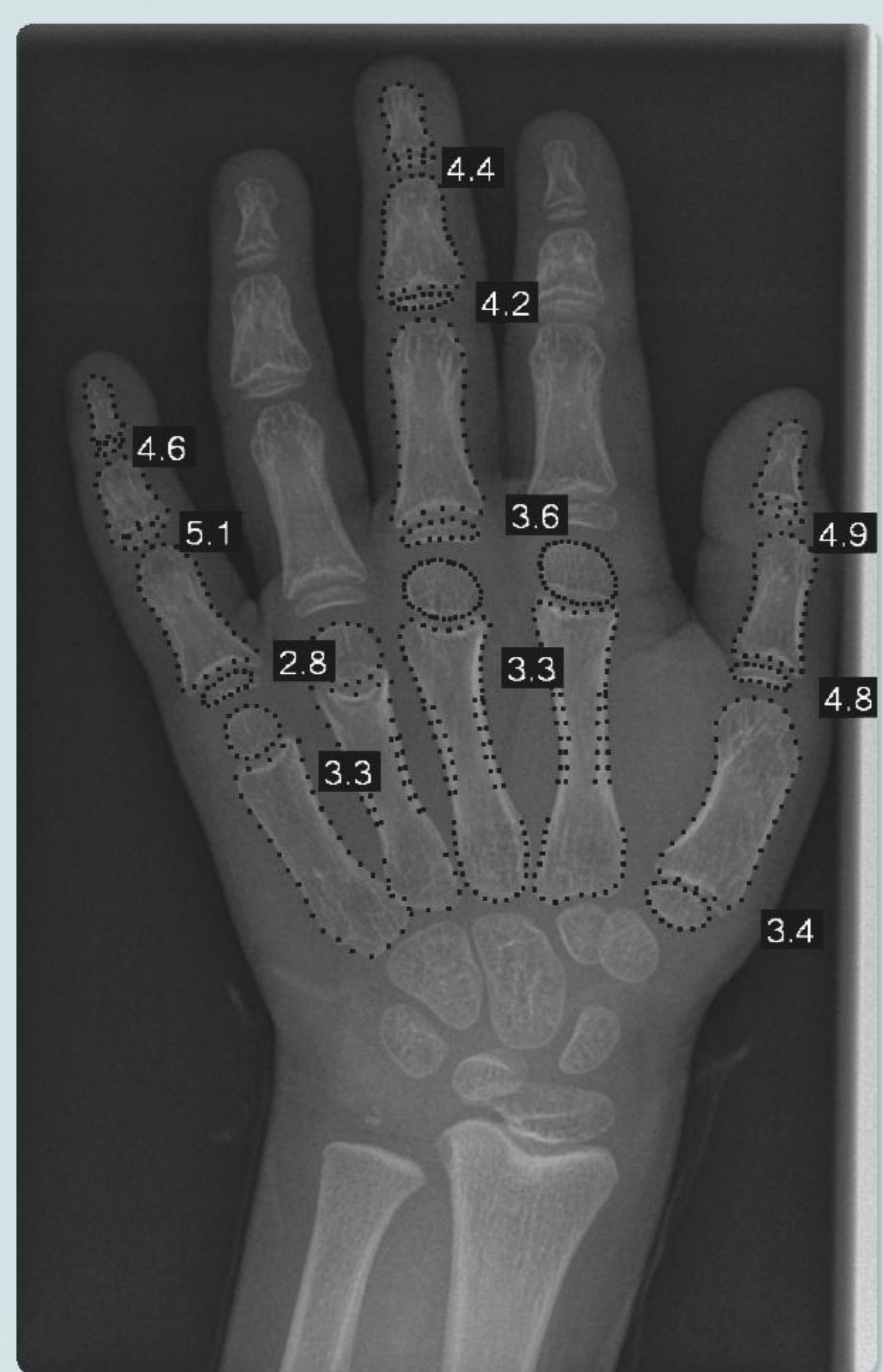
Results

At 5.9 years old the bone age was 6.7 years (manually) and 4.1 years (boneXpert) (figure 1), respectively, and the radiologist suspected bone disease (figure 2). At 8.5 years old the bone age was 9.1 years (manually) and 5.4 years (boneXpert), respectively. Whole body X-ray examination was compatible with metaphyseal chondrodysplasia - McKusick type (figure 3). Genetic examination confirmed the radiologic diagnosis with a homozygous pathogenic mutation 70A>G - in the RMRP gene.

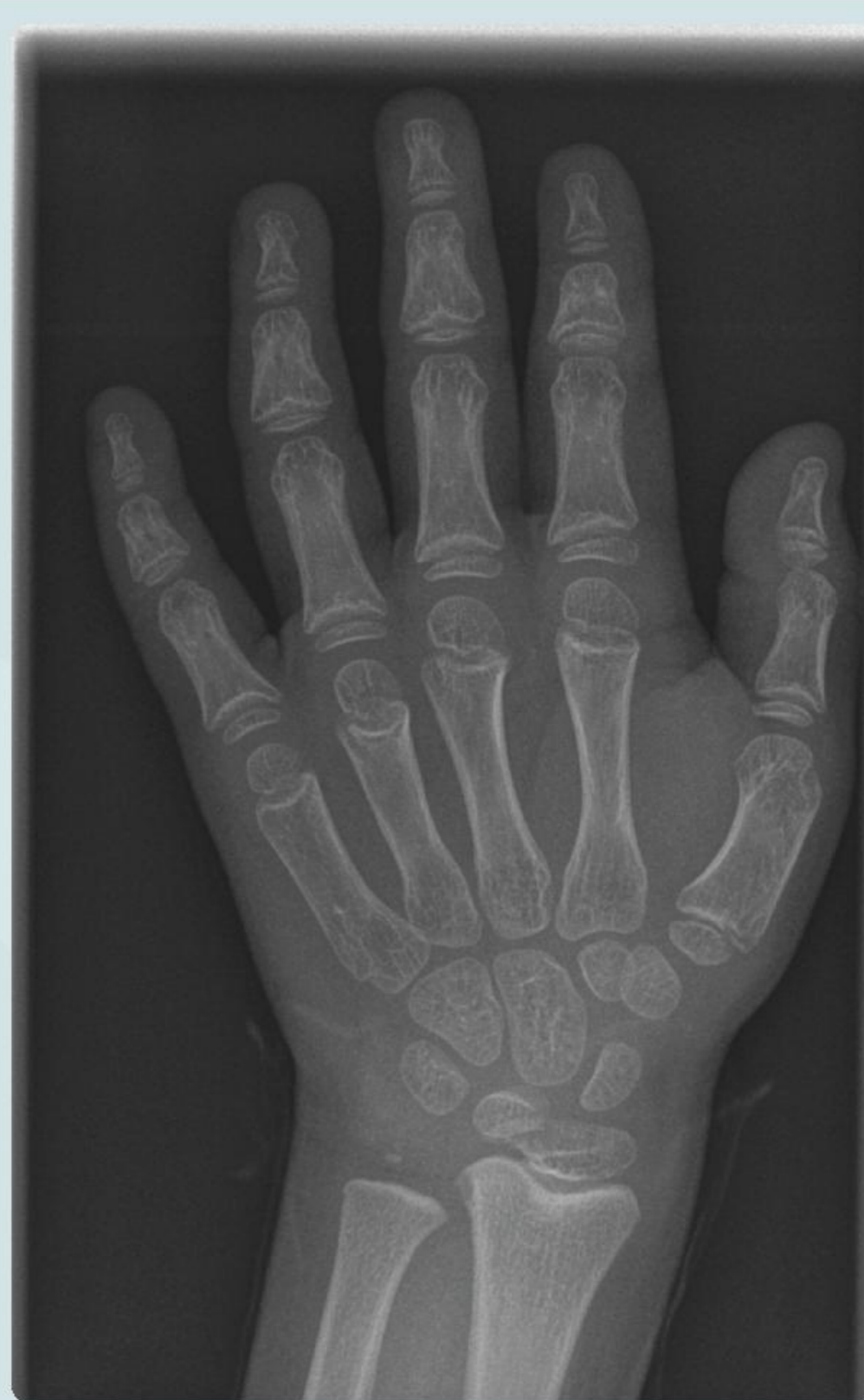Conclusion

Children with metaphyseal chondrodysplasia may show significant discrepancies in bone age when rated with the manual TW2 method and the automated – boneXpert – TW3 method. This may hamper adult height prediction. The manual method has the opportunity that the radiologist can evaluate bone structure and come up with proposals for further examinations.

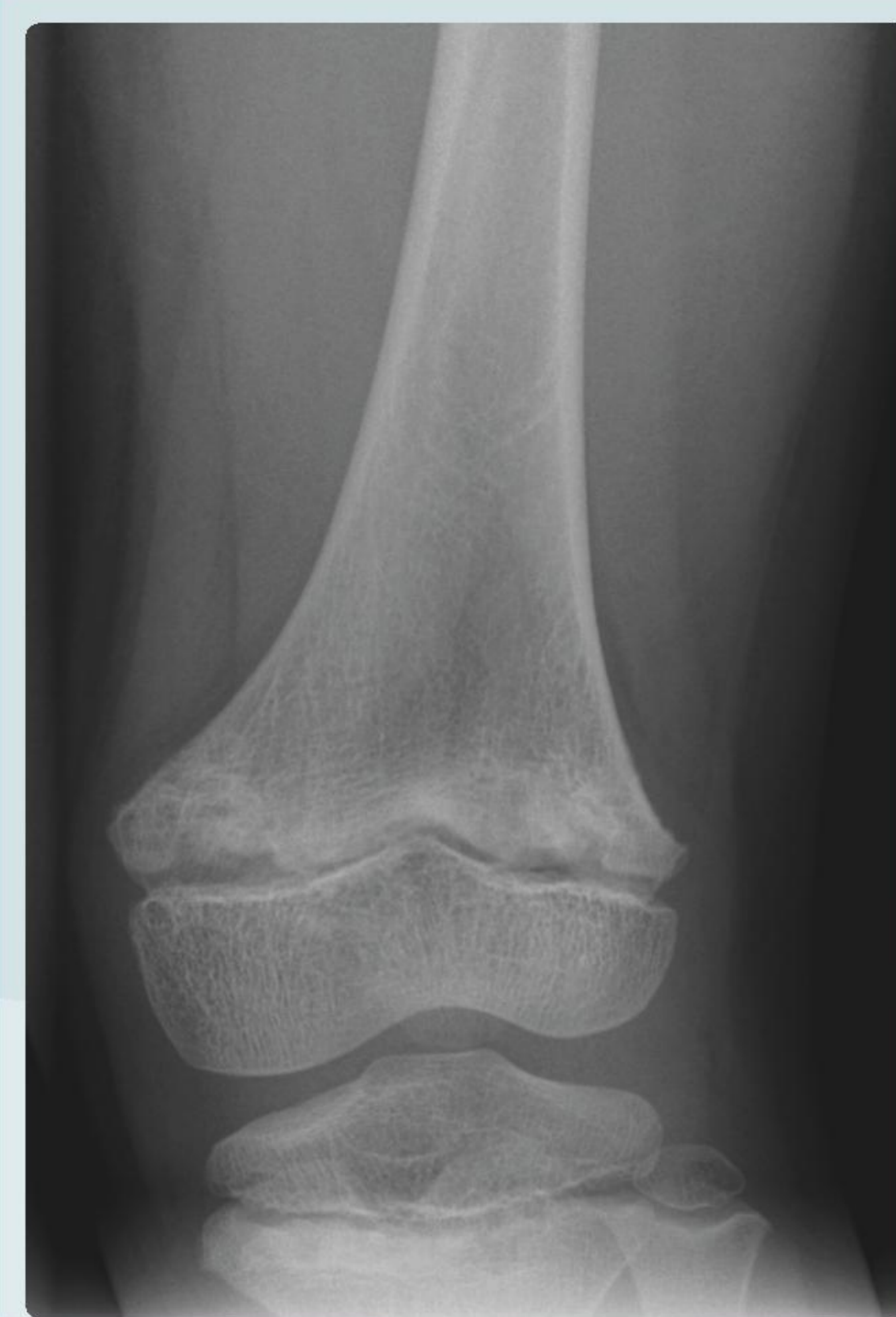The authors have nothing to disclose



Bone age 4.1 years (BoneXpert) at chronological age 5.9 years.



Bone age 6.7 years (manual evaluation) at chronological age 5.9 years. Coarse trabecular structure and short broad middle phalanges. Slightly sclerotic and irregular distal radial metaphysis.



Left distal femur and proximal tibia. Sclerotic and irregular metaphysis.

