

## Final Height (FH) in a patient with Fanconi Syndrome (FS) and Growth Hormone Deficiency (GHD) treated with Growth Hormone

Maria Cláudia Schmitt-Lobe (maria.l@terra.com.br), Laís Dadan Perini, Letícia Salm.  
 Pediatric Endocrinology Ambulatory, Regional University of Blumenau (FURB), Brazil

### BACKGROUND

The syndrome of Toni-Debré-Fanconi (FS) and growth hormone deficiency (GHD) is a rare association. The FS is a dysfunction in the proximal tubule that can be idiopathic or primary. This dysfunction leads to renal loss of bicarbonate, phosphate, glucose, potassium and amino acids. One of the clinical features is a delay in body growth<sup>1</sup>. The correction of acidosis can protect the loss of growth<sup>2</sup>. According to the prevalence of idiopathic growth hormone deficiency (GHD), it would be expected that 1 in 4000 patients and, patients with FS may have both conditions<sup>1</sup>.

### CASE REPORT

A 1.6-year old girl with FS, presented sweating, rickety rosary, tabes skull, chest keel, signs of rickets, muscle atrophy, enlargement of fists and knees. At this stage H-SDS: -4.49; blood tests showed metabolic acidosis, hypophosphatemia, aminoaciduria, glycosuria, phosphaturia. Was excluded from inborn errors of metabolism. The H-SDS of target height (TH) was -0.61. The patient received potassium, phosphate, and sodium bicarbonate replacement therapy. Clinical signs of rickets disappeared with this treatment.

At 7.5y, H-SDS: -2.89; HV-SDS: 1.54. At 9y, H-SDS: -3.72; presented growth velocity reduction, with appropriate therapeutic compliance, HV-SDS: -3.89. IgF1: 12ng/ml (22.1-383ng/ml); IgFBP-3: 1.3mcg/ml (2.6-5.5mcg/ml). GH stimulation test with clonidine: Basal: 0.7ng/ml; 30min: 0.7ng/ml; 60min: 6.3ng/ml; 90 min: 2.2ng/ml; 120min: 0.6ng/ml). Karyotype 46XX. Euthyroid. Tubular losses were appropriately replaced, no intestinal malabsorption. MRI of the pituitary gland and hypothalamus was normal. The GH replacement therapy was began at 10y (H-SDS: -3.85). She presented catch-up growth, HV-SDS: 4.9. GH treatment was maintained for 5.9 months. Menarche occurred at 15.2anos.

At 18y with 156cm, H-SDS: -1.03 the patient has no signs of rickets, makes use of citrate, phosphate, hydrochlorothiazide and persists treatment with nephrologist. BMD (Lumbar spine): Z-score: -1.0; PTH: 43.1pg/ml (11-65), Creatinine: 0.52mg/dl (0.4-1.0); Ca: 8.42mg/l (8.1-10.8); Pi 2.1mg/dl (1.3-6.1); Bic: 24mmo/l (23-27); 25-OHD: 49.7ng/ml.

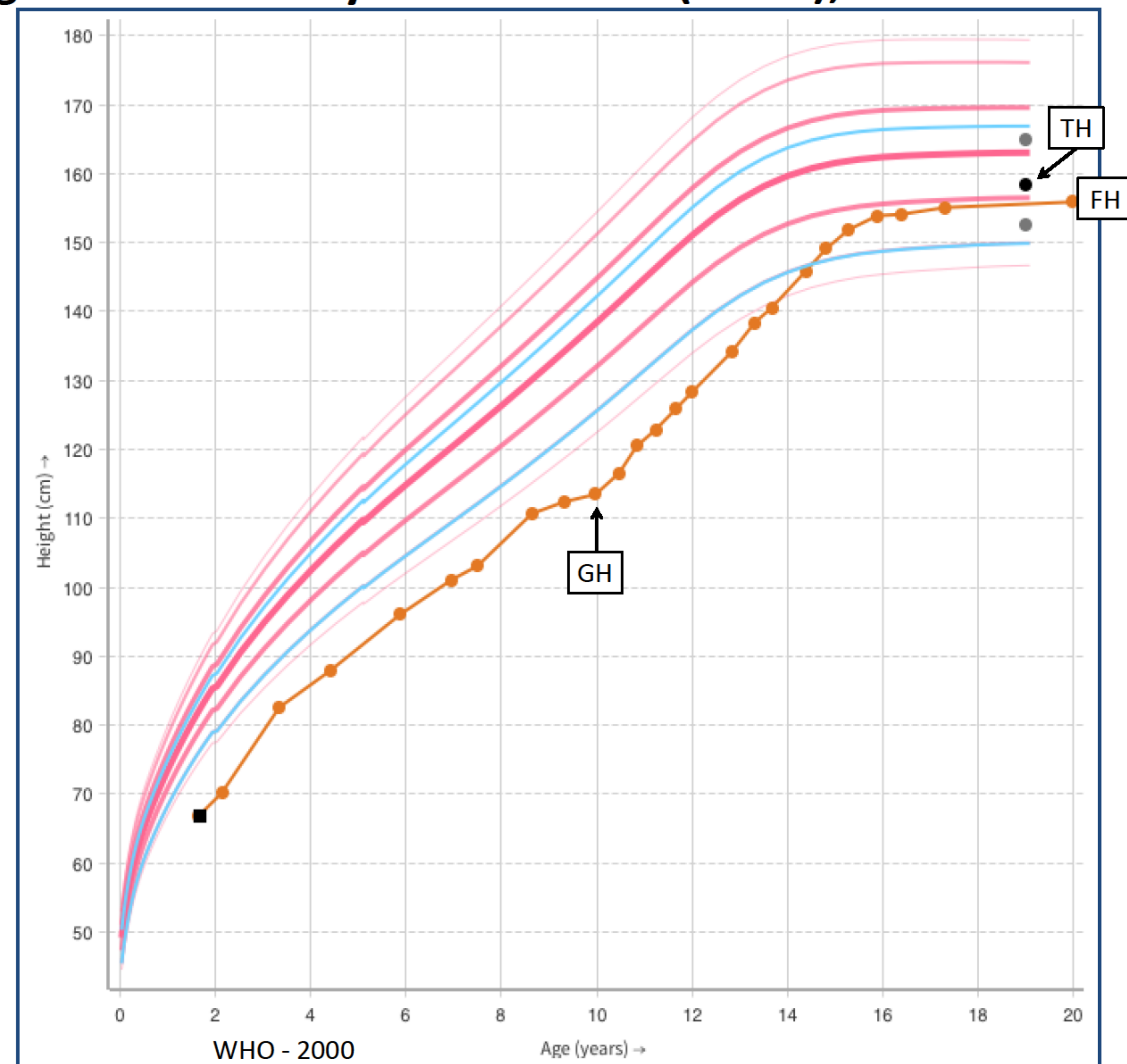
H-SDS at diagnosis: -4.49

H-SDS at 7.5: -2.89

H-SDS at 10y: -3.85 (GH)

H-SDS at FH: -1.03

H-SDS TH: -0.61



### DISCUSSION

Delay in body growth is expected in patients with FS<sup>3,4</sup>. Hypophosphatemia, disturbed vitamin D metabolism and metabolic acidosis are possible causes for growth retardation. Chronic hypokalemia and extracellular volume contraction seem to be cofactors, while glucosuria and the loss of amino acids are less important. When it is not reversed with the correction of acidosis, we should think in associated comorbidities, such as GHD. Plank et al. published the first report of FS and GHD association. According to them, before GHD was suspected, adequate control of the tubular electrolyte losses had been installed. The diagnosis of idiopathic GHD was suspected because of pathological growth velocity, low IGF-I concentrations and bone age retardation and could be confirmed using independent GH stimulation tests, demonstrating this coincidence<sup>1</sup>.

### CONCLUSION

With adequate control of the tubular electrolyte losses in FS expected an increase in growth rate. Even though uncommon, should be suspected growth hormone deficiency when there is a reduction in growth velocity. In this patient, treatment with GH, citrate and phosphate allowed to reach final height compatible with the target height.

### REFERENCES

1. Christian Plank C, Konrad M, Dörr HG, Dötsch J. Growth failure in a girl with Fanconi syndrome and growth hormone deficiency. *Nephrol Dial Transplant* 2004; 19(7):1910-2.
2. Gil-Peña H, Mejía N, Santos F. Renal Tubular Acidosis. *J Pediatr* 2014; 164(4):691-698.
3. Basu G, Sudhaka G, Mohapatra A. Renal tubular acidosis. *Clinical queries: nephrology* 2013; 166-178.
4. Besouw MTP, Dyck MV, Francis I, Hoyweghen EV, Levchenko EN. Detailed studies of growth hormone secretion in cystinosis patients. *Pediatr Nephrol* 2012; 27:2123 - 2127.