

COMPLETE ANDROGEN INSENSITIVITY SYNDROME ASSOCIATED WITH BILATERAL SERTOLI CELL ADENOMAS AND PARATESTICULAR LEIOMYOMA: CASE REPORT

Senay SAVAS ERDEVE¹, Zehra AYCAN¹, Melikşah KESKİN¹, Semra ÇETİNKAYA¹, Ayşe KARAMAN², Sema APAYDIN³, Emin ÇAKMAKÇI⁴

Dr. Sami Ulus Obstetrics and Gynecology, Children's Health and Disease Training and Research Hospital, Pediatric Endocrinology¹, Pediatric Surgery², Pathology³, Radiology⁴ Department, Ankara, Turkey

INTRODUCTION

Complete androgen insensitivity syndrome (CAIS) is a sexual development disorder due to mutations that cause function loss in androgen receptors in 46,XY individuals. The risk of malignancy development until the age of 25 years in CAIS is 5-10%. The case we present is a very rarely reported case in the literature with unilateral paratesticular leiomyoma developing concurrently with bilateral Sertoli cell adenomas.

CASE REPORT

A patient raised as a female aged 17 years presented to our clinic for primary amenorrhea. Her history involved surgery for left inguinal hernia at the age of 2. Her niece of the same age were diagnosed with CAIS and received gonadectomy 6 months ago. The patient had four more nieces with the same diagnosis. Phenotypically female, patient's physical examination demonstrated the following: weight: 164.7 cm (-1.53 SDS), body weight: 54.5 kg (-2 SDS), breast development: Tanner stage 5, pubic hair development: Tanner stage 2 and she had scarce axillary hair development. Gonad was palpable at the left inguinal region. Chromosome analysis revealed 46,XY, and positive *SRY* gene. Her laboratory analysis yielded the following: LH: 18.6 mIU/mL (1.7-11), FSH: 0.7 mIU/mL (1.4-11.7), total testosterone: 702 ng/dL (8-80), E2: 31.3 pg/mL (23-188), Anti-mullerian hormone: 8.2 ng/ml (0.8-14.2), dihydrotestosterone: 18.2 ng/dl (5-22), 1-4 delta androstenedione: 2.41 ng/mL (0.5-4.7), sex hormone binding globulin (SHBG): 59.7 nmol/L (18-145). Of the serum tumor markers, lactate dehydrogenase (LDH) was 146 IU/L (98-192), alpha-pheto protein (AFP) was 0.5 IU/ml (0.5-3.5) and B-HCG was <2 mIU/mL (0.5-5.3).

The result of the pelvic ultrasonography was reported as: 'Solid soft tissue 29x19x22 mm in size that could be from the testis parenchyma in the right adnex and adjacent cystic lesion 32x25x23 mm in size; solid soft tissue 17x9x11 mm in size that could be consistent with testis parenchyma in the left inguinal region and adjacent cystic lesion 38x20x18 mm in size. Mullerian structures could not be visualized.'

Figure 1. With T2-weighted MRI on the sagittal plain, right testis parenchyma appears to have smooth margins accompanied by paratesticular cyst appearance in the simple internal structure with lobule contours

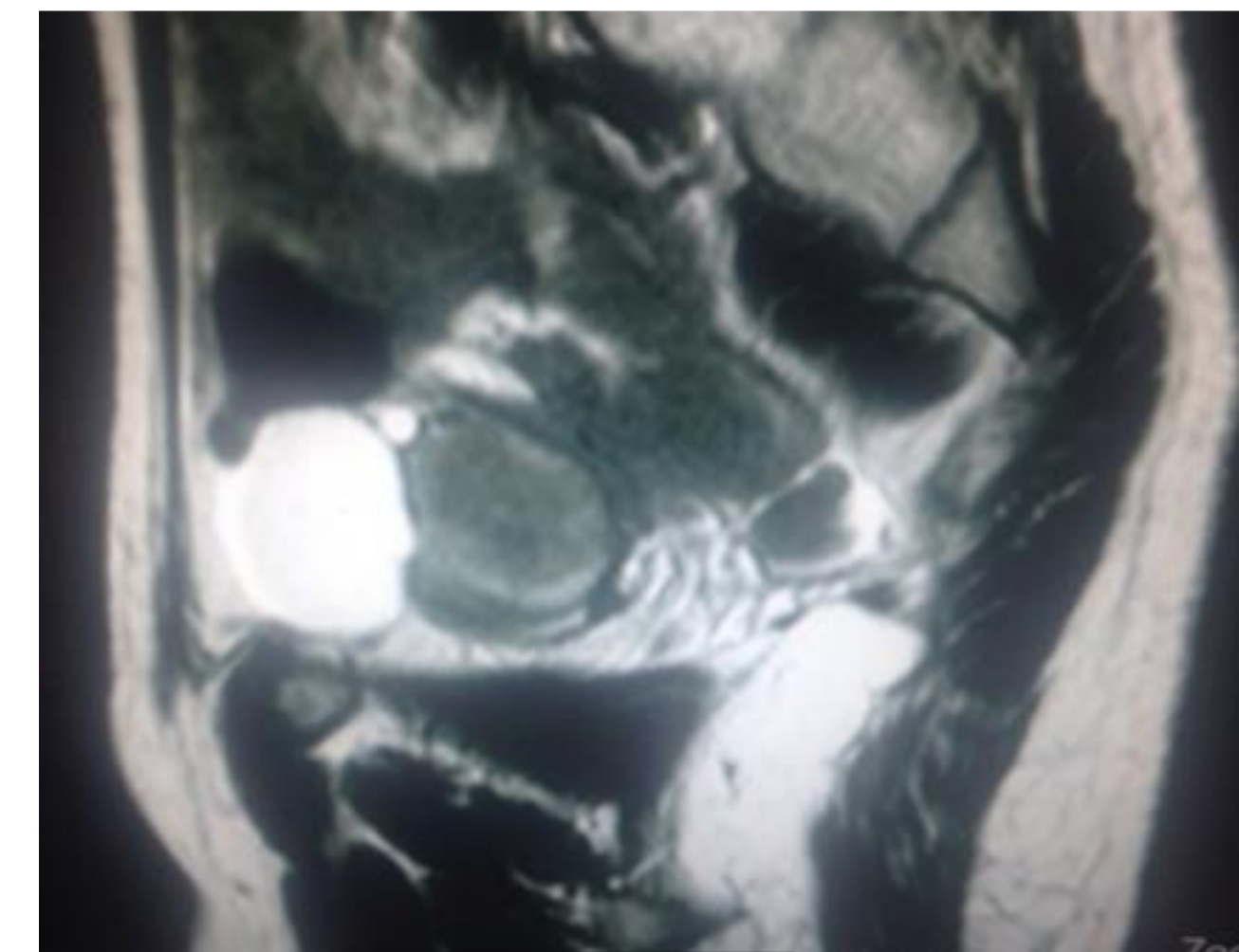


Figure 1

Figure 2. Left testicle parenchyma of atrophic appearance with T2-weighted MRI on the coronal plain and paratesticular cyst formation with fine septum adjacent to the anterolateral area

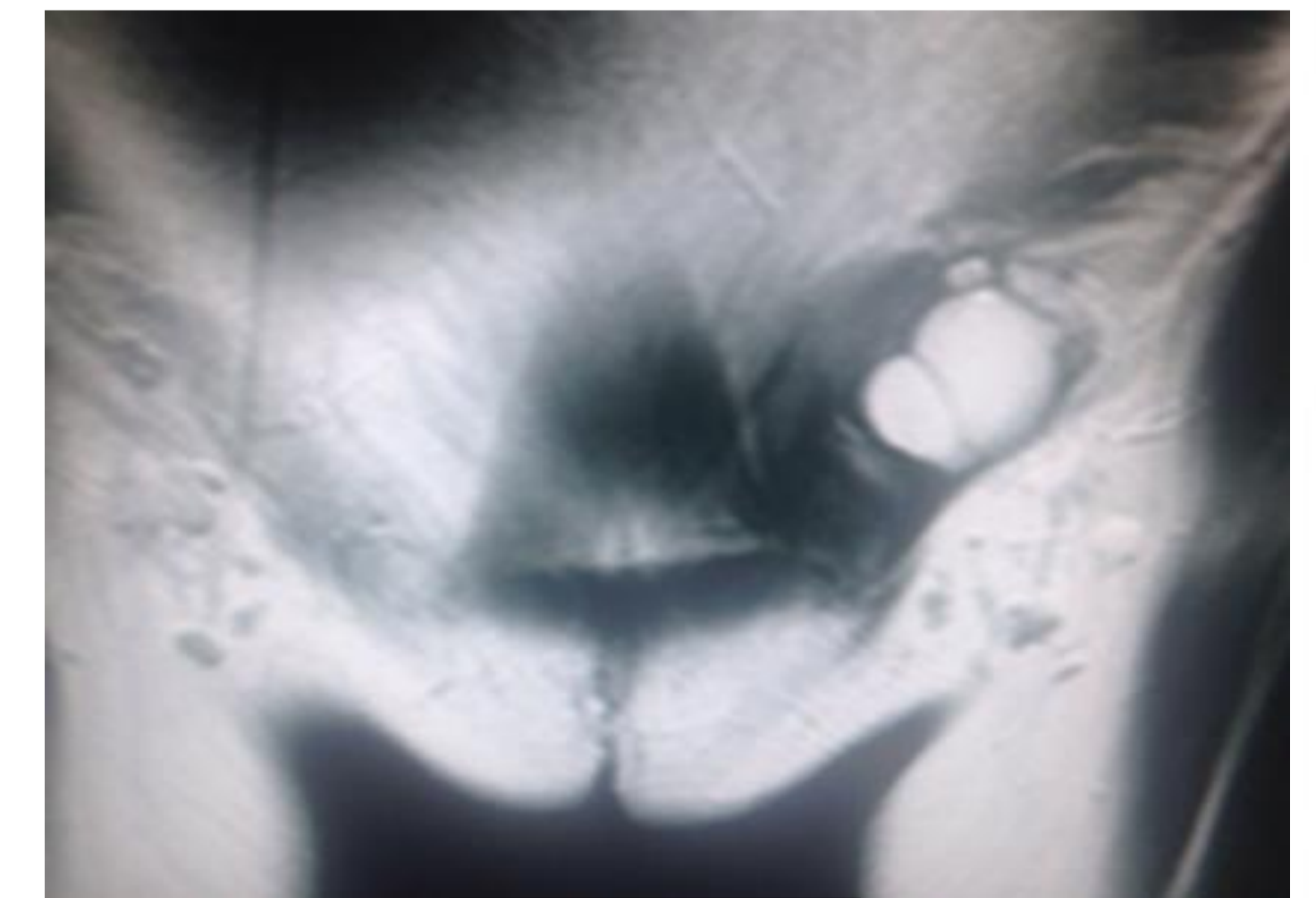


Figure 2

With her physical examination, laboratory and imaging results, she was diagnosed with complete androgen insensitivity and was assessed by the Sexual Orientation and Gender Identity Committee. It was decided to perform gonadectomy due to the risk of malignancy. Intraoperative images of the gonads are given in Figure 3 and 4. As a result of the histological analysis of the biopsy materials taken from the gonads, the patient was diagnosed with well-differentiated sertoli cell tumor and right side unilateral leiomyoma. Besides, Mullerian (Tuba uterina) and Wolfian cystic structures were observed. Figure 5 show histopathologic images of the patient.

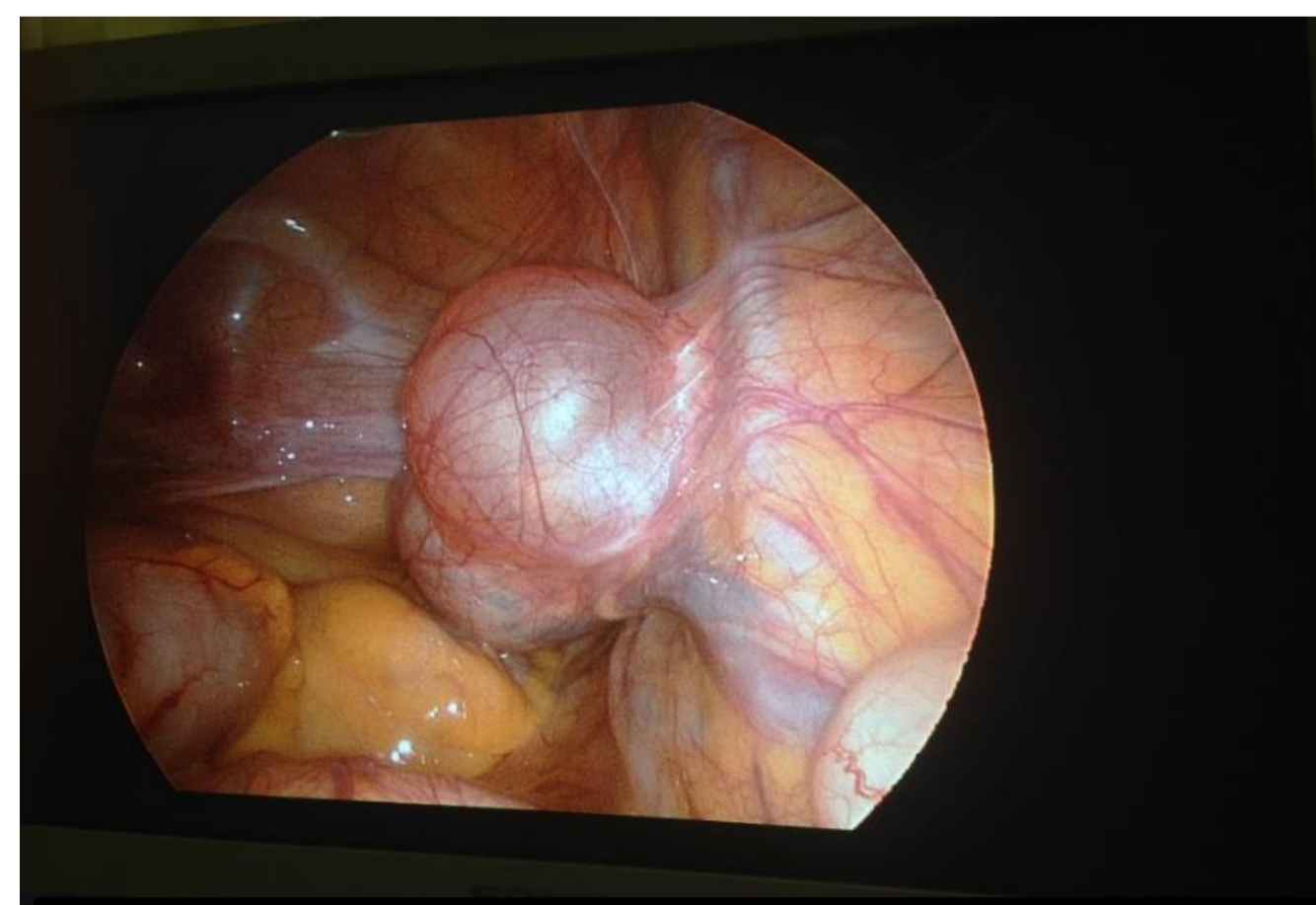


Figure 3. Laparoscopic image of the right intraabdominal gonad

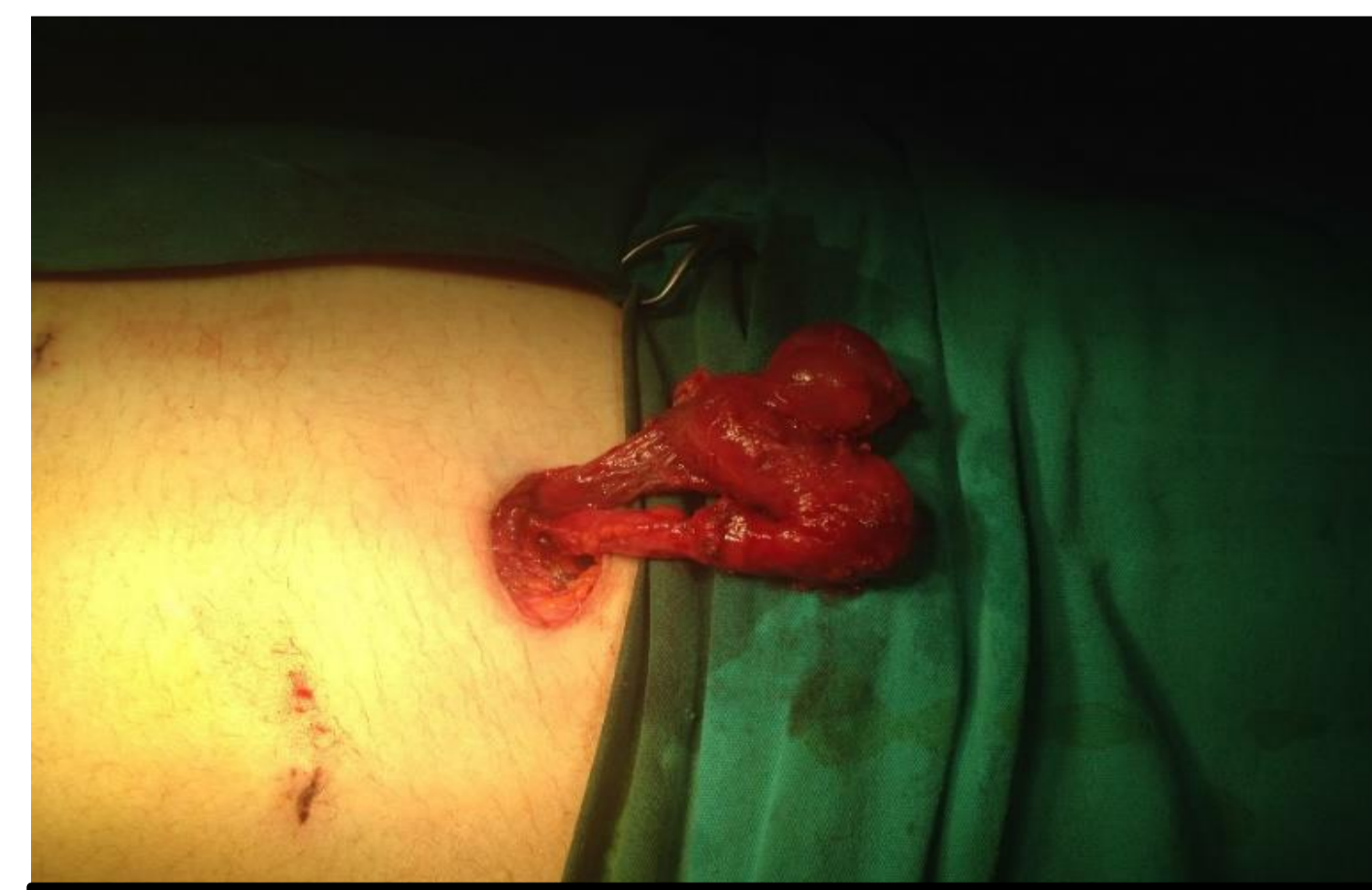

Figure 4. Intraoperative image of the left inguinal gonad

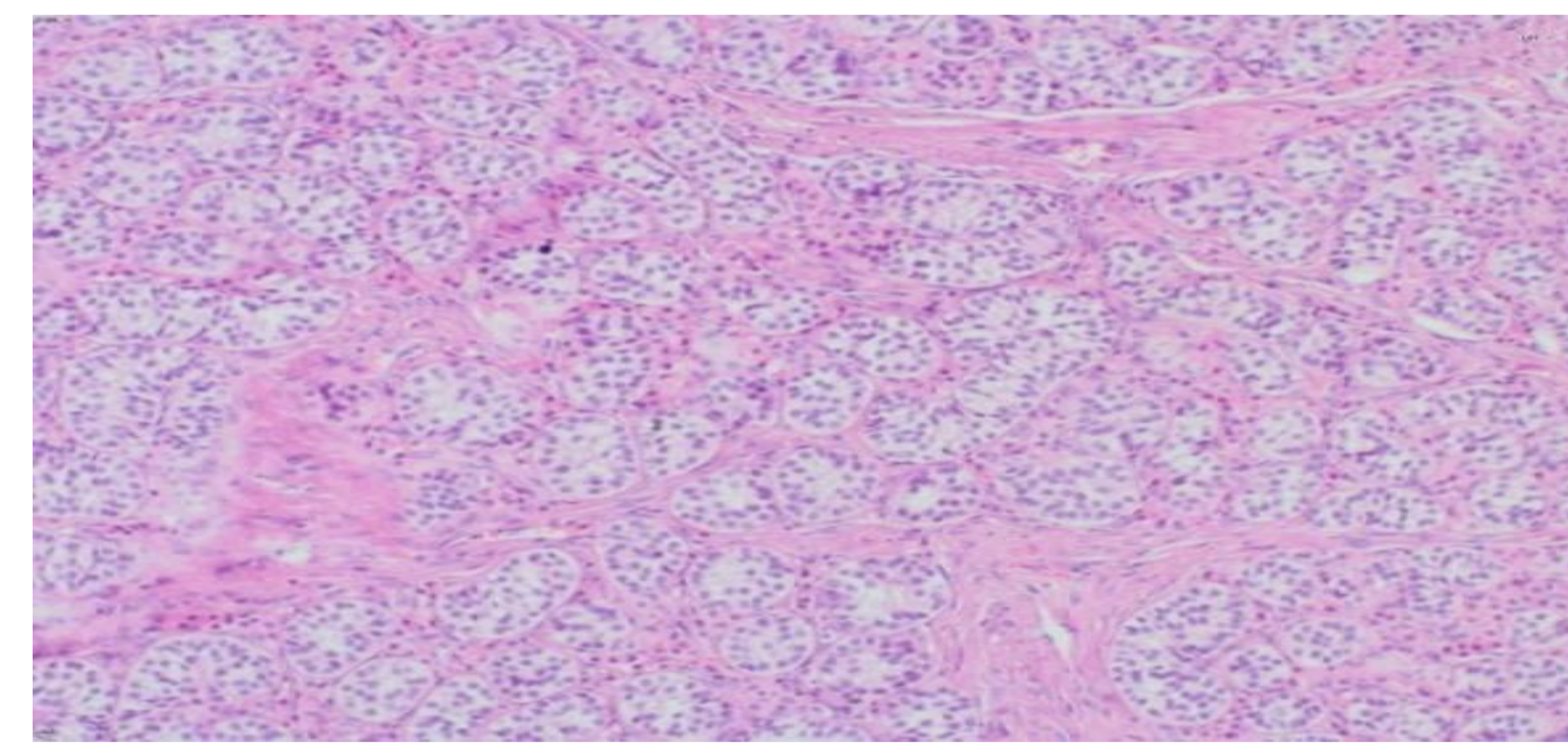


Figure 5. Mature-looking sertoli cells forming a tubular structure and leydig cells are seen in the thin narrow fibrotic stroma in the tumoral tissue

CONCLUSION

The testes in androgen insensitivity syndrome are at risk of development of tumors. The origin of the tumors can be the testicular germ cells, testicular stroma cells, or other mesenchymal cells that give rise to hamartomatous tumors with muscular or other elements. The presence of leiomyomas is extremely rare in removed gonads from AIS patients, with only three similar cases reported in the literature. The case we present is a very rarely reported case in the literature with right paratesticular leiomyoma developing concurrently with bilateral Sertoli cell adenomas.

