

Two cases with decelerated linear growth, normal growth hormone (GH) – insulin-like growth factor –I(IGF-I) axis with an exceptional response to GH therapy.

Fawzia Alyafie¹, Ashraf Soliman[#]

Departments of Pediatrics Hamad Medical Center, Doha Qatar 1, and Alexandria University Children's Hospital # Egypt #.



Introduction

Idiopathic short stature (ISS) describes short children with normal GH secretion. Although GH treatment increases their heights, growth response to the therapy differs among patients. Exceptional fast growth in response to GH therapy in these children should be reported and studied in details to enable scientist to delineate the different etiologies behind this broad term of ISS.

We are reporting two cases with ISS who showed an exceptionally good response to GH therapy that surpassed their mid-parental height SDS.

Case Study

We are reporting two children aged **5 years and 9 years** diagnosed with ISS. They presented with short stature with normal birth measurements and nutritional history. On examination They did not have dysmorphic features, skeletal anomalies, goitre or dyspigmentation and the rest of their examination was unrevealing. GH response to provocation was normal. They had normal CBC, liver and renal functions, sweat chloride, ESR and thyroid function. MRI showed normal pituitary gland.

Treatment and results

A trial of GH therapy was started (0.035 mg/kg/day S.C. HS) with a follow-up every 6 months. Significant growth response to GH was noted that exceeded their genetic background (mid-parental HtSDS) (table 1)

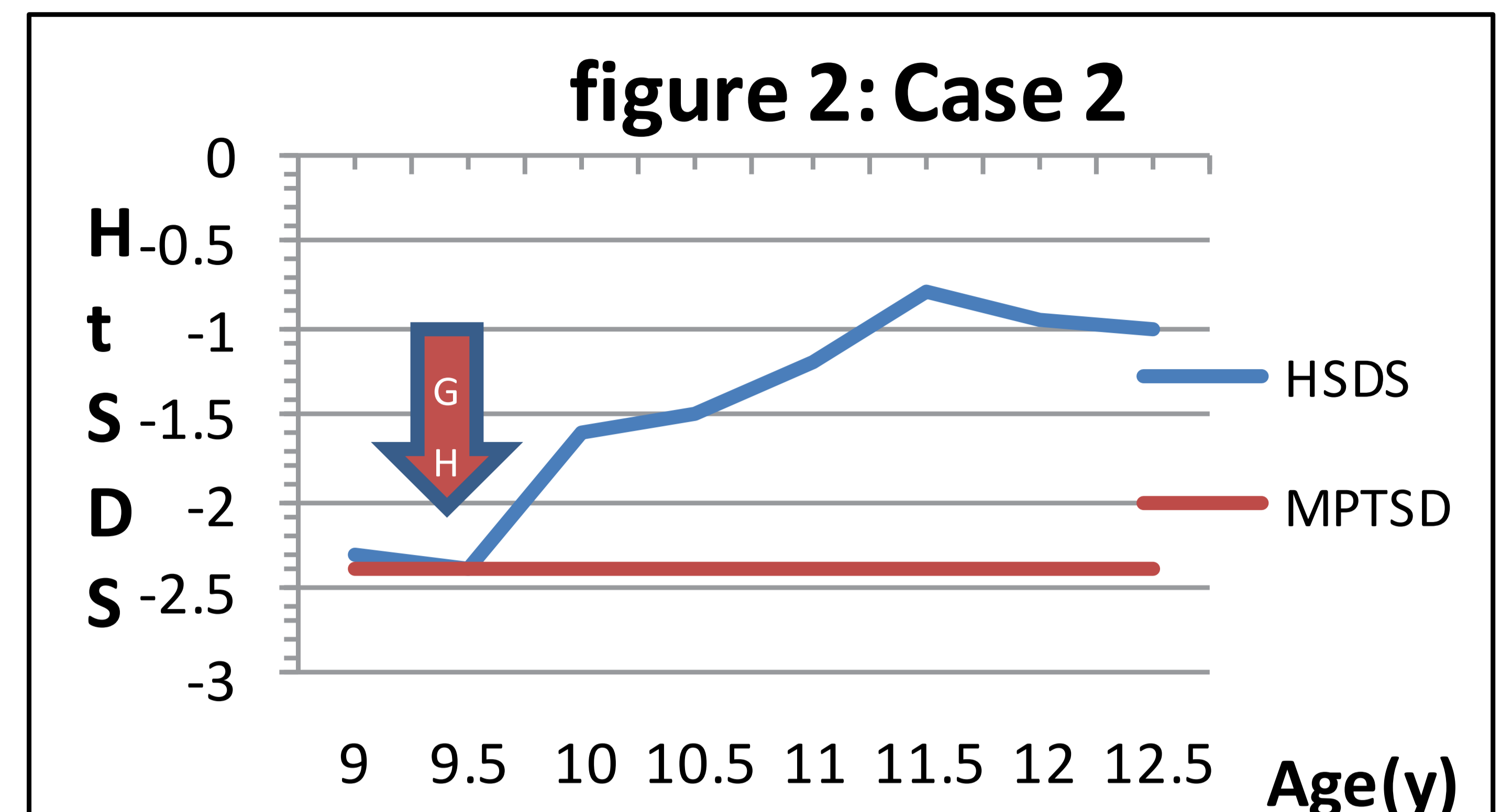
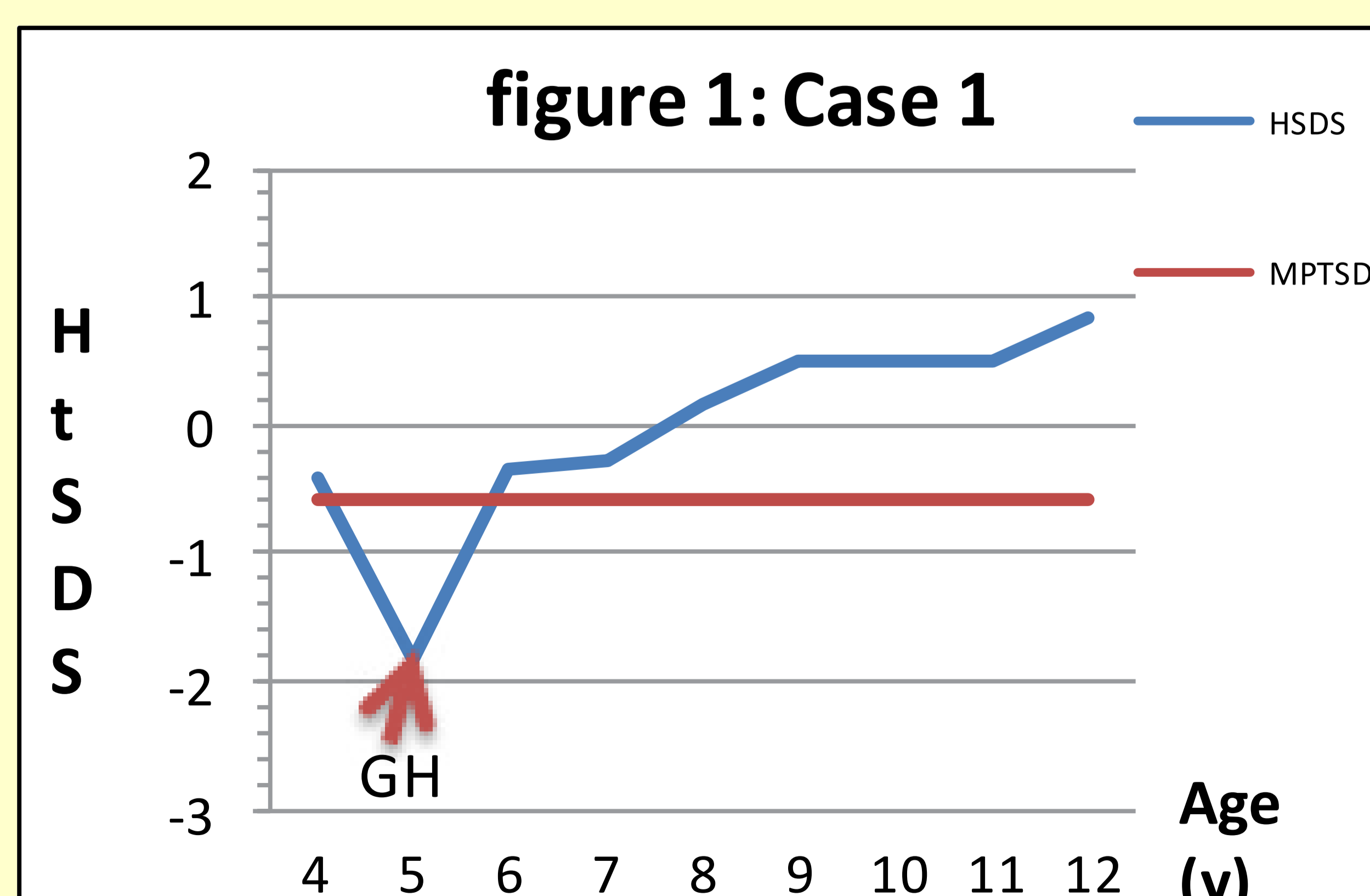


Table 1	Case 1	Case 2
Age	5	9
Bone age	4	8.5
GVSD/year	-5	-1.1
IGF1SDS	-1	-2
Peak GHST (ng/dl)	10	18.5
HTSD pre treatment	-1.84	-2.4
Estimated adult HT pre treatment	164 cm	144 cm
Duration of treatment with GH	7years	3.5years
HTSD post treatment	0.83	-1
Estimated adult HT post treatment	181 cm	156.5cm
Mid parental HtSDS	-0.6	-2.37

Results

The results of therapy figure 1,2 and table1 showed significant catch-up of growth during the treatment which was fast initially and then maintained at a slower pace during the following years. Puberty started at the age of 11years for both with normal progress.

Conclusion

Two children with ISS presented with decelerated growth rate, normal GH response to provocation, one with low IGF-I and the other with normal IGF-I level. Both responded well to the GH therapy to surpass their mid-parental height SDS.

