

PATIENT WITH CLASSIC PHENOTYPE OF HYPOCHONDROPLASIA AND DELETION OF THE GENE SHOX

Amoretti S³, Domínguez M¹, Ropero E³, Campos A¹, Clemente M¹, Fernández P², Yeste D¹.

¹Pediatrics Endocrinology Department. Hospital Materno-Infantil Vall d'Hebron, Barcelona

²Genetics Department. Hospital Vall d'Hebron, Barcelona

³Pediatrics Department. Hospital de Mataró, Barcelona

INTRODUCTION:

Hypochondroplasia is an osteochondrodysplasia inherited in an autosomal dominant pattern that results in a disproportionately short stature, characteristic facial features and skeletal alterations such as lordosis and *genu valgum*. Haploinsufficiency of the fibroblast growth factor receptor 3 gene (FGFR3) is responsible for 50-70% of the cases, but a negative result doesn't rule it out.

CASE REPORT:

We report an 11 year and 10 month old boy with family history of disproportionately short stature and personal background of small for gestational age (39 weeks, birth weight 2020 g (-3.2 SD), length 44.5 cm (-3.2 SD).

He begins puberty at the age of 10.

PHYSICAL EXAMINATION:

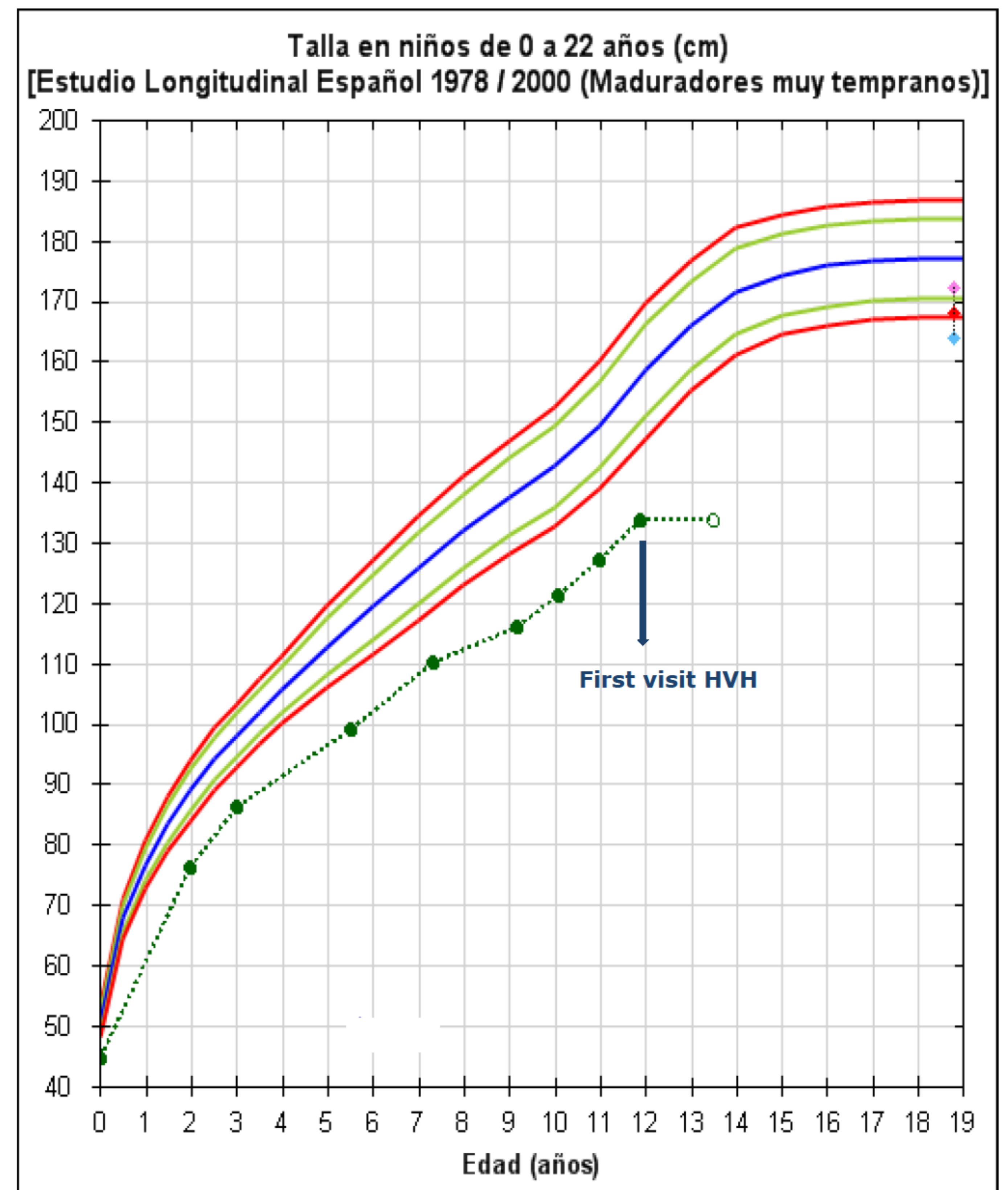
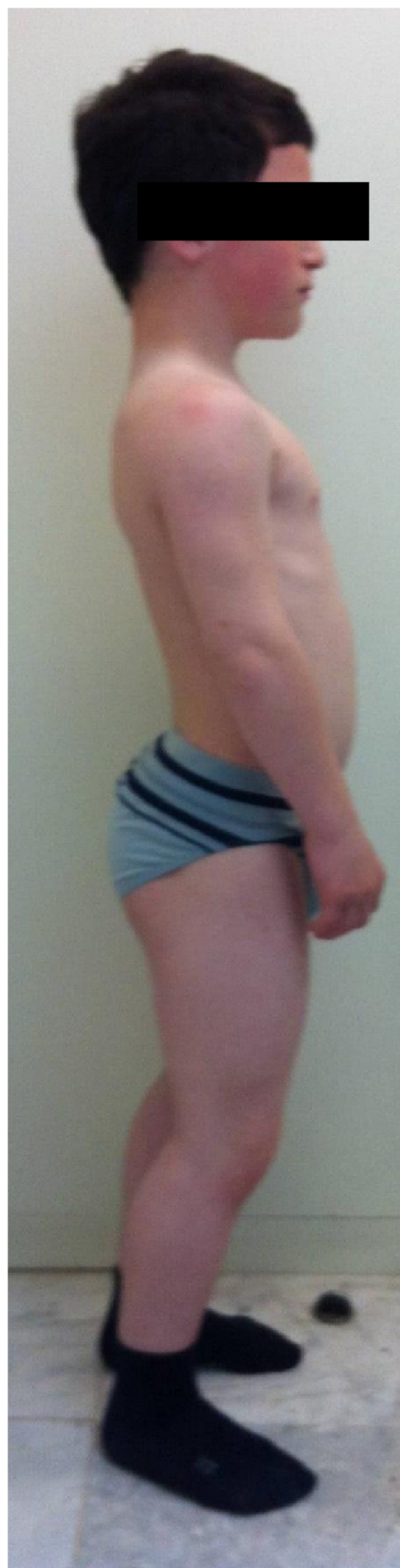
Weight: 37.6 Kg (-0.53 SD)

Height 133.5 cm (-2.1 SD)

Sitting height-to-standing height ratio (SH/S) 0.57 (>97)

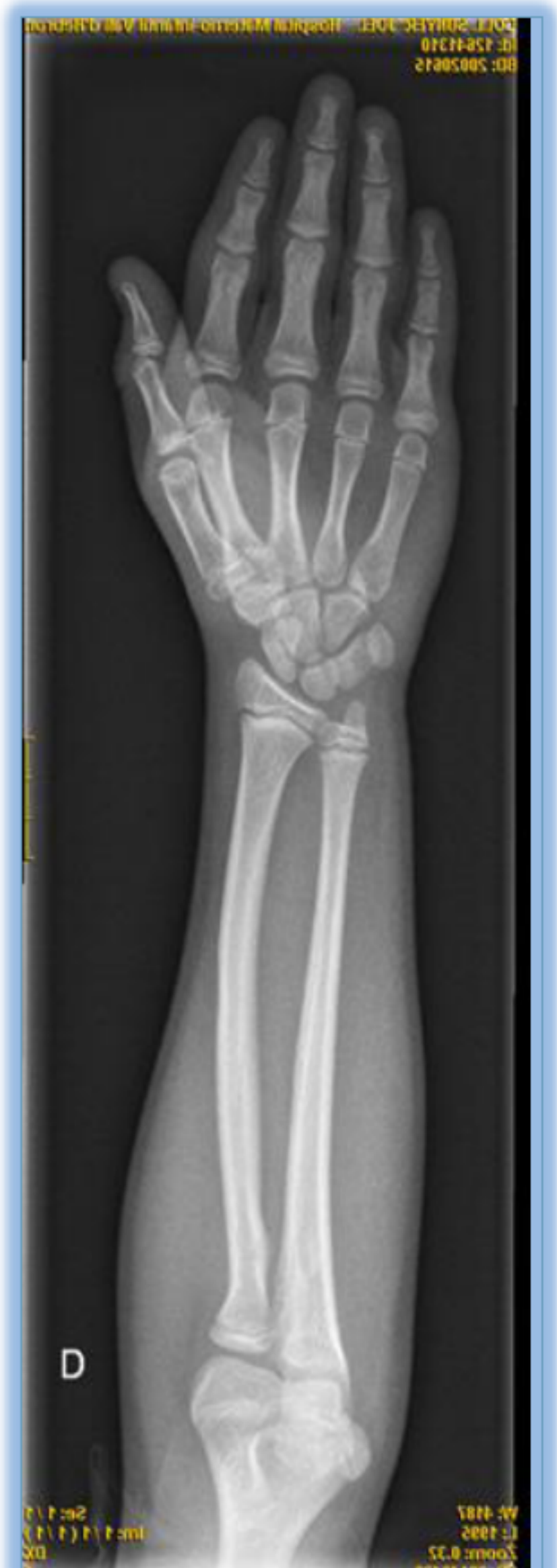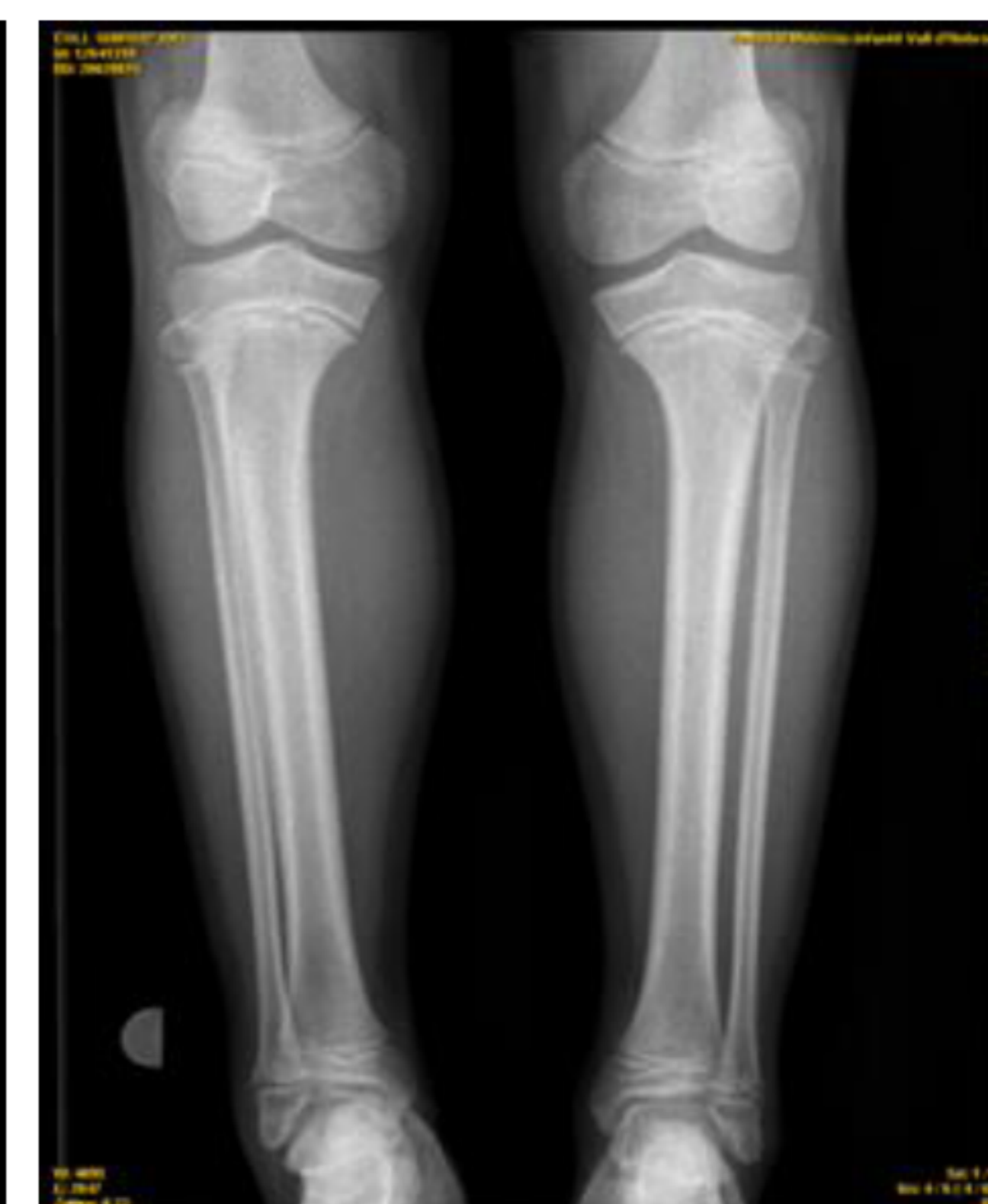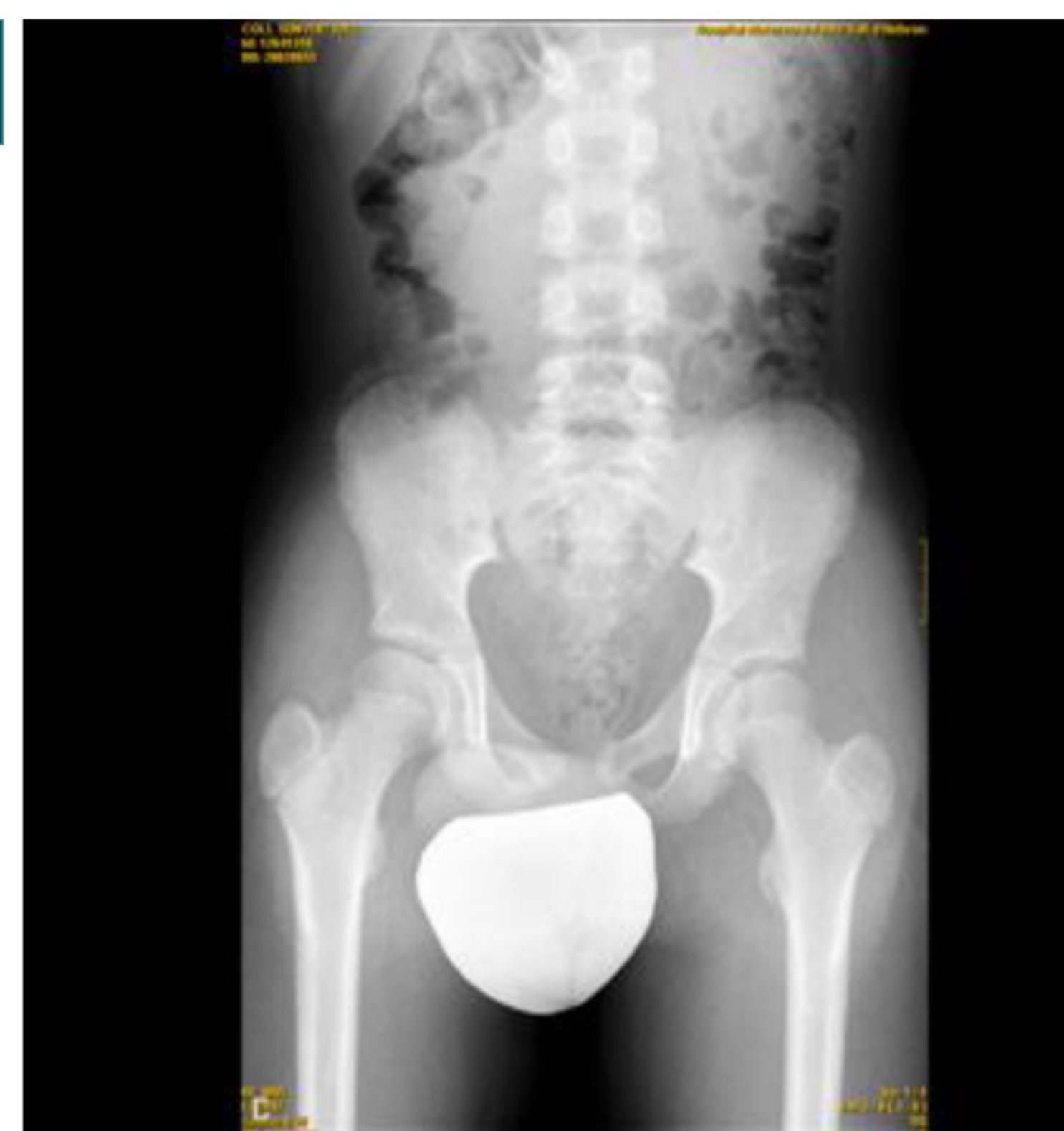Tanner IV (20-20 cc)

Clinical features suggestive of hypochondroplasia with facial dysmorphism with frontal bossing, large hands with enlargement of interphalangeal joints, short and wide fingers, limited forearm supination and short limbs with rhizomelia, and significant muscle hypertrophy.



COMPLEMENTARY EXAMINATION:

- **Skeletal survey:** Rhizomelia, Madelung's deformity and widened lumbar interpeduncular distance.
- **Bone age:** 14 years.
- **Molecular genetic analysis of FGFR3:** Negative.
- **HCG-ARRAY:** 0.045 Mb deletion of the regulation region of the gene SHOX, found as well in the mother and the siblings.



CONCLUSION:

In patients with clinical features suggestive of hypochondroplasia and negative result in molecular genetic analysis of FGFR3, defects in the gene SHOX should be ruled out.

- Song et al. New Proposed Clinico-Radiologic and Molecular Criteria in Hypochondroplasia: FGFR 3 Gene Mutations Are Not the Only Cause of Hypochondroplasia. American journal of medical Genetics .June 2012
- Korkmaz HA et al. Hypochondroplasia in a Child with 1620C>G (Asn540Lys) Mutation in FGFR3 ,J Clin Res Pediatr Endocrinology 2012;4(4):220-222