

# Hyperinsulinism secondary to congenital portosystemic shunt in a neonate

Department of Pediatrics, Soonchunhyang University Hospital of Bucheon, Korea

Yong Hee Hong, Dong Hoon Lee, Sung Shin Kim

SCH

## Introduction

Hyperinsulinism is a common cause of persistent hypoglycemia in infant. Insulin secretion from pancreatic  $\beta$ -cells is unregulated and inappropriate for the level of blood glucose, causing glucose into the insulin-sensitive tissues, such as the muscle, liver and adipose tissue, leading to hyperinsulinemic hypoglycaemia. But congenital portosystemic shunt, a rare vascular malformation, can cause hyperinsulinemic hypoglycemia very rarely because glucose from portal to systemic circulation causes early hyperglycemia leading to exaggerated insulin secretion, leading to bypassing the hepatic metabolism directly entering into the systemic circulation, which results in hyperinsulinemia, then in turn causes late hypoglycemia.

## Case

**Chief Complaint :** 1-day-old female neonate was referred for hypoglycemia without response in intravenous 10% glucose infusion.

**Birth History :** 38 weeks via cesarean section, birth weight 3.3 kg. Second child of healthy parents.

**Laboratory Findings :** insulin/glucose ratio 1.98

glucose 34 mg/dL (normal range : 60-108 mg/dL), insulin 67.43 uIU/mL (normal range : 12-25 uIU/mL)

**Imaging Study**

**Abdominal USG - normal pancreas and intrahepatic portosystemic shunt ;**

middle hepatic vein-medial segmental portal vein, left hepatic vein-S2, S3 segmental portal vein(Figure 1)

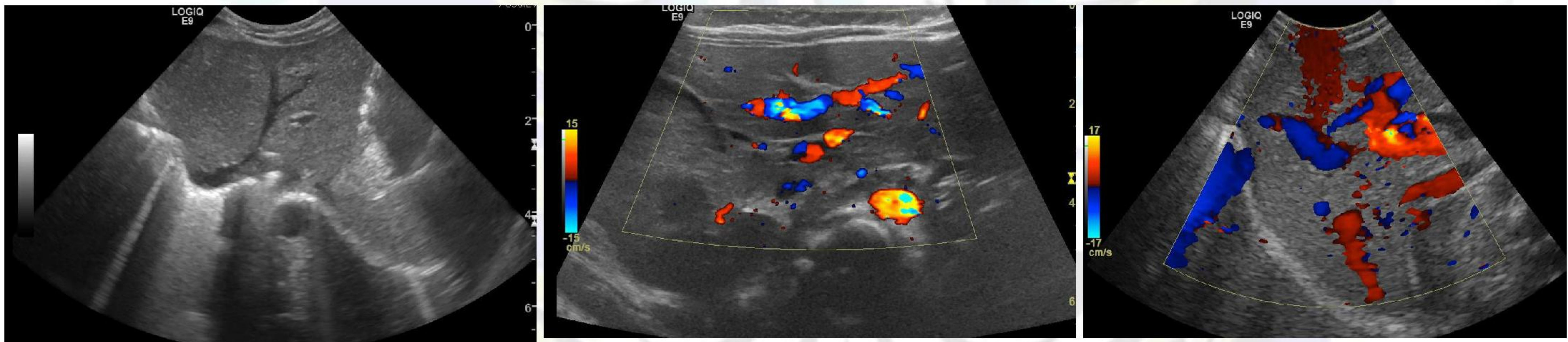


Figure 1

**Liver dynamic CT - Intrahepatic portosystemic shunt - middle and left hepatic vein between left portal vein**

**Hypoplasia of right portal vein(Figure 2)**

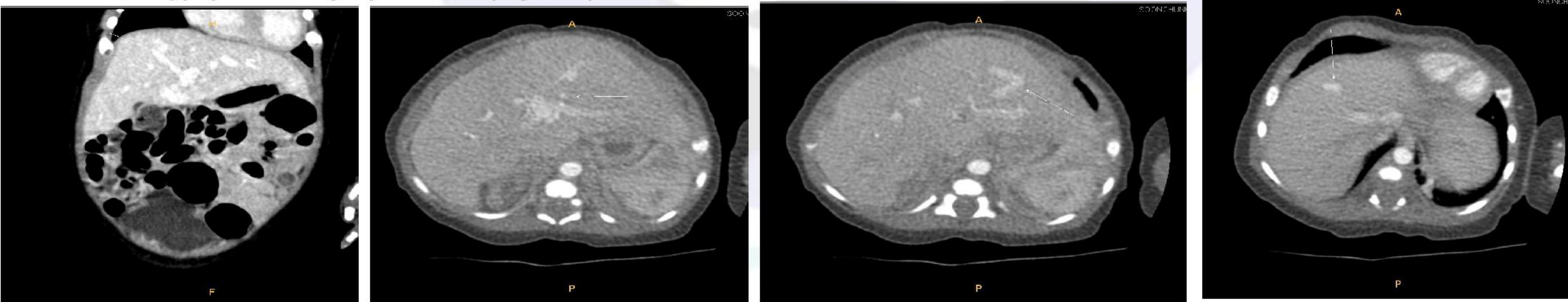


Figure 2

**Clinical Course :** After 9 days of conservative treatment, the baby's symptom and sign disappeared, and blood test was normalized. She was discharged without transcatheter embolization. After 2 months, size of the shunt was reduced in abdominal ultrasonography.

## Conclusion

Even though rare, congenital portosystemic shunt can cause hyperinsulinism and hypoglycemia in infant, so imaging study is needed about vasculature in liver with pancreas, avoiding unnecessary treatment, for example, diazoxide.

