

# Testotoxicosis: be careful to predict the final height!

SOUZA L. G. , BASTOS P. M. V. , PINHEIRO C. T. C. , COMINATO L. , STEINMETZ L. , MENEZES FILHO H. C. , KUPERMAN H. , DICHTCHEKENIAN V. , MANNA T. D. , DAMIANI D.

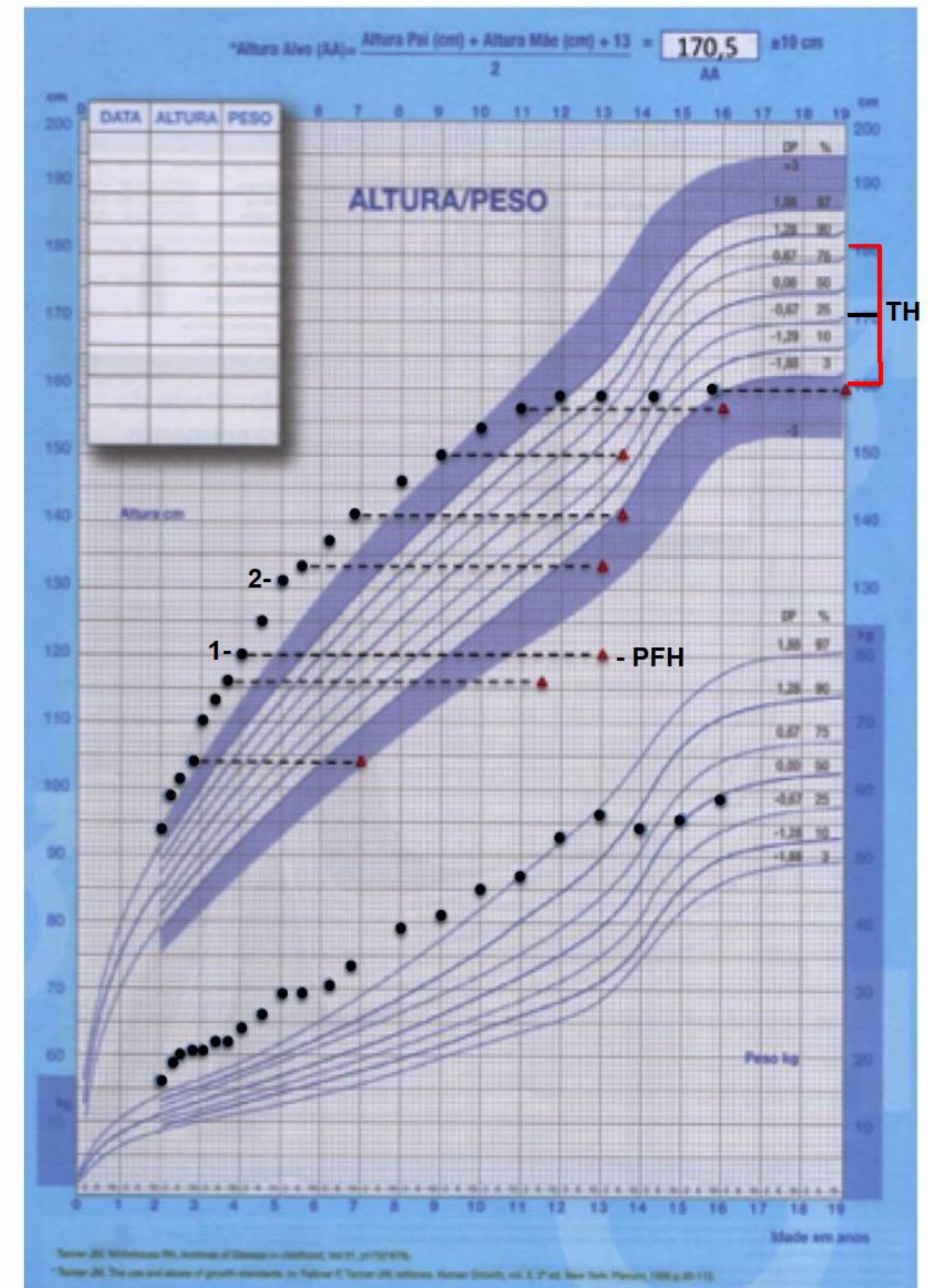
Instituto da Criança, Universidade de São Paulo, Brasil.

## BACKGROUND

Familial male-limited precocious puberty, known as testotoxicosis, is an autosomal dominant disease that leads to the activation of luteinizing hormone receptor. It presents with progressive virilization, advanced bone age and linear growth acceleration and may lead to loss in predicted adult height. We report the case of a patient diagnosed with testotoxicosis at two years of age.

## CASE PRESENTATION

Two-year-old boy with penis enlargement and pubic hair. On physical examination, muscle hypertrophy, Tanner G3P2, 10cm penis, 94cm tall (Z-score + 2.25). Lab work-up: Total Testosterone 734.5 ng / dL, bone age seven years. He was treated with ketoconazole, spironolactone, cyproterone acetate and anastrozole, with partial response, although maintaining high concentrations of testosterone, progress of bone age and of growth velocity, and growth of the right testicle. At age four, scrotum US showed testicular microlithiasis on the right side; on biopsy, there was intense focal proliferation of Leydig cells without atypia and indefinite limits. He was submitted to right orchiectomy associated with treatment with leuprolide acetate (due to secondary gonadotropin-dependent precocious puberty – GDPP), with stabilization of bone age. At age 16, his height was 160 cm, within the family target.



Growth and weight gain chart with target height (TH) and bone age.

● Weight and Height ▲ Bone Age

1- GnRH analog / 2- right orchiectomy / PFH- 141,1cm

## CONCLUSION

The treatment of testotoxicosis aims to stop the progression of puberty and avoid the loss of the final height. Despite the therapeutic difficulty, and the advancement of bone age, the patient reached the familial target height. The predicted final height (PFH) when he was 4 years old was 141,1cm and yet he reached the familial target height. The presence of microlithiasis raised the suspicion of a testicular tumor, not confirmed, with subsequent orchiectomy. The induction of a GDPP demanded blocking with leuprolide acetate, which may have contributed to a favorable outcome in adult height.

