



CENTRAL HYPOTHYROIDISM AND GROWTH HORMONE DEFICIENCY IN A BOY WITH WILLIAMS-BEUREN SYNDROME

Sara Ciccone¹, Adriana Fumarola¹, Stefania Bigoni², Valentina Bonifacci¹, Elisa Maria Gabriella Marrella¹, Barbara Buldrini², Cristina Host¹

¹ Pediatric Unit, Department of Reproduction and Growth, S. Anna University Hospital, Ferrara, Italy
² Medical Genetics Unit, Department of Reproduction and Growth, S. Anna University Hospital, Ferrara, Italy

Thyroid disorders (subclinical hypothyroidism and structural abnormalities) are common in WS patients.

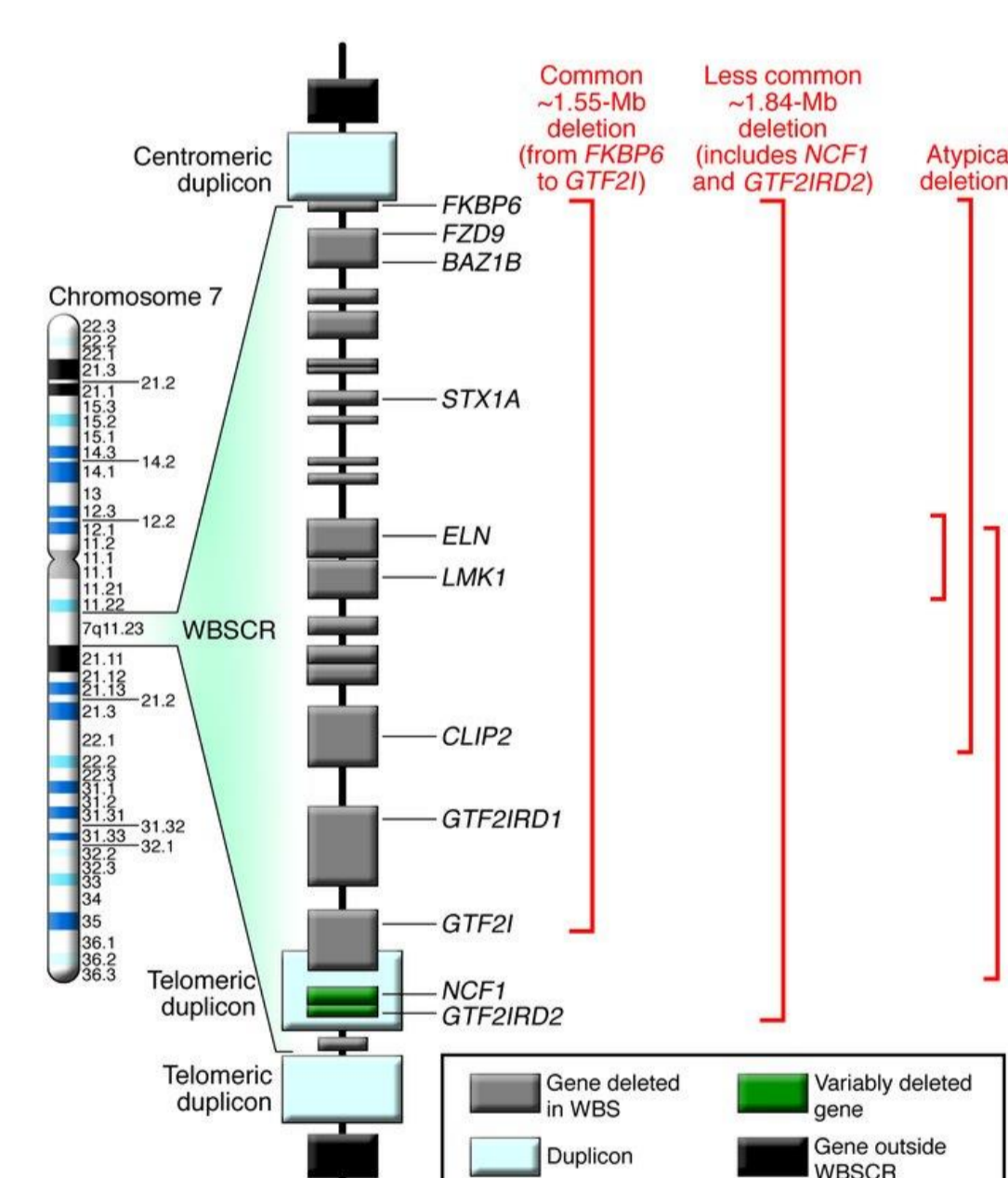
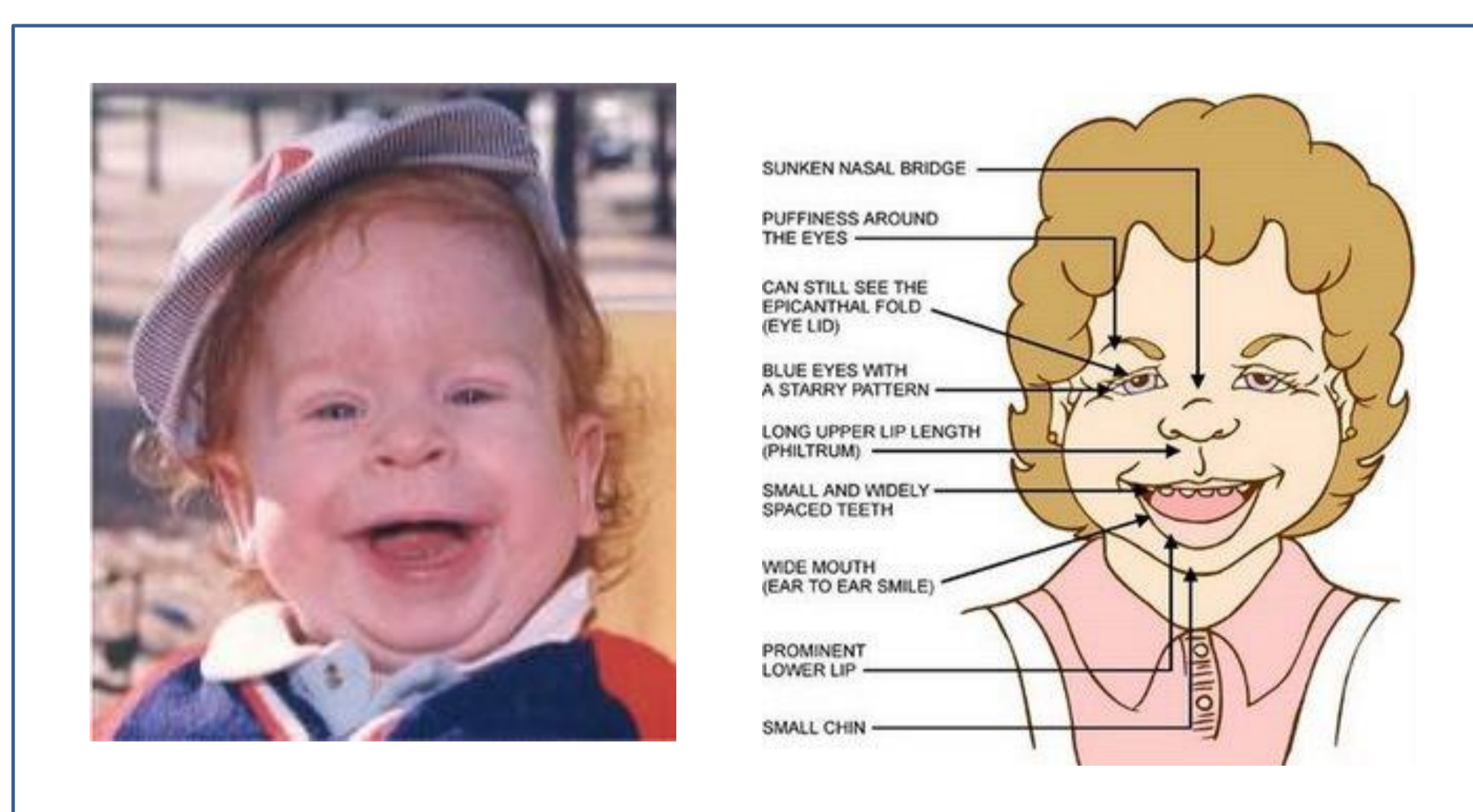
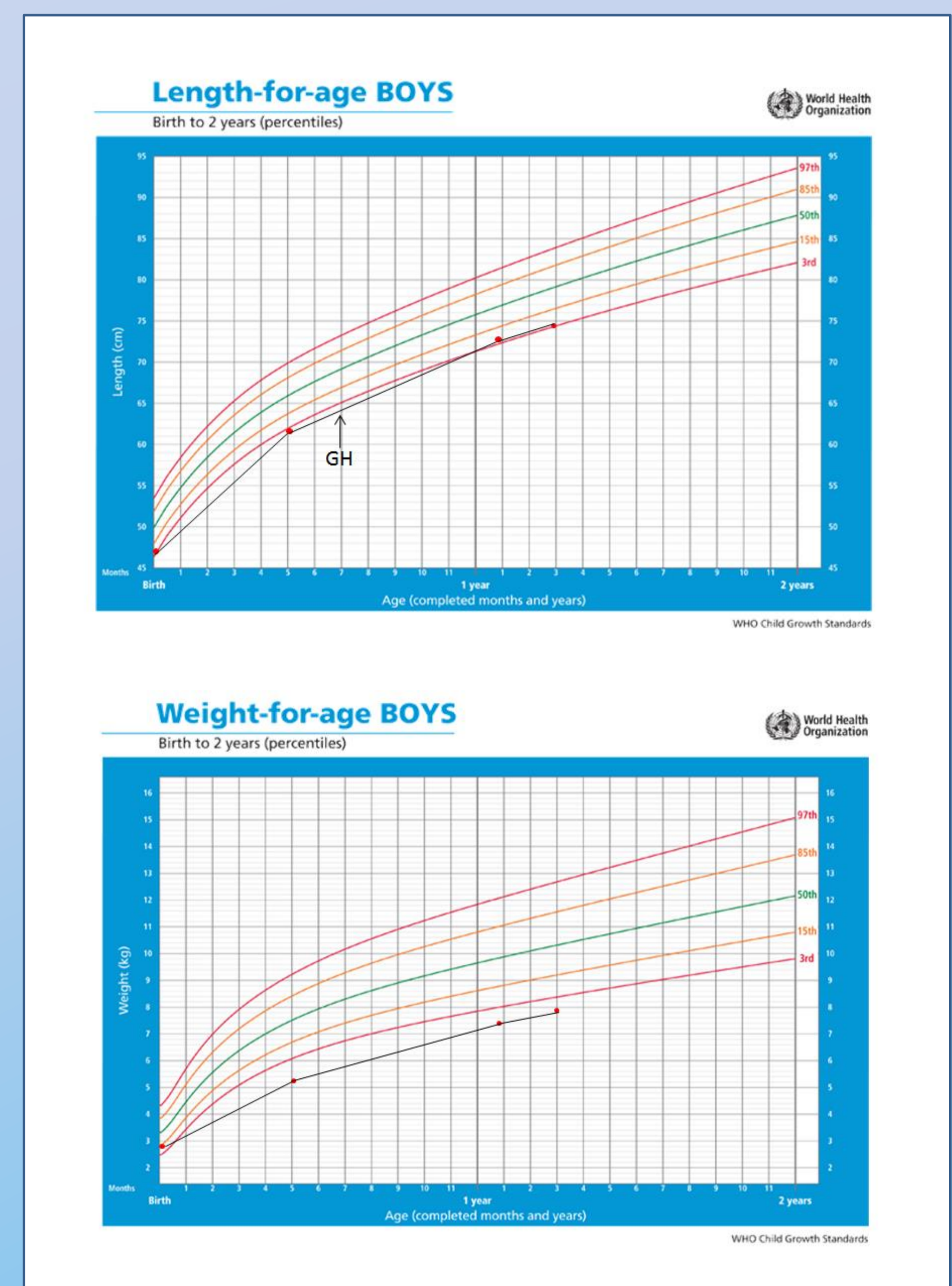
A 5-month-old male was admitted to our hospital because of growth failure since the 3rd month, mild dysmorphisms, micropenis.

He was a second-born at term from non-consanguineous parents. During pregnancy the mother has been treated with levothyroxine for a Hashimoto's thyroiditis. After birth, the baby presented normal adaptation parameters, weight g 2880 (3rd-10th), length cm 48 (3rd-10th), head circumference cm 33 (3rd-10th); later mild jaundice, without history of hypoglycemia or calcium disorders was reported. No thyroid dysfunction was detected by screening test.

At admission (5 months), weight was g 5670 (<3rd), length cm 63 (3rd), head circumference cm 40 (<3rd); no neurological abnormalities or heart murmurs were noted. Main signs observed at the dysmorphological evaluation were: fullness of the peri-orbital structures, epicanthal folds, full cheeks, small upturned nose with long philtrum and down-turned corners of the mouth, micropenis.

Blood tests revealed a **CENTRAL HYPOTHYROIDISM** (FT4 0.72 ng/dl, TSH 3.53 mcUI/ml) associated to a GHD documented by two classic stimulation tests (peak of GH: 1.89 ng/ml, 1.76 ng/ml), IGF-1 6,8 ng/ml. Remaining pituitary gland function and structure was normal at MRI. Ultrasonography showed a reduced thyroid volume, particularly the left lobe (in levothyroxine replacement). Echocardiogram resulted unremarkable. Blood tests also revealed a mild hypercalcemia (max value of 2.7 mmol/l, normal range 2.1-2.6 mmol/l).

Levothyroxin was started (up to 2 mcg/kg/die) with a prompt normalization of FT4. hGH therapy was also initiated at a dose of 0,16 mg/kg/week with a growth improvement.



GENETIC TESTS (FISH) revealed a 7q11.23 microdeletion, confirming the suspected diagnosis of WS.

Array-CGH is now ongoing to define the extension of the deletion and to understand if the involvement of other genomic regions, contiguous to the WS critical region or not, can contribute to this endocrinological picture.

CONCLUSION: IN ADDITION TO THE PERIPHERAL FORMS, ALSO A CENTRAL HYPOTHYROIDISM CAN BE FOUND IN WS. OUR PATIENT ALSO SHOWED A GHD, THAT IS RARELY REPORTED IN WS.

- Cambiaso P, Orazi C, Digilio MC, Loche S, Capolino R, Tozzi A, Faedda A, Cappa M. Thyroid morphology and subclinical hypothyroidism in children and adolescents with Williams syndrome. J Pediatr. 2007 Jan;150(1):62-5.
- Dimitriadou M, Christoforidis A, Sarri C, Gyftodimou Y, Athanassiou-Metaxa M. Congenital hypothyroidism as the initial presentation that led to the diagnosis of Williams syndrome. Gene. 2012 Feb 15;494(1):102-4.
- Xekouki P, Fryssira H, Maniati-Christidi M, Amenta S, Karavitakis EM, Kanaka-Gantenbein C, Dacou-Voutetakis C. Growth hormone deficiency in a child with Williams-Beuren syndrome. The response to growth hormone therapy. J Pediatr Endocrinol Metab. 2005 Feb;18(2):205-7.

P3-1172



54th Annual Meeting 1-3 October
ESPE 2015 BARCELONA
 European Society for Paediatric Endocrinology

