

PEDIATRIC THYROID DISEASE: ABOUT A SERIES OF 48 CASES

INTRODUCTION

Thyroid disorders in children and adolescents are varied. They are dominated by frequent malignant tumor lesions and goiters represented by Graves' disease and Hashimoto thyroiditis in adolescence . They are characterized by several clinical forms

Objective : Study the clinical and etiological characteristics of thyroid disease in children and adolescents

METHOD

This is a retrospective descriptive study of observations of thyroid diseases in children and adolescents collected over a 10 year period (2005-2015)

RESULTS

48 cases were reported

Average age of patients was 12.96 years (2-16)

The girls were predominant with 38G / 10B Familial predisposition was found in 46,6 % (n:20)

We observed:

15 cases of hypothyroidism (8 congenital 7 autoimmune).

13 cases of Hyperthyroidism (Graves' disease 100%)

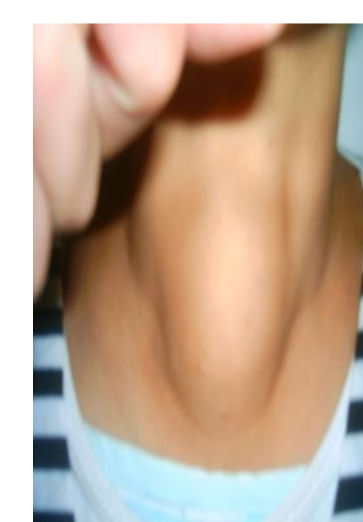12 cases of euthyroid goitre and 6 cases of thyroid nodule . 4 of them were related neoplastic : differentiated thyroid cancer . It was diagnosed at an advanced stage in 50% cases (T4 M1N1)

DISCUSSION

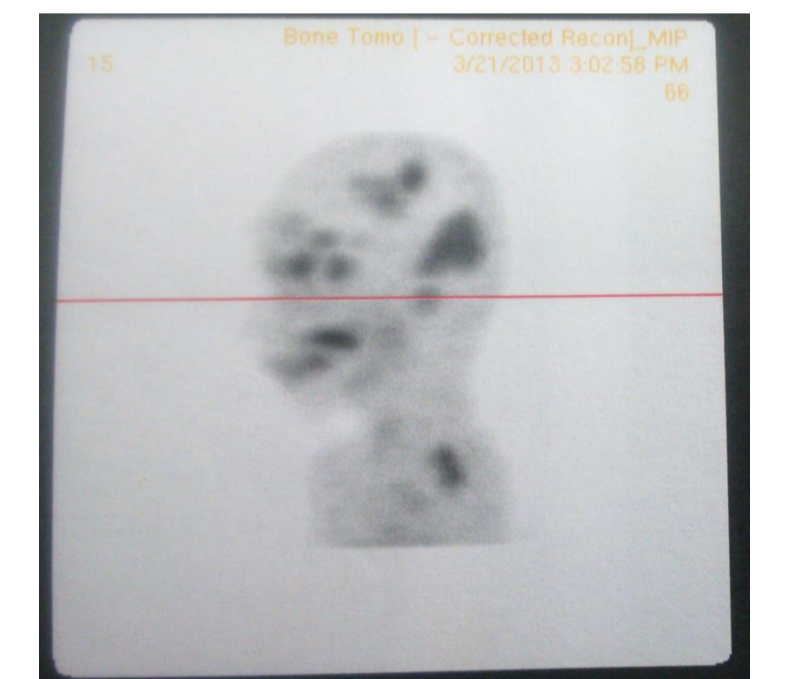
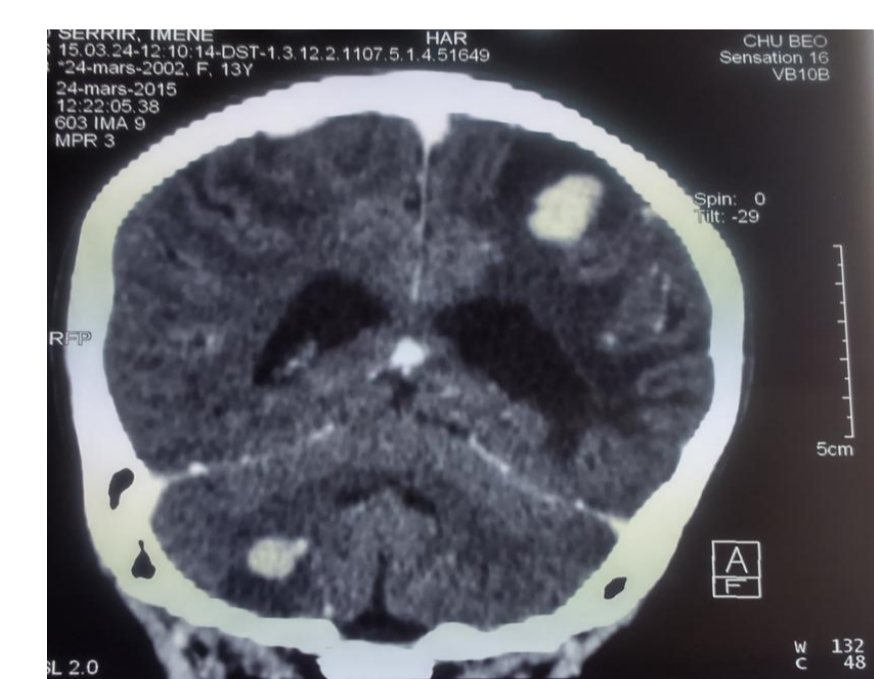
Hypothyroidism is the most common thyroid diseases It is not diagnosed precociously as there is no routine screening in the neonatal period and the signs of hypothyroidism are not recognized . Hyperthyroidism in child is dominated by Graves' disease. The diagnosis is easy. The main difficulty is regarding patient care because the disease is marked by a high risk of recurrence. (antithyroid drugs [ATS], surgery and radioactive iodine) ? We must choose the treatment who gives the best chance of success, taking into account the patient's age, intensity and volume of the signs goiter. . The thyroid cancer is rare in children, but the diagnosis must be an obsession in any thyroid nodule, especially if the child is younger, he has been exposed to radiation or it has family background. it is invasive and generally aggressive at diagnosis

The thyroid nodule in children is much rarer than in the adult population, but the rate of cancer thyroid nodules discovered among these is much higher

Hypothyroidism can be congenital or acquired. It must be recognized and treated precociously to avoid deleterious effect on psychomotor development and growth. Hyperthyroidism in children is dominated by Graves' disease. the diagnosis is easy, the main difficulty is regarding patient care due to frequent relapses. In front of a thyroid nodule, the obsession is thyroid cancer that is characterized by a significant aggressiveness and poor prognosis. Cytology and clinical and morphological monitoring are essential



Congenital hypothyroidism



papillary carcinoma complicated ocular and intracranial metastases

