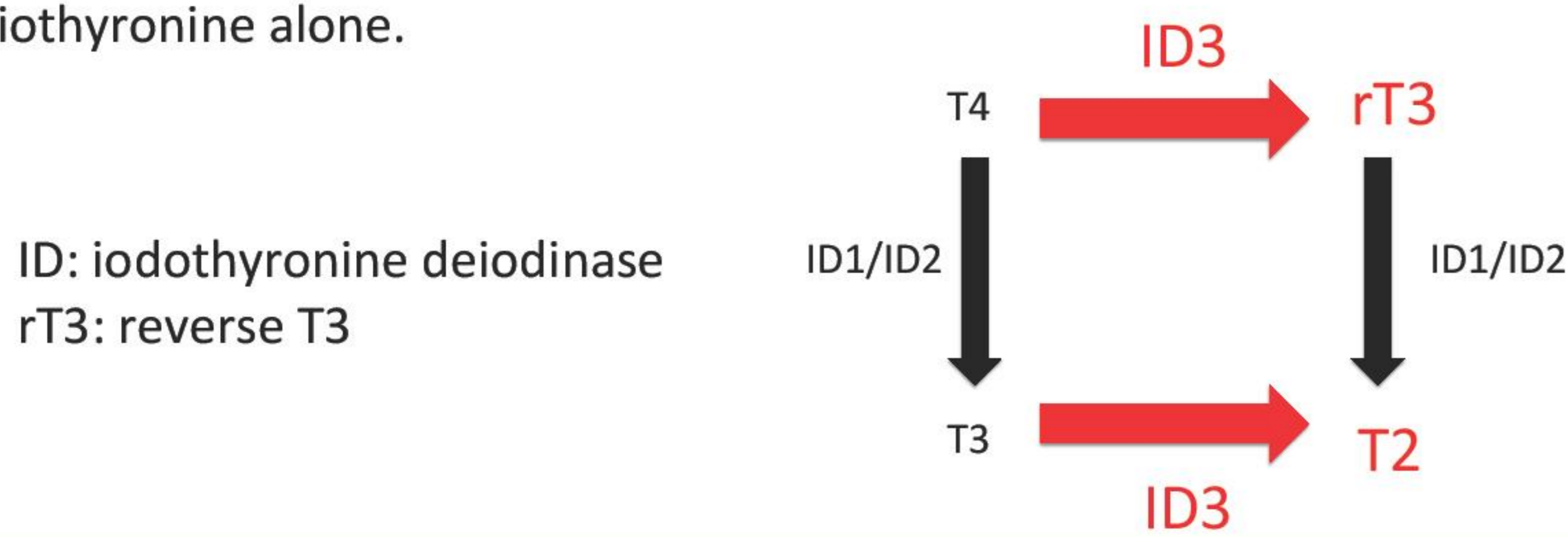


Use of liothyronine in a case of consumptive hypothyroidism caused by hepatic hemangiomas

Shinji Higuchi Masaki Takagi Masahiro Goto Yukihiro Hasegawa
Tokyo Metropolitan Children's Medical Center, Department of Endocrinology and Metabolism

Background

Diffuse or multifocal hepatic hemangiomas cause consumptive hypothyroidism due to overexpression of type 3 deiodinase in the endothelium of vascular tumor. Because type 3 deiodinase converts T4 and T3 into reverse T3 and T2, respectively, administration of levothyroxine alone may not maintain normal levels of both fT3 and fT4. Liothyronine therapy with propranolol in this disorder has been reported in only two papers as far as we know. We here present a Japanese case with multifocal hepatic hemangiomas, whose fT3 were low with fT4 being in the normal ranges. The low level of fT3 improved with administration of liothyronine alone.



Patient Report

Clinical course

Birth: 38w1d, Height 49.0 cm (0 SD), Body weight 3208 g (+0.5 SD), spontaneous cephalic delivery. He had no hypoglycemia, micropenis. He had no exposure to iodine.

1m1d: He was diagnosed as having jaundice in health check.
2m4d: He was referred to our hospital because of jaundice.
2m9d: Abdominal US showed hypoechoic multifocal tumors.
2m10d: Abdominal enhanced CT showed multiple hypervascular liver tumors. According to the enhancement pattern, he was diagnosed as having multifocal hepatic hemangiomas. We checked the tests on thyroid function.

<physical findings>

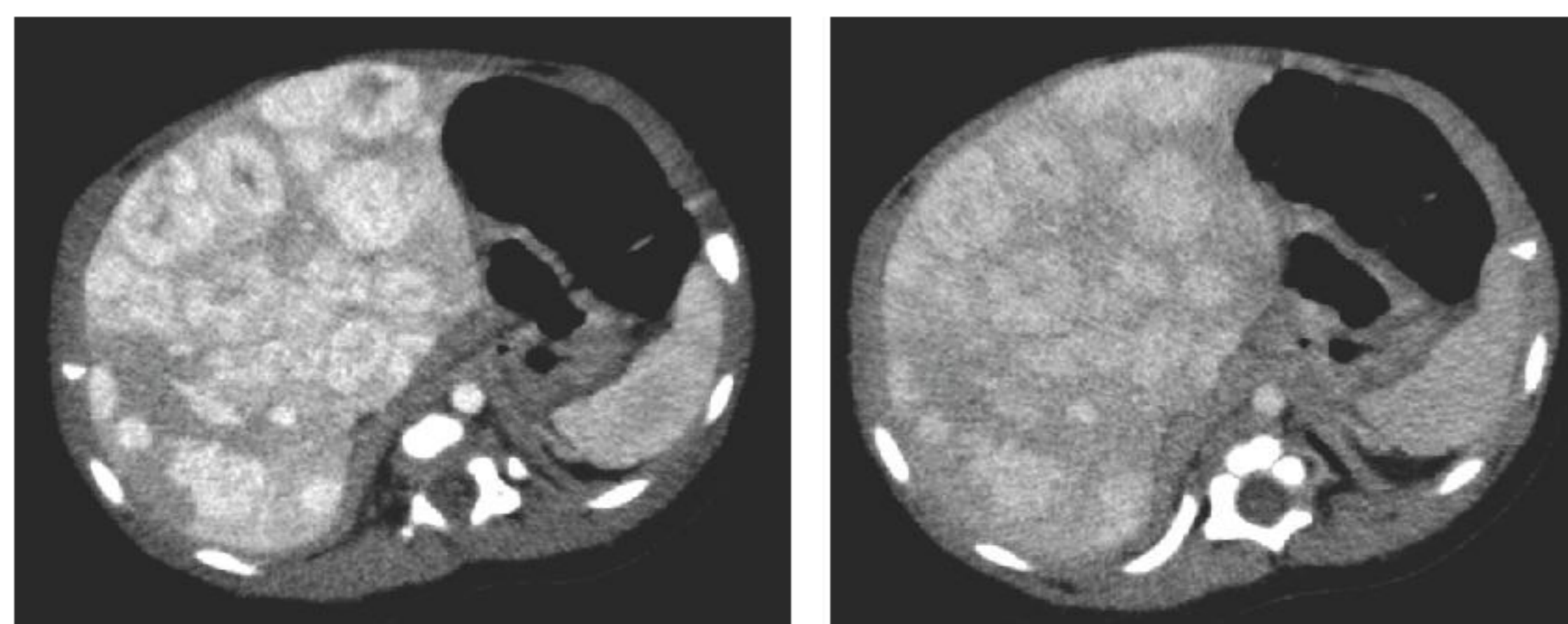
Height 56.5 cm (-0.6 SD)	Abdominal : liver was palpable 3cm below the right costal margin
Body Weight 6.29 kg (+1.1 SD)	no neurological abnormalities
Conjunctiva: icteric	no other hypothyroid symptoms
Thyroid gland: not palpable	

<Blood test>

TSH 17.7 μ U/ml	T-Bil 6.4 mg/dl	<Roche ratio> 0.21
free T3 1.96 pg/ml	D-Bil 0.2 mg/dl	
free T4 1.48 ng/dl	Tg 653 ng/ml	

<abdominal CT>

multifocal hepatic hemangiomas were enhanced in arterial phase and equilibrium phase.



arterial phase

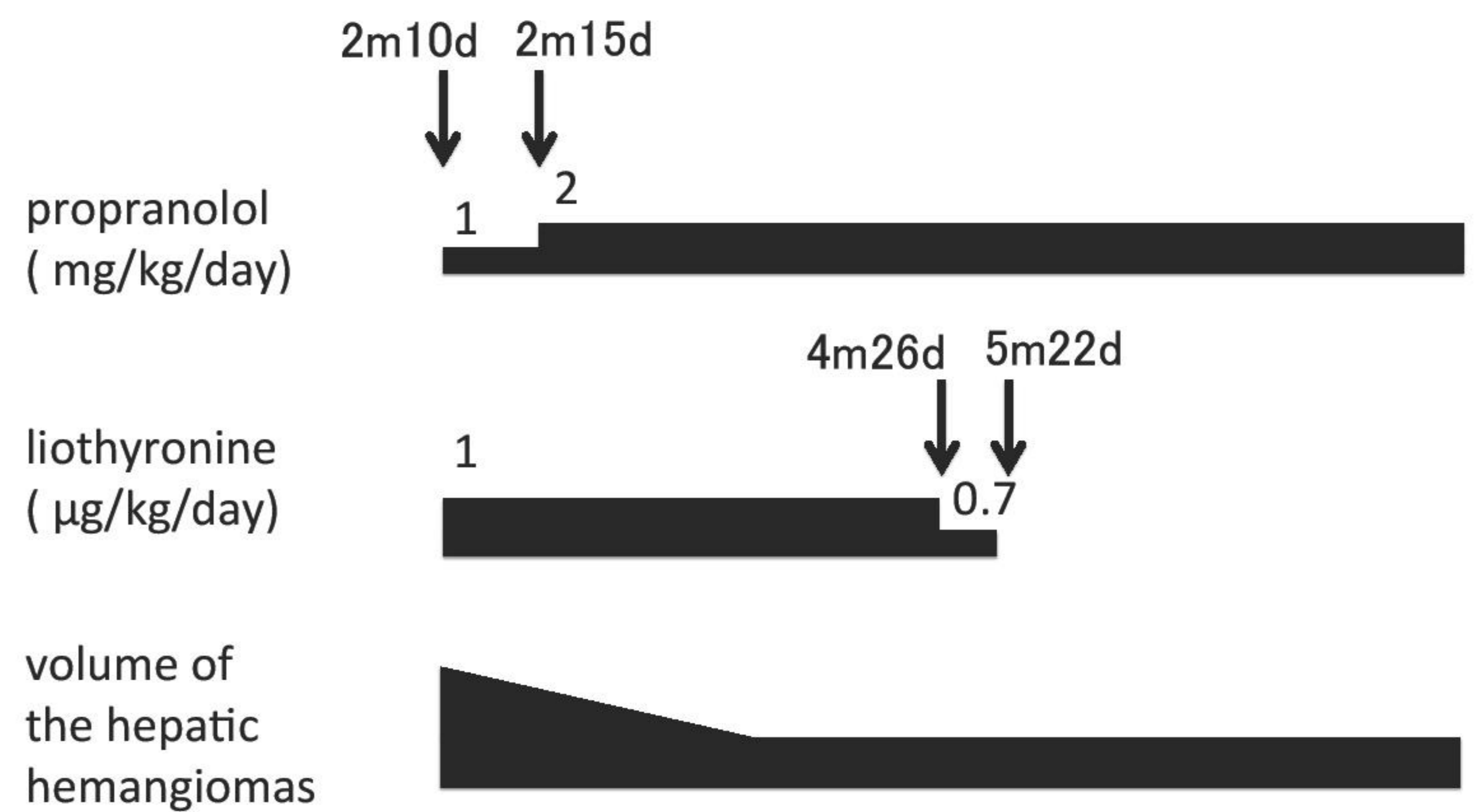
equilibrium phase

➤ We diagnosed him as having hypothyroidism due to multifocal hepatic hemangiomas.

2m15d: Propranolol(2 mg/kg/day) and Liothyronine(1 μ g/kg/day) were started because only fT3 was decreased.

5m22d: We stopped using liothyronine because fT3 and fT4 levels were maintained in the normal ranges.

11m8d: His growth and neurological development were normal for age and he was euthyroid



	5d	2m10d	2m22d	3m4d	4m5d	5m22d	6m12d	8m13d	11m8d
freeT3 (pg/ml)		1.96	4.36	4.95	4.52	3.91	4.29	4.41	4.6
freeT4 (ng/dl)	2.19	1.48	1.26	0.98	0.86	1.04	1.13	1.12	1.23
TSH (μ IU/ml)	5.9	17.73	8.384	1.956	2.571	0.98	1.789	1.436	1.515
T-Bil (mg/dl)		6.4	3.2	1.3	0.7	0.5	0.6	0.6	0.6
D-Bil (mg/dl)		0.2							

Discussion

- It took one month for this patient to have thyroid hormone levels in the normal ranges. The period for this improvement is shorter than most of the reported ones. The thyroid hormone requirement was gradually reduced and the treatment was discontinued at the age of 5 months.
- Propranolol is supposed to cause involution of multifocal hepatic hemangiomas, which leads to the early normalization of thyroid hormones. This is true in this patient.
- Administration of liothyronine alone can be useful in some patients with hypothyroidism caused by multifocal hepatic hemangiomas, especially when their fT3 level is low, compared to fT4 level. Administration of levothyroxine alone in consumptive hypothyroidism is reported to be difficult.

Conclusion

Administration of liothyronine alone can be useful in some patients with hypothyroidism caused by infantile hepatic hemangiomas, especially when their fT3 level is low, compared to fT4 level.

References

- 1) Semra Cetinkaya, et al. J Clin Res Ped Endo 2(3): 126-130, 2010
- 2) Stephen Huang, et al. NEJM 343(3): 185-189, 2000
- 3) Mhanna Amal, et al. Pediatr Dermatol 28(1): 39-45, 2011
- 4) Vergine Gianluca, et al. Horm Res Paediatr 78(4): 256-260, 2012
- 5) Hiroyuki Ikeda, et al. J Jpn Pediatr Soc 117(8): 1308-1312, 2013

Disclosure Statement

We have declared no conflicts of interest.

Contact

Shinji Higuchi, E-mail: shinji_higuchi@tmhp.jp