

Massive pericardial effusion and short stature caused by autoimmune hypothyroidism in 9-yr old dyspneic girl

Yun hee Gyon¹⁾, MD, Jae-Hong Yu²⁾, MD, Heon-Seok Han,¹⁾ MD,

Department of Pediatric, College of Medicine,
Chungbuk National University, Cheongju, Korea¹⁾
Joy Children's hospital, Daejeon, Korea²⁾

INTRODUCTION

• Massive pericardial effusion is uncommon in acquired hypothyroidism in children. As cardiac tamponade is life-threatening, prompt diagnosis and drainage should be performed. The most common and prominent manifestation of chronic acquired hypothyroidism in children is profound growth failure. Thyroxine supplementation improves all the clinical signs and symptoms except for growth failure. Accelerated growth often does not result in restoration of full growth potential, due to the rapid increase in skeletal age during treatment.

CASE REPORT

- A 9-yr-11-mo-old girl was brought to the ER with sudden dyspnea . She showed a weight increase of 10 kg over 1 year without specific symptoms. Hypercholesterolemia was recently found in the school health exam.
- She looked short but chubby, with a height of 120 cm (–2.61 SDS), weight 30 kg (25th percentile), and BMI 20.8 kg/m² (90th – 95th percentile), respiratory rate, 22 /min; pulse rate, 65 /min; and BP, 105/57 mmHg. SaO₂ 100% in room air. Her midparental height was 161cm (0.05 SDS). She was prepubertal without goiter. Heart sounds were soft and, distant without murmur.
- Total cholesterol: 526 mg/dL, LDL 476 mg/dL,
- SGOT/SGPT 117/126 IU/L, and CPK was 851 IU/L (normal, <167 IU/L).

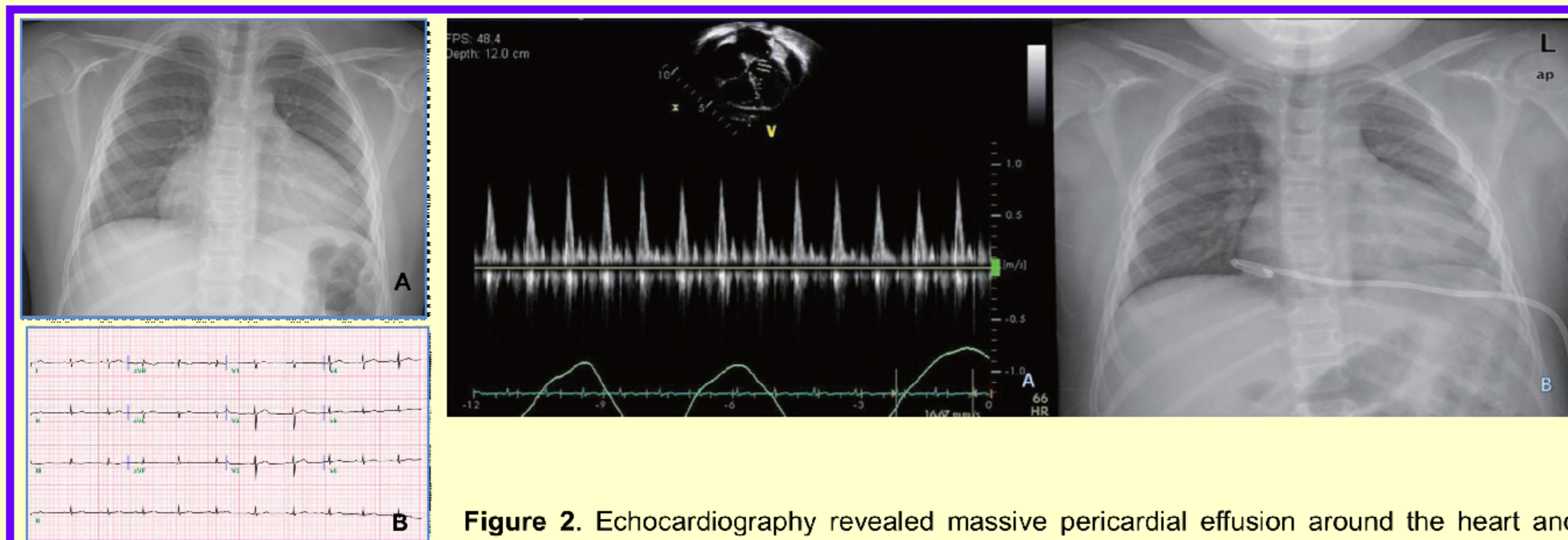


Figure 1. Chest X-ray showed water-bottle shaped cardiomegaly (A), and low-voltage in EKG (B).

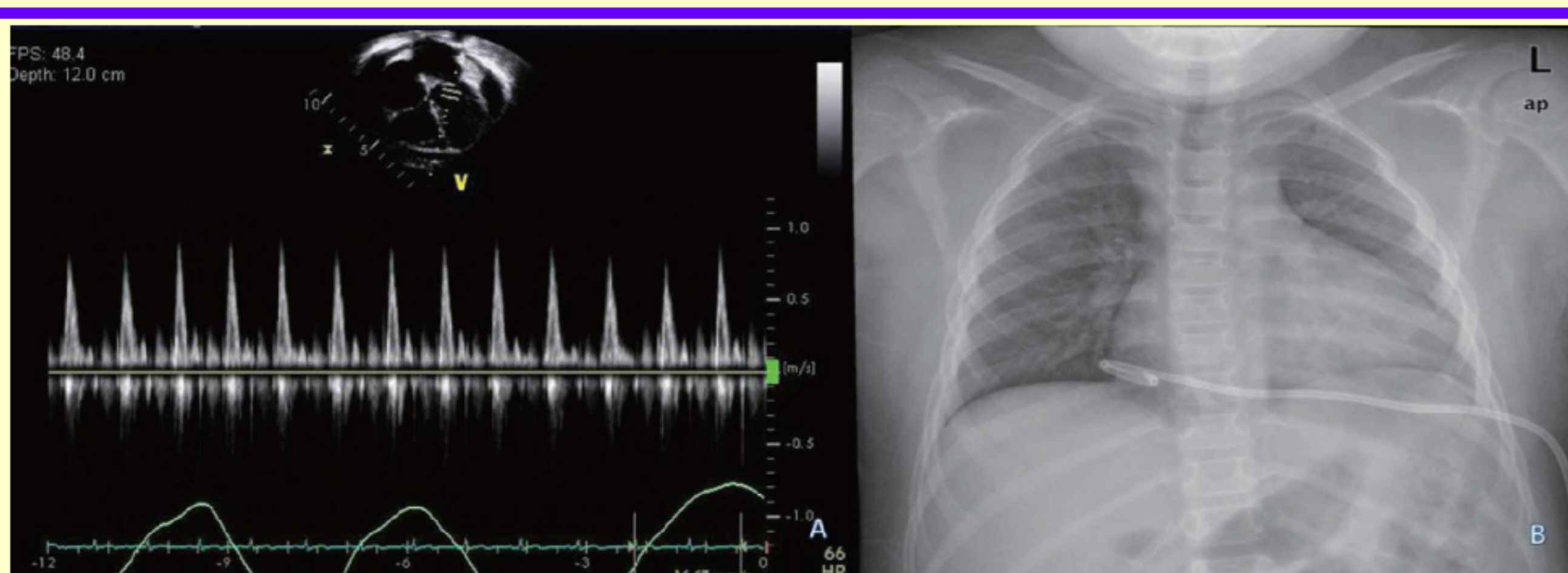


Figure 2. Echocardiography revealed massive pericardial effusion around the heart and fluctuating mitral inflow pattern recorded according to respiration (A), and closed pericardiostomy was performed with pericardial catheter (B).

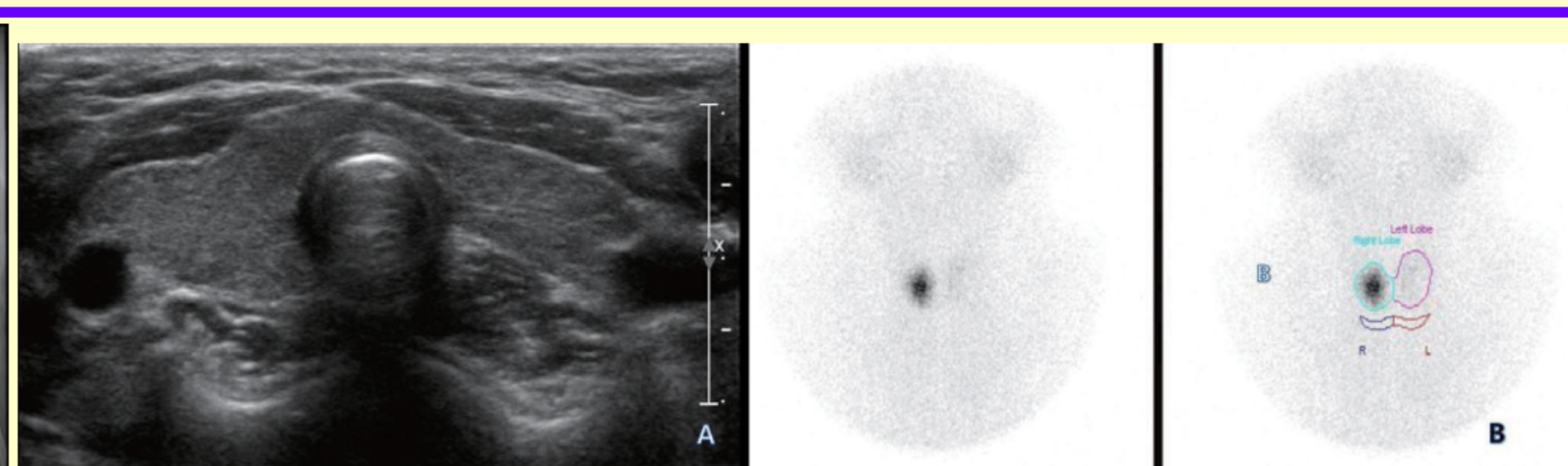


Figure 3. Thyroid ultrasonography showed mild heterogeneous echogenicity without intrathyroid nodule and lymph node enlargement (A), and thyroid 99mTc scintigram showed focal increase of radio-uptake in right lobe and nearly non-visualization of left lobe (B).

COURSE AND FOLLOW-UP

- Pericardiostomy (Fig. 2B) showed 500 ml straw-colored effusion with LDH 416 IU/L, glucose 79 mg/dL, protein 5.6 g/dL, WBC 80/ μ L (mononuclear cell 90%), Gram staining and culture for bacteria (-), AFB (-), viral test (-)
- TFT : free T₄ 0.27 ng/dL, T₃ 56.9 ng/dL, TSH>50 μ U/mL, anti-Tg Ab 154 IU/mL, TPO Ab 282 IU/mL, and TSH-R-Ab >40 U/L, Bone age was delayed at 9.0 years (CA=9.11 yr), IGF-1 63.6 ng/mL(64–345 ng/mL), IGFBP-3 1,545 ng/mL (1,800–7,100 ng/mL),
- T₄ was replaced with 0.1 mg daily without recurrence of pericardial effusion. During the 1st yr of thyroxine therapy, height velocity was 11.1 cm/yr, the HSDS improved from –2.61 to –1.65, and serum IGF-1 and IGFBP-3 levels were increased to 579 ng/mL and 2,687 ng/mL respectively. However bone age progressed rapidly from 9.0 years to 10.5 years. At 11 years of age, she developed breast budding with a bone age of 10.5 years. During the next 6 months, height velocity was 7.86 cm/yr and HSDS increased only to –1.62, but bone age progressed rapidly to 11.5 years.
- GH was given at 0.7 IU/kg/wk for 6 mo, resulting in increased HSDS up to –1.10 at the end of the second year of treatment with a height velocity of 12.63 cm/yr (Fig. 4).

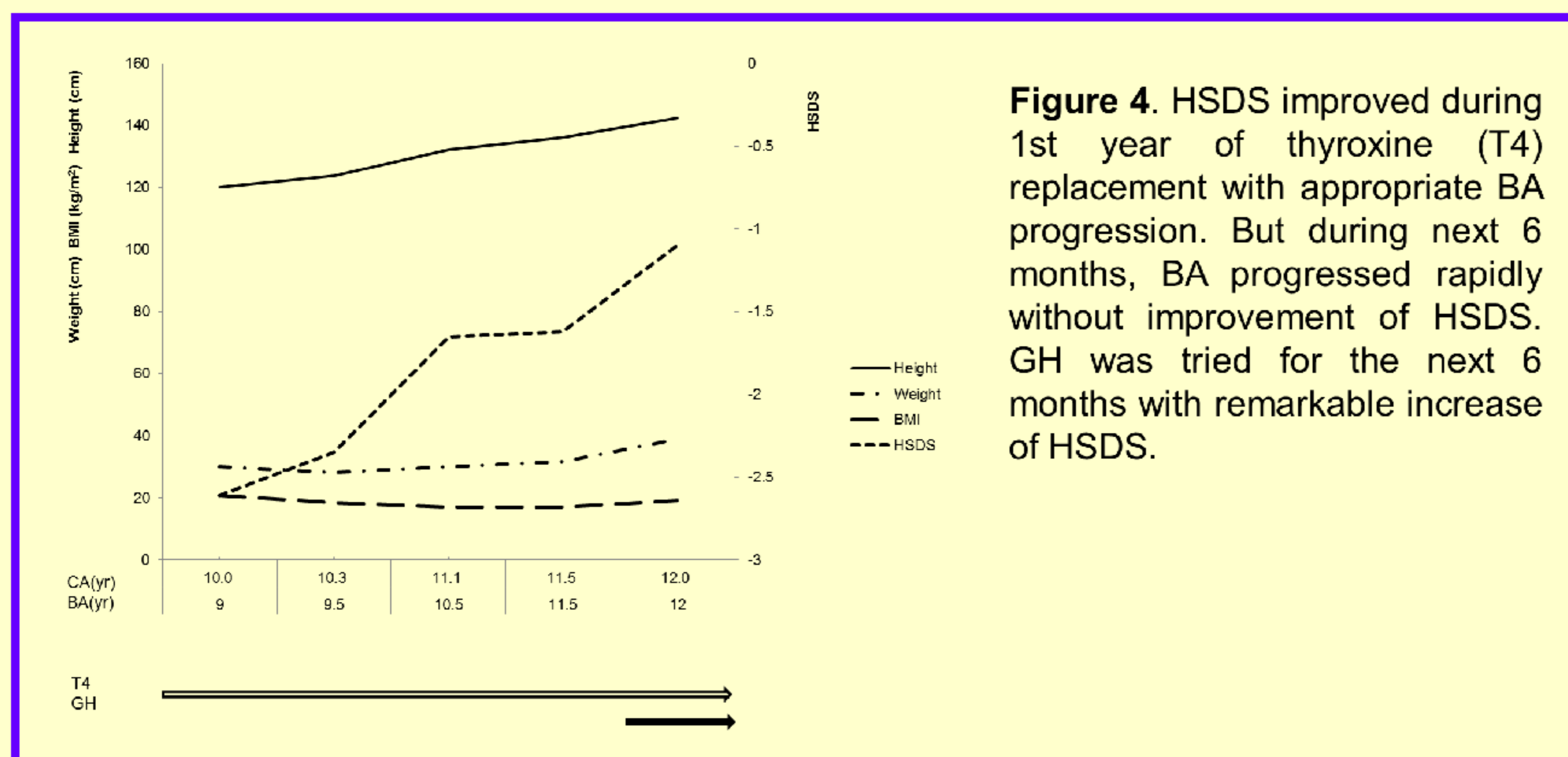


Figure 4. HSDS improved during 1st year of thyroxine (T₄) replacement with appropriate BA progression. But during next 6 months, BA progressed rapidly without improvement of HSDS. GH was tried for the next 6 months with remarkable increase of HSDS.

CONCLUSION

- In conclusion, primary hypothyroidism should be included in the etiologic evaluation of pericardial effusion, especially associated with relative bradycardia and short stature in children.
- Additional growth promoting therapy should be considered for incomplete catch-up growth in prolonged hypothyroidism during thyroxine supplementation.