

# Transient Hyperthyroidism Associated with a Thyroid Nodule

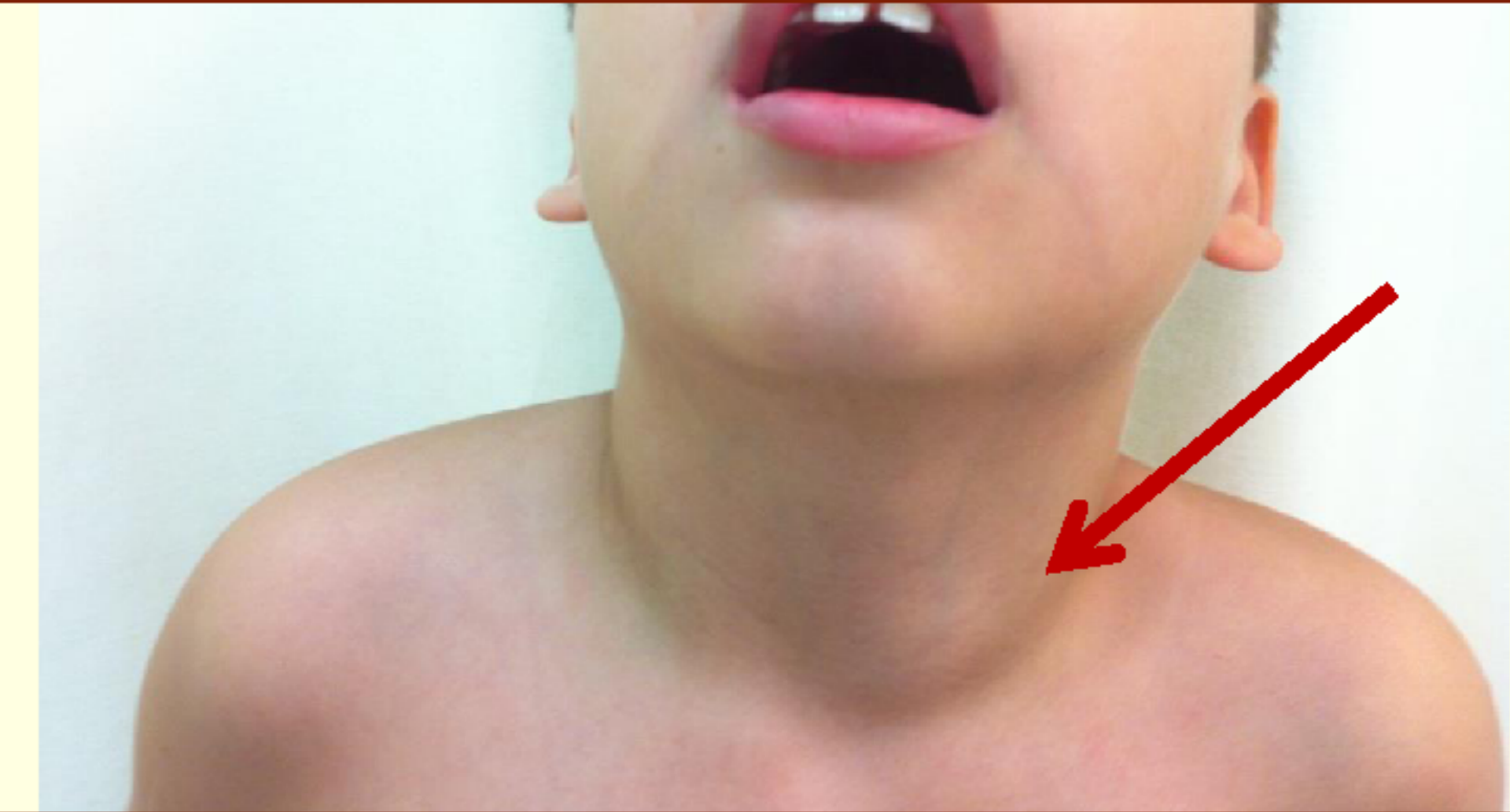Vargas A<sup>1</sup>, Yeste D<sup>1</sup>, Campos A<sup>1</sup>, Clemente M<sup>1</sup>, Garrido M<sup>2</sup>, Carrascosa A<sup>1</sup>

<sup>1</sup>Pediatric Endocrinology Department, Vall d'Hebron University Hospital, Barcelona

<sup>2</sup>Histopathology Department, Vall d'Hebron University Hospital, Barcelona

## Introduction

Developing an acute onset thyroid nodule is rare in children and usually associates with infectious or neoplastic disease; when linked to hyperthyroidism, the most likely diagnosis is toxic adenoma.

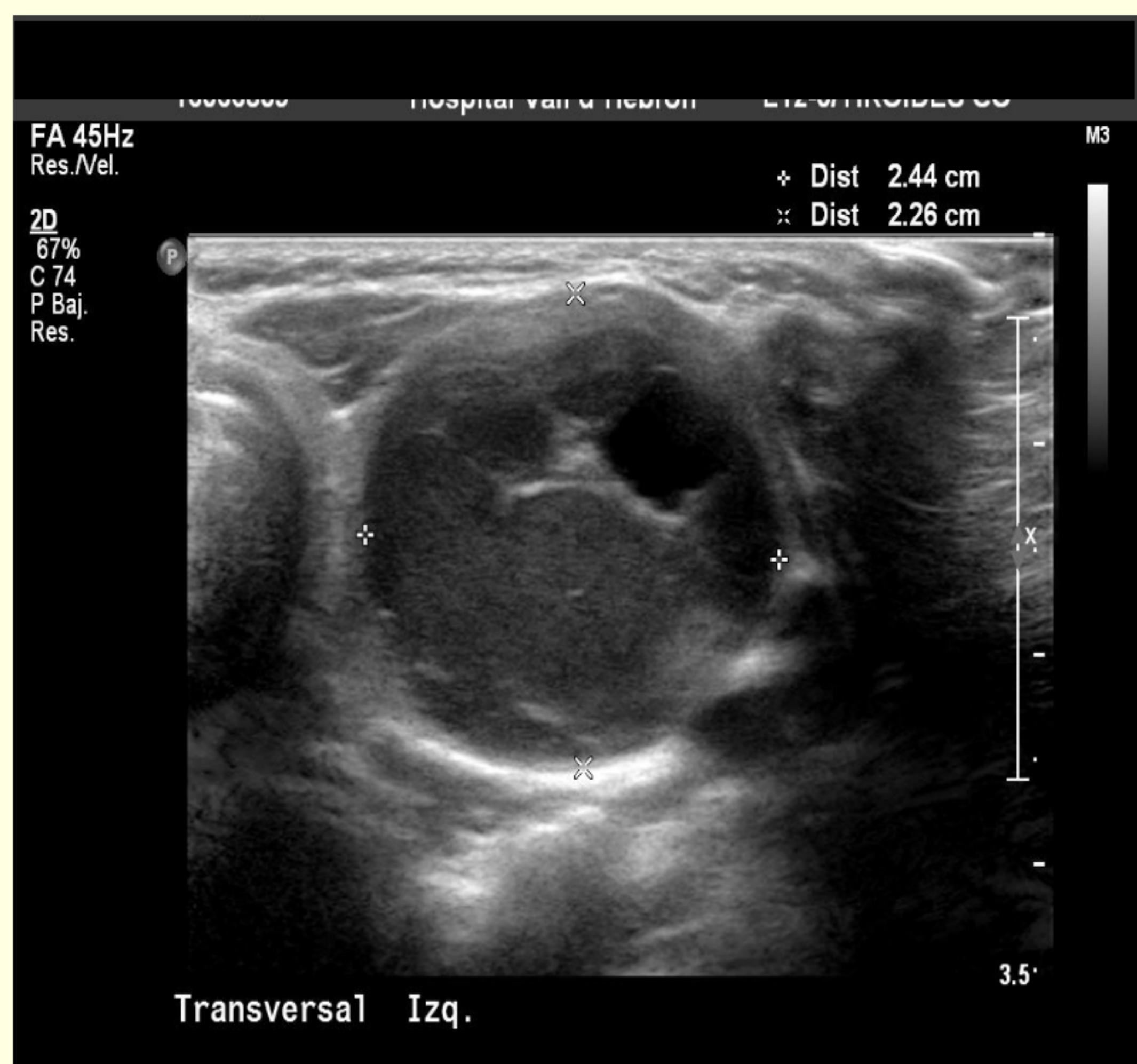


## Clinical Description

9-year-old boy with no relevant medical history was seen at the emergency department for acute cervical pain and tumor involving the left thyroid lobe with no inflammatory signs or history of trauma.

**Physical Examination:** No fever, normal BP and no exophthalmos. A nodule without clearly defined borders could be palpated. No lymphadenopathies were detected.

**Neck Ultrasound:** Well-defined heterogenic nodule measuring 3.3x2.5x2.4cm involving the left thyroid lobe, with no Doppler signal, and probable hematic content. Analgesic and antibiotic treatment was initiated owing a suspected spontaneous hemorrhage.



Over 72 hours, the patient developed nervousness, insomnia and palpitations with no evident change in the nodule's external appearance. HR: 90bpm, BP 110/70 (95p). Normal CBC and general biochemistry. Thyroid function: TSH 0.019mU/L (0.64-6.27), FT<sub>3</sub> 9.81pg/mL (2.3- 4.2), FT<sub>4</sub> 2.44ng/dL (0.8- 1.76), thyroglobulin: 3241pg/mL (0-55). Treatment was started with beta-blockers.

**Pertechnetate scintigraphy:** low thyroid uptake, almost abolished in the involved region.

**FNA:** scant non-diagnostic cellular material.

Thyroid function 15 days after presentation: TSH 0.016mU/L, FT<sub>3</sub> 4.82pg/mL, FT<sub>4</sub> 1.32ng/dL, thyroglobulin: 857pg/mL. Gradual reduction in US measured nodule size also showing contents changing from anechoic to hypoechoic, favoring a hematic nature. One month post-presentation thyroid function had normalized: TSH: 2.2mU/L, FT<sub>3</sub>: 3.51pg/mL, FT<sub>4</sub>: 0.95ng/dL, thyroglobulin: 90.1pg/mL. Owing a persistence of the nodule, a hemithyroidectomy was indicated.

**Histopathology:** hyperplastic residual nodule with widespread signs of previous hemorrhage.

	23/10/2014	30/10/2014	07/11/2014
TSH mU/L (0.64-6.27)	0.019 ↓↓↓	0.016 ↓↓↓	2.23
T3L pg/mL (2.3-4.2)	9.81 ↑↑↑	4.82 ↑	3.51
T4L ng/dL (0.8-1.76)	2.44 ↑	1.32	0.95
Thyroglobuline ng/mL (0-55)	3241 ↑↑↑	857 ↑↑	90.1 ↑

## Comments

Although transient hyperthyroidism is very rare in children, it has been described in early stages of Hashimoto's thyroiditis and in intoxications with exogenous thyroid hormones. The release of thyroid hormones due to spontaneous hemorrhage appears to have caused the transient hyperthyroidism in our patient.