

7 month-old male infant with spontaneous transient Graves' thyrotoxicosis.

Shuichi Yatsuga, Takako Sasaki, Kikumi Ushijima, Junko Nishioka, and Yasutoshi Koga
Department of Pediatrics and Child Health, Kurume University School of Medicine, Japan

Nothing to declare

1. Introduction

Graves' disease (GD) is the most prevalent autoimmune disorder in adults. The annual incidence in adult women is approximately 0.5 in 1,000, and in adult men one tenth, which is as common as in women. GD is rare in children, with an annual incidence of 0.8 in 100,000, and with six times more common in girls, thus, GD in boys is very rare. An annual incidence of GD under 10 year-old is extremely rare. Spontaneous transient thyrotoxicosis with pregnancy occasionally happens in 2% to 3% of all pregnant women. On the other hand, five adult cases of spontaneous transient Graves' thyrotoxicosis without pregnancy were reported¹.

2. Male infant case

41w0d, 3344 g, 47.4 cm, Normal delivery
3M Hyperhidrosis, diarrhea
5M Diarrhea
7M Difficulty in sitting position
--> Suspected with mild Developmental delay
--> Referred to child neurologist

3. 7M findings at child neurologist

Mild developmental delay

Height: 62.8 cm (-2.1 SD)

Body weight: 6.105 kg (-2.1 SD)

TSH < 0.01 μ U/mL, FT4 2.14 ng/mL

--> Referred to our hospital

4. 8M findings at our hospital

Height: 64.0 cm (-2.7 SD)

Body weight: 6.085 kg (-2.5 SD)

Heart rate: 140 bpm (at sleeping)

Blood pressure: 87/59 mmHg

ECG: normal

No goiter

T-cho 112 mg/dL

CRP < 0.04 mg/dL

ESR (60) 6.0 mm

TSH < 0.005 μ U/mL

FT4 1.60 ng/mL

Tg 73.6 ng/mL (< 32.7)

TRAb 2.2 IU/L (< 2.0)

TSAb (-)

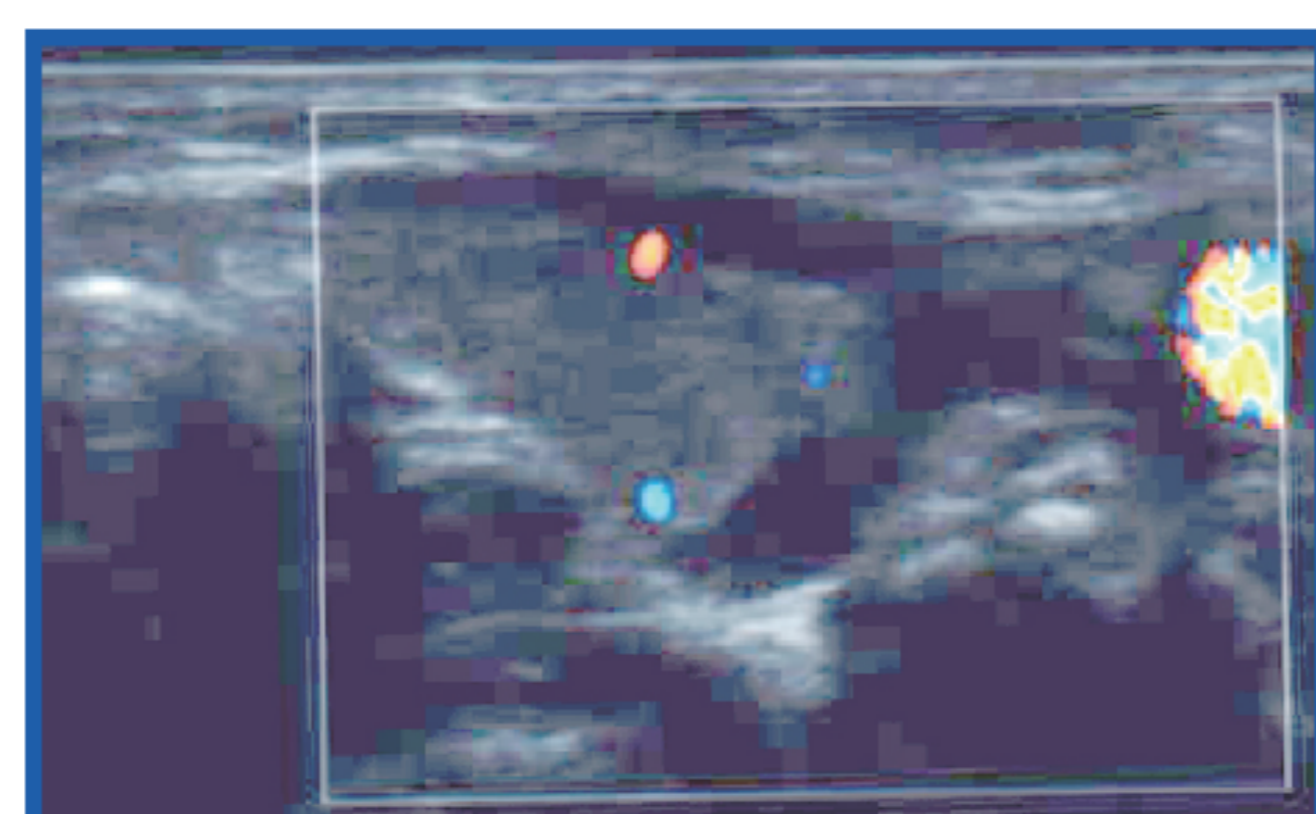
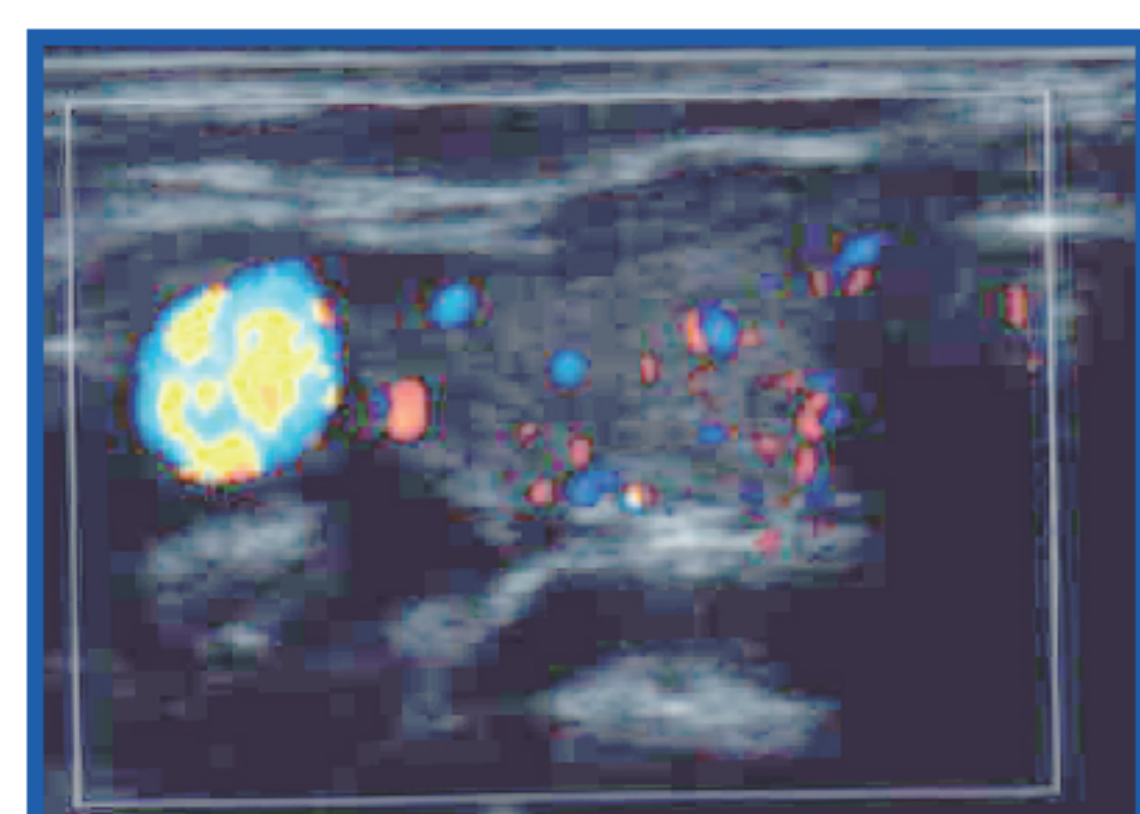
TgAb (-)

TPOAb (-)

5. thyroid ultrasonic echo

Right lobe
8.7x3.9 mm

Left lobe
9.2x6.7 mm



No enlarged thyroid

No increasing blood flow in thyroid

6. Tc scintigraphy



Tc uptake 2.7 %

(Right: 1.3 %, Left: 1.4 %)

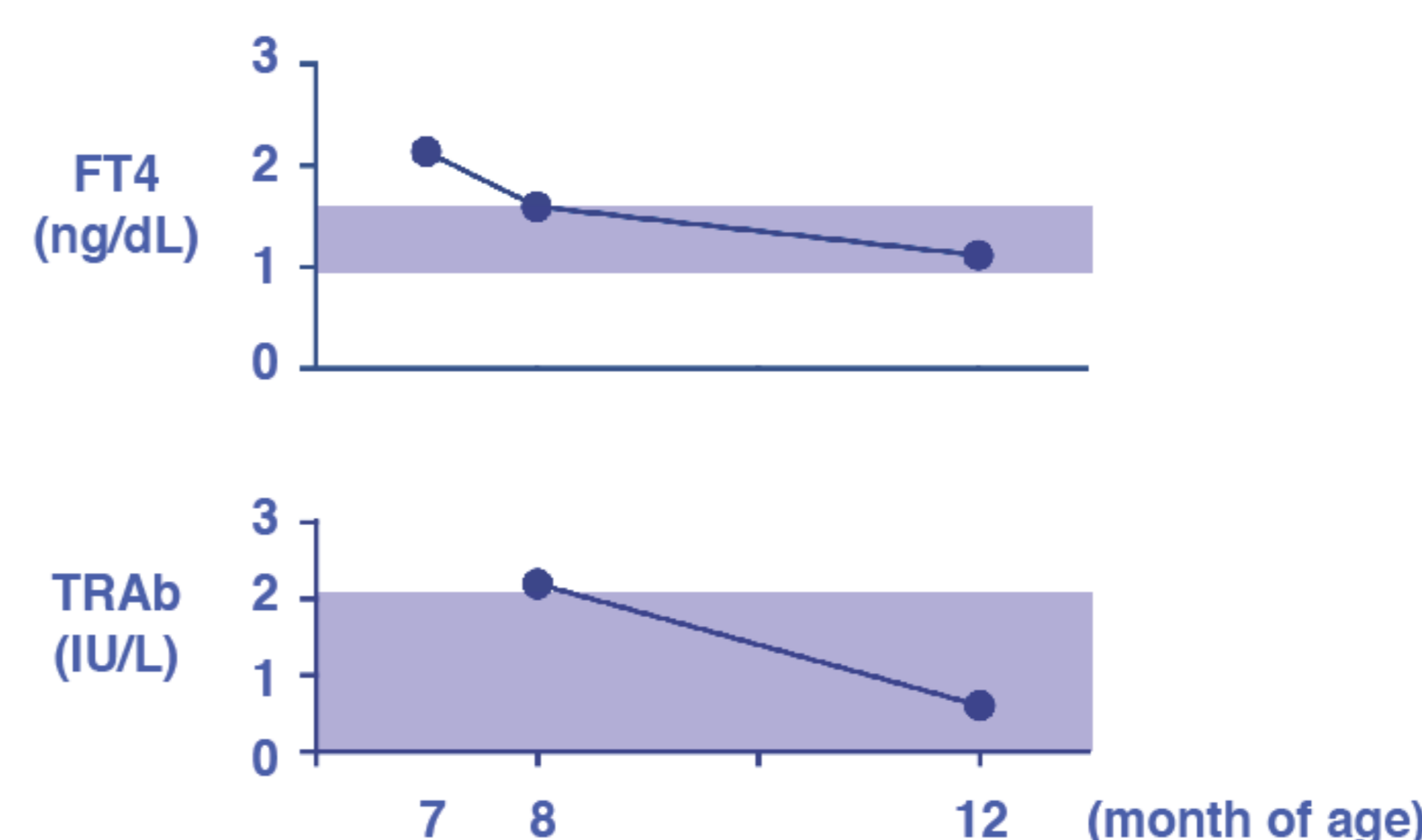
--> Normal range?

No nodules

No laterality

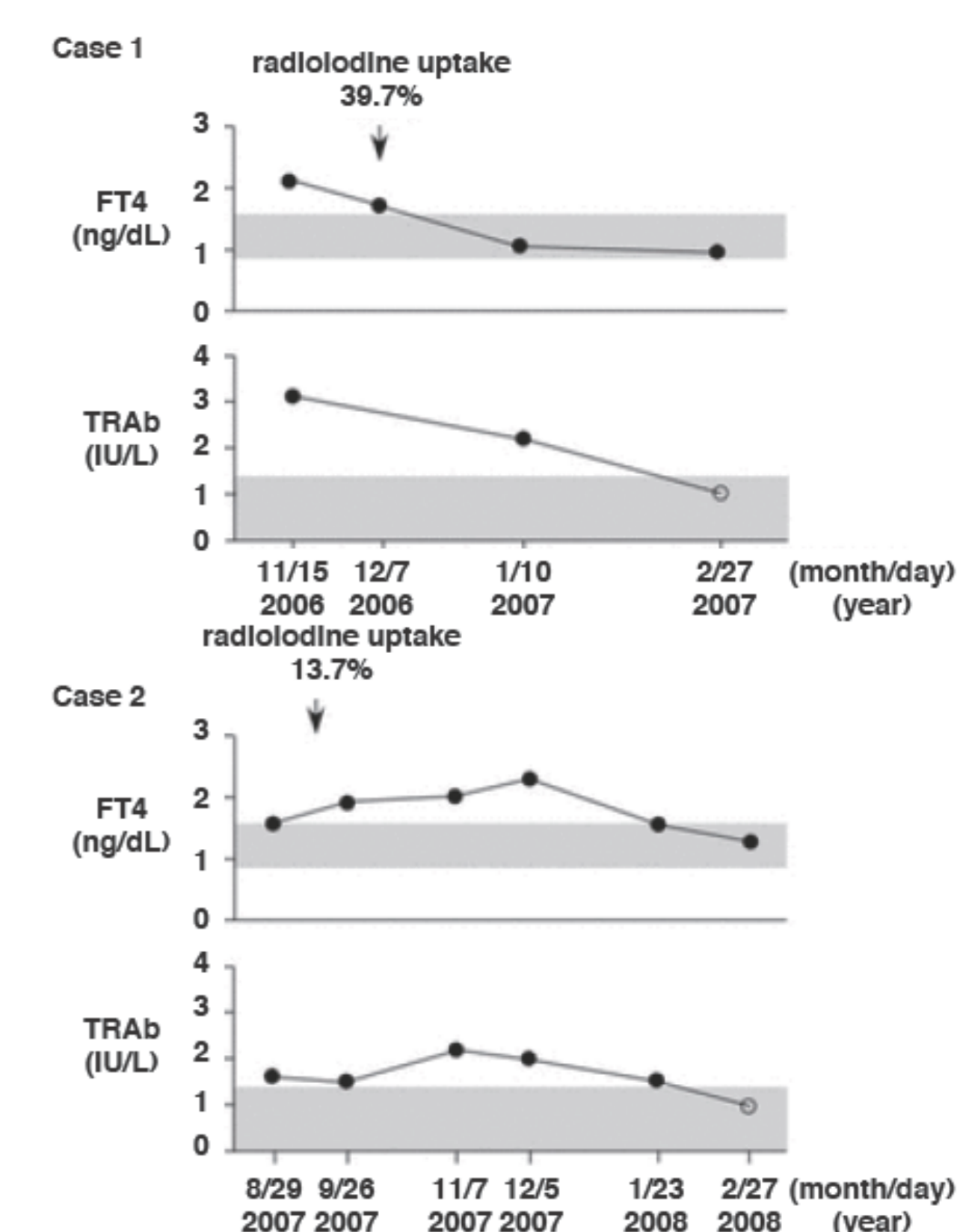
7. Thyroid hormone data

	7M	8M	12M
TSH (μ U/mL)	< 0.01	< 0.005	2.39
FT4 (ng/mL)	2.14	1.60	1.12
FT3 (pg/mL)		5.2	3.8
Tg (ng/mL)		73.6	23.2
TRAb (IU/L)		2.2	0.6



8. Spontaneous transient Graves' thyrotoxicosis

Hidaka Y, and Tatsumi K reported two cases that described clinical course with lab data¹. They had no history of thyroid disease. Their thyroid uptake of ¹²³I were high level, and their thyroid functions improved and become euthyroid without medication. Case 2 was diagnosed with a very mild case of Graves' disease.



9. Discussion

In this case, silent thyroiditis must be ruled out, however, it is very difficult to differentiate between very mild Graves' disease and silent thyroiditis. Failure to thrive, mild developmental delay, and tachycardia are most likely symptoms of hypertoxicosis. Uptake of Tc was not high level, but uptake of Tc was slightly higher compared with salivary gland. Our case was differed from previous reports, in which there were no symptoms. We believe that was spontaneous transient Graves' disease with symptoms. Although there are very few reports, it may be that there are more subclinical cases in reality. Follow up without medication is possible for our case, however, this case presents an interesting question of when to start treatment in similar situations.

References

1. Hidaka Y, and Tatsumi KI. Spontaneous transient Graves' thyrotoxicosis. Thyroid. 2008.

