

Turner Syndrome with Breast Development : Case report

¹Sung Won Park, ²Sung Yoon Cho, ²Jinsup Kim, ²Rimm - Huh, ³Su Jin Kim, and ²Dong-Kyu Jin

¹Department of Pediatrics, Cheil General Hospital, Dankook University School of Medicine, Seoul, Korea
²Department of Pediatrics, Samsung Medical Center, Sungkyunkwan University School of Medicine, Seoul, Korea
³Department of Pediatrics, Myongji Hospital, Goyang, Korea

Introduction

➤ Turner Syndrome (TS) is caused by monosomy or structural abnormalities of the X chromosome, with a prevalence of out 1/2500 females live birth. Most important clinical features of TS are short stature and gonadal failure. Approximately one third of girls with TS may undergo spontaneous puberty. One case of a variant Turner syndrome with breast development was presented.

Case Presentation

9-years old girl was referred to our pediatric endocrinology outpatient clinic with complaints of short stature and breast budding.

She was born at 35+2wks with a birth weight of 1930g (10th percentile) and a length of 41.5 cm (10th percentile). There was no family history of genetic or congenital disorders. On personal past history, the patient had been treated as transient tachypnea of newborn at first day after birth. And she was diagnosed as Kawasaki disease & Brown syndrome at 2012, March at other hospital and followed up echocardiogram every years.

Her height on referral was 122.4cm, which placed her in the 10th percentile on a Korean standard growth chart and at the 90th percentile on a TS growth chart; her weight was 30.5 kg (70th percentile). The mid-parental height was 164.5 cm (75th percentile). A physical examination revealed a Tanner stage III for breast development and Tanner stage I for pubic hair development, Her bone age was 11 years. Chromosome analysis revealed a **46,x,der(x)t(x;x)(p11.21;q11.2)**

The size and shape of the heart were normal on echocardiography and a kidney ultrasound was normal. Pelvic ultrasound can evaluate her prepubertal uterus, sized 40*5*9mm, but ovaries can't be evaluated due to poor visualization, so follow up evaluation must be considered.

Thyroid function tests of the patient was normal. A gonadotropin-releasing hormone (GnRH) agonist stimulation test is up to 4.8mIU/ml at 45min(Table1). A serum estradiol was under 5.0pg/ml, and serum levels of IGF-1 and IGFBP-3 were within normal limits(Table 2).

These findings were not consistent with precocious puberty but LH peak was nearly up to the level of precocious puberty. The patient has been treated with growth hormone. And it can be helpful for her growth and emotional support.

Table 1. GnRH agonist stimulation test

	LH level (mIU/mL)	FSH level (mIU/mL)
Base level	<0.1	8.5
30'	3.8	26.0
45'	4.8	37.8
60'	4.6	43.5
90'	4.0	49.9

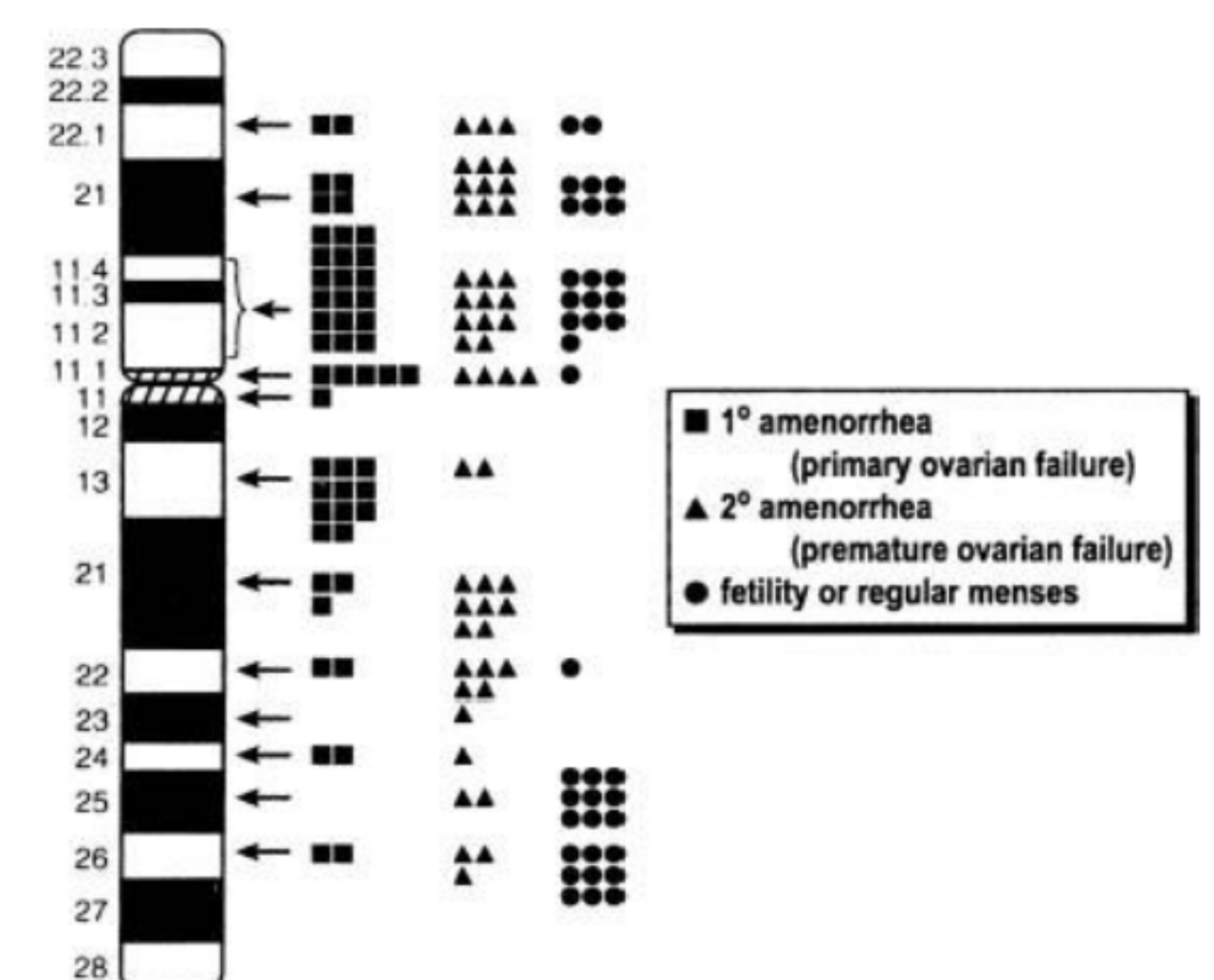
Table 2. IGF-1 & IGF-BP3

	Result
IGF-1	211.4
IGF-BP3	4190

Summary & Conclusion

It is believed that the proximal of the short arm of the X chromosome is more likely to be associated with ovarian function(Figure 1). So, 1/3 girls with TS may undergo spontaneous puberty, but precocious puberty is not common and there is only one case report in Korea, in 2012, in variant TS. Our case highlights the possibility of precocious puberty as an atypical clinical feature of TS. We will emphasis on careful assessment on unusual gonadal pattern in this case and we also concentrate concern on her growth chase as a normal woman.

Figure 1
Schematic diagram of the X chromosome



Reference

1. J. U. Baak, I. T. Hwang, et al.: Precocious puberty in Turner Syndrome. J Pediatr Adolesc Gynecol_2012_25(5)_e113-4
2. Pasquino AM, Passeri F, Pucarelli I, et al: Spontaneous pubertal development in Turner's syndrome. Italian Study Group for Turner's Syndrome. J Clin Endocrinol Metab 1997; 82:1810