

# Ligase IV deficiency syndrome as a cause of microcephalic primordial dwarfism in dizygotic twins

Céline M Girardin<sup>1</sup>, Emmanuelle Ranza<sup>3</sup>, Mirjam Dirlewanger<sup>1</sup>, Philippe Klee<sup>1</sup>, Marianne Caflisch<sup>2</sup>, Armand Bottani<sup>3</sup>, Valerie M Schwitzgebel<sup>1</sup>

<sup>1</sup>Pediatric Endocrinology and Diabetology, <sup>2</sup> Department of Pediatrics, <sup>3</sup>Department of Genetic Medicine, University Hospitals of Geneva, Switzerland.

Authors have no conflict of interest

## Introduction

Microcephalic primordial dwarfism (MPD) is a group of rare genetic disorders defined by severe restriction of both pre- and postnatal growth of weight (W), length (L), and particularly head circumference (HC).

**We report the genetic origin of MPD in dizygotic twins.**

## Method

Next generation exome sequencing, followed by targeted bioinformatics analysis of 19 genes known to be implicated in MPD, was performed in the affected boy. Familial segregation of the identified causative variants was done by Sanger sequencing.

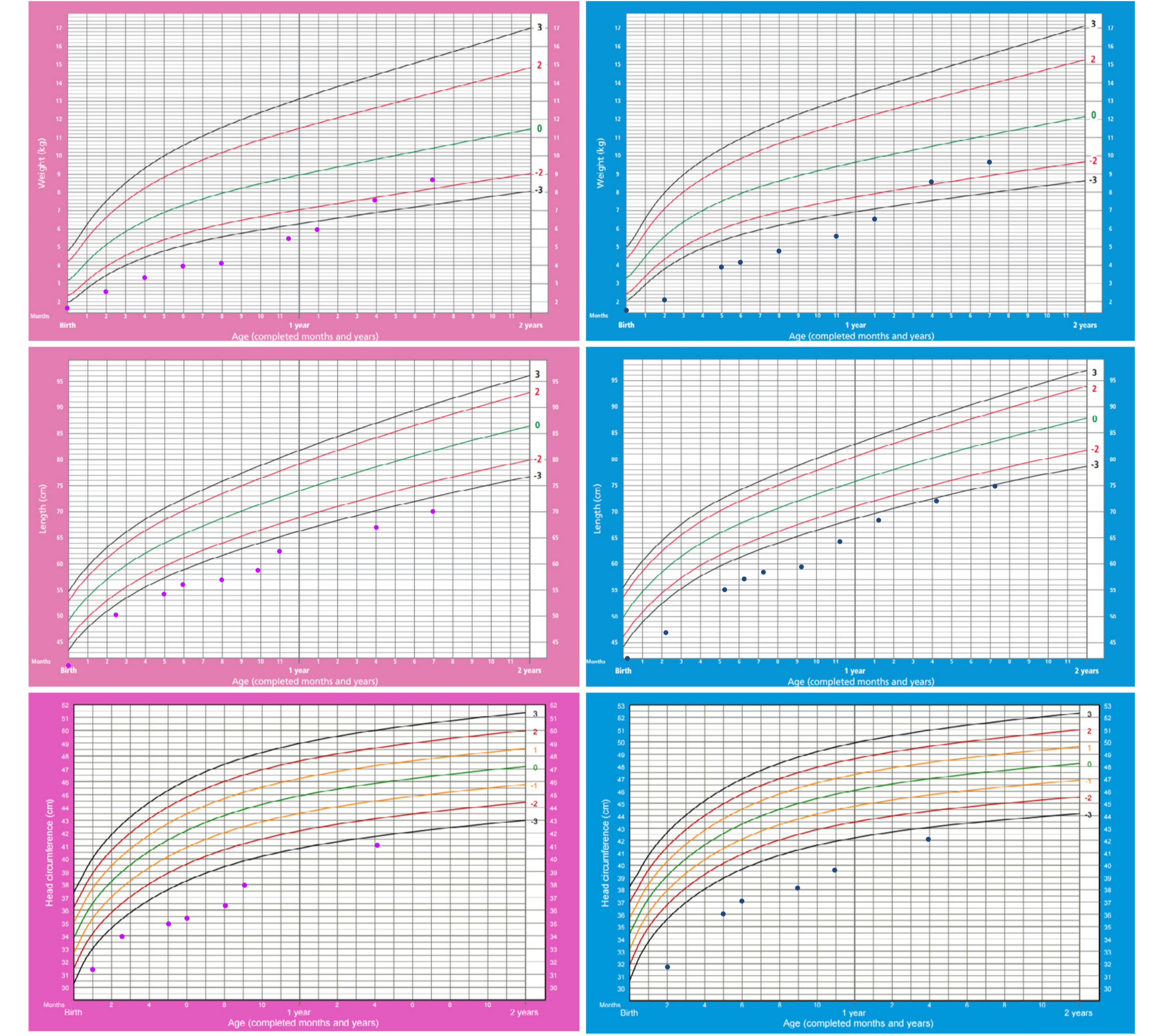
## Case report & Results

Dizygotic twins (a girl and a boy) were born from non-consanguineous healthy parents of normal height. Two older siblings of 4 and 2 years of age were healthy. **Harmonious intrauterine growth restriction** of both twins was noted starting in the 4<sup>th</sup> month of pregnancy and was confirmed at birth (Fig. 1).

Figure 1. Growth parameters at birth.

Birth 36 1/7	Boy	SD	Girl	SD
Weight (g)	1530	-3.1	1490	-3.1
Length (cm)	41.5	-3.2	40	-3.9
Head circumference (cm)	28	-3.7	26.7	-4.4

Figure 2. Weight, Length and Head circumference charts of both twins.



Both twins developed **feeding difficulties** and were hospitalized at the age of 5 months to investigate their **growth failure**. W, L and HC were well below -2SD (Fig. 2). Examination showed alert and non sick-looking babies with a similar round face, thin lips and a high-pitched voice. Penile length in the boy was 1 cm. Enteral nutrition through gastrostomy allowed weight gain and some statural catch-up growth (Fig 2).

Extensive work-up showed **hypogammaglobulinemia** and **neutropenia**. Gonadotropic axis exploration at mini-puberty in the boy showed slightly elevated FSH (7mU/l), normal LH and testosterone and slightly decreased AMH values (122pmol/l), potentially suggesting Sertoli cell insufficiency. Thyroid function tests, growth factors, brain MRI and skeletal x-rays were normal.

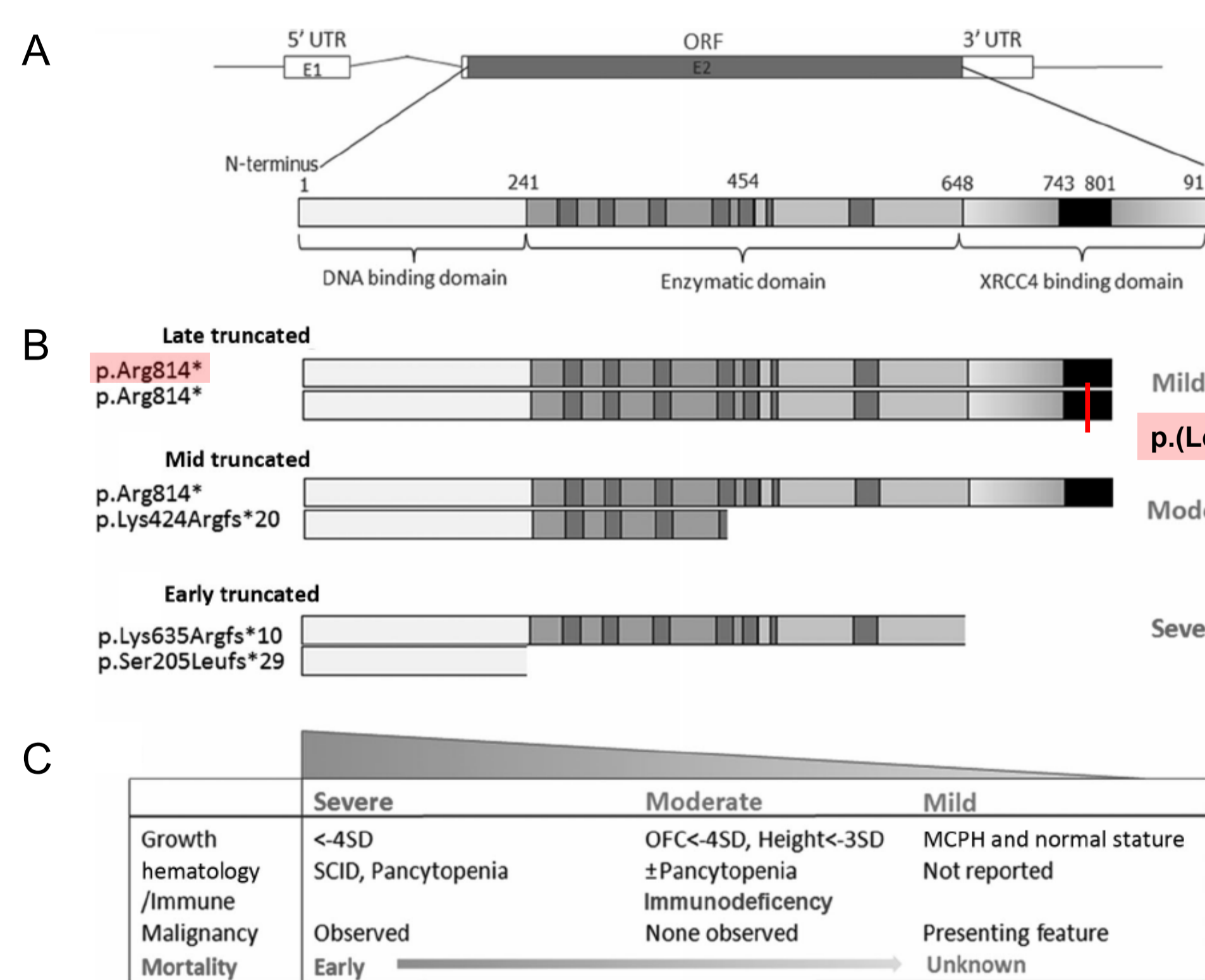
Genetic investigations revealed normal blood standard karyotype and array-CGH (180K). Exome sequencing of 19 candidate genes known to be implicated in MPD showed **compound heterozygous mutations of LIG4** (chromosome 13) in both twins (Fig.3B) :

- c.2321T>C, p.(Leu774Pro): previously undescribed "late" missense mutation.
- c.2440C>T, p.(Arg814\*): recurrent common "late" truncating mutation.

The parents were heterozygous carriers of one of the respective mutations.

## Discussion

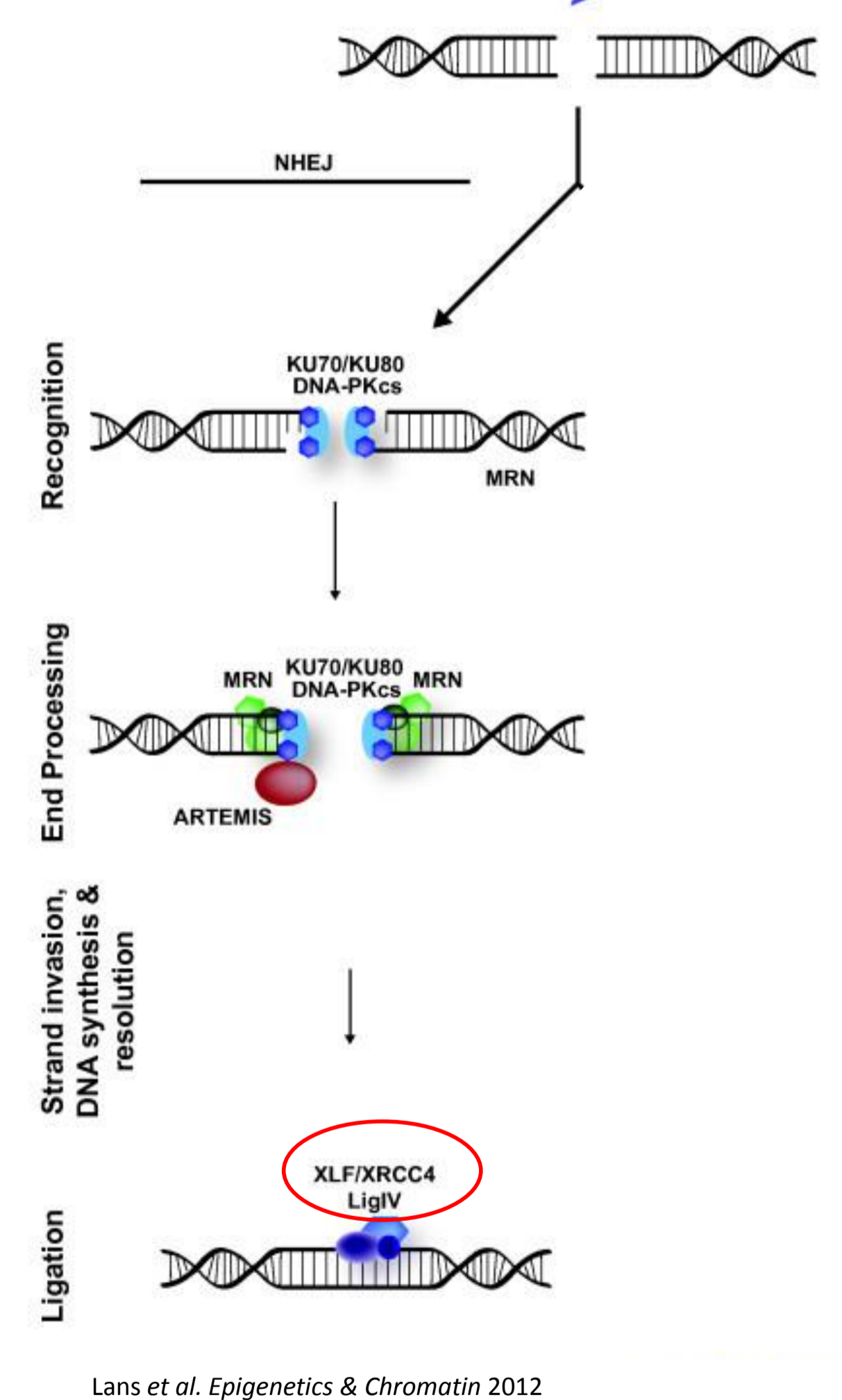
Figure 3. A: Schematic of the LIG4 gene. B: Position of the mutated loci. C: Genotype-phenotype correlation according to Murray et al, Human Mutation, 2013.



Ligase IV is an enzyme of the **nonhomologous end-joining (NHEJ) pathway** which is implicated in the repair of DNA double-strand breaks (Fig. 4). Complexing with XLF and XRCC4 proteins, it joins DNA ends. Both of the mutated loci are located in the XRCC4 binding domain (Fig. 3). Ligase IV is also implicated in the V(D)J recombination of T and B cells, leading to the highly diverse repertoire of immunoglobulins and T cell receptors.

To date, 28 cases of ligase IV deficiency have been reported. Major clinical features are: severe prenatal and postnatal growth restriction (W, L and HC), possible severe immunodeficiency, bone marrow failure and radiation hypersensitivity leading potentially to lympho-reticular malignancies. Other inconstant characteristics include feeding difficulties and hypergonadotropic hypogonadism which was reported in two girls who had reached age of puberty. Murray et al. established a genotype / phenotype correlation based on the combination and position of the causative mutations (Fig 3C).

Figure 4. DNA double-strand breaks repair : NHEJ pathway



## Conclusion

Ligase IV deficiency syndrome has to be considered in the differential diagnosis of patients with MPD, especially if associated with immune and hematological anomalies. The defect in the NHEJ DNA repair pathway is responsible for a constitutive hypersensitivity to ionizing radiations and a possible increased risk of cancer. Early diagnosis (and avoidance of non strictly indicated Xray imaging) is thus important, as it makes long-term follow-up mandatory.

### References:

- Murray et al, Extreme growth failure is a common presentation of ligase IV deficiency. Hum Mutat. 2014 Jan;35(1):76-85.
- Murray et al, Mutations in the NHEJ Component XRCC4 Cause primordial dwarfism, Am J of Hum Genet, 2015 Mar 5;96(3):412-24.
- Uspert et al, Clinical spectrum of LIG4 deficiency is broadened with severe dysmaturity, primordial dwarfism, and neurological abnormalities. Hum Mutat. 2013 Dec;34(12):1611-4.
- van der Burg et al, A new type of radiosensitive T-B-NK+ severe combined immunodeficiency caused by a LIG4 mutation. J Clin Invest. 2006 Jan;116(1):137-45.
- O'Driscoll et al, DNA ligase IV mutations identified in patients exhibiting developmental delay and immunodeficiency. Mol Cell. 2001 Dec;8(6):1175-85.

