

CUSHING SYNDROME DUE TO ADRENOCORTICAL CARCINOMA IN A 3 MONTH OLD INFANT WITH A LARGE INTERSTITIAL DELETION OF CHROMOSOME 5Q INCLUDING THE APC GENE

Halit Ilker Akkurt (1), Esther Schulz (1), Konrad Reinshagen (4), Jessika Johannsen (2), Inga Vater (3), Almuth Caliebe (3)

1. Department of Pediatrics, Altonaer Children's Hospital, Hamburg, Germany
2. Department of Paediatrics, Hamburg University Medical Centre, Hamburg, Germany
3. Institute of Human Genetics, Universitätsklinikum Schleswig-Holstein, Campus Kiel, Kiel, Germany
4. Department of Pediatric Surgery, Altonaer Children's Hospital, Hamburg, Germany

Background: Childhood adrenocortical tumors (ACT) are rare. Adenomas are the most common ACT, but adrenocortical carcinomas (ACC) occur as well. Childhood ACC may be part of the Li-Fraumeni Syndrome, Beckwith-Wiedemann Syndrome or familial cancer susceptibility syndromes caused by single gene mutations including P53, MEN1, PRKAR1A, CTNNB1 and APC (2). ACC may also occur in familial adenomatous polyposis coli (FAP) which is a colon cancer predisposition syndrome caused by germline inactivation of the adenomatous polyposis coli tumor-suppressor gene (APC) located on the long arm of chromosome 5 (5q21–5q22). The main feature of FAP is polyposis beginning in early adulthood. We report on an infant with a large deletion 5q who presented with an ACC at the age of 3 months.

Clinical case: (there is informed consent on showing clinical data and pictures):

- **3-month-old male infant, offspring from non-consanguineous german parents, presenting with obvious clinical signs of Cushing Syndrome**
- **Findings on admission:** truncal obesity, moon face, reddening of the cheeks with abnormally thin skin, poor spontaneous motor activity, no signs of abnormal virilisation, micropenis, cryptorchidism on the right side.



patient at age of 1 month

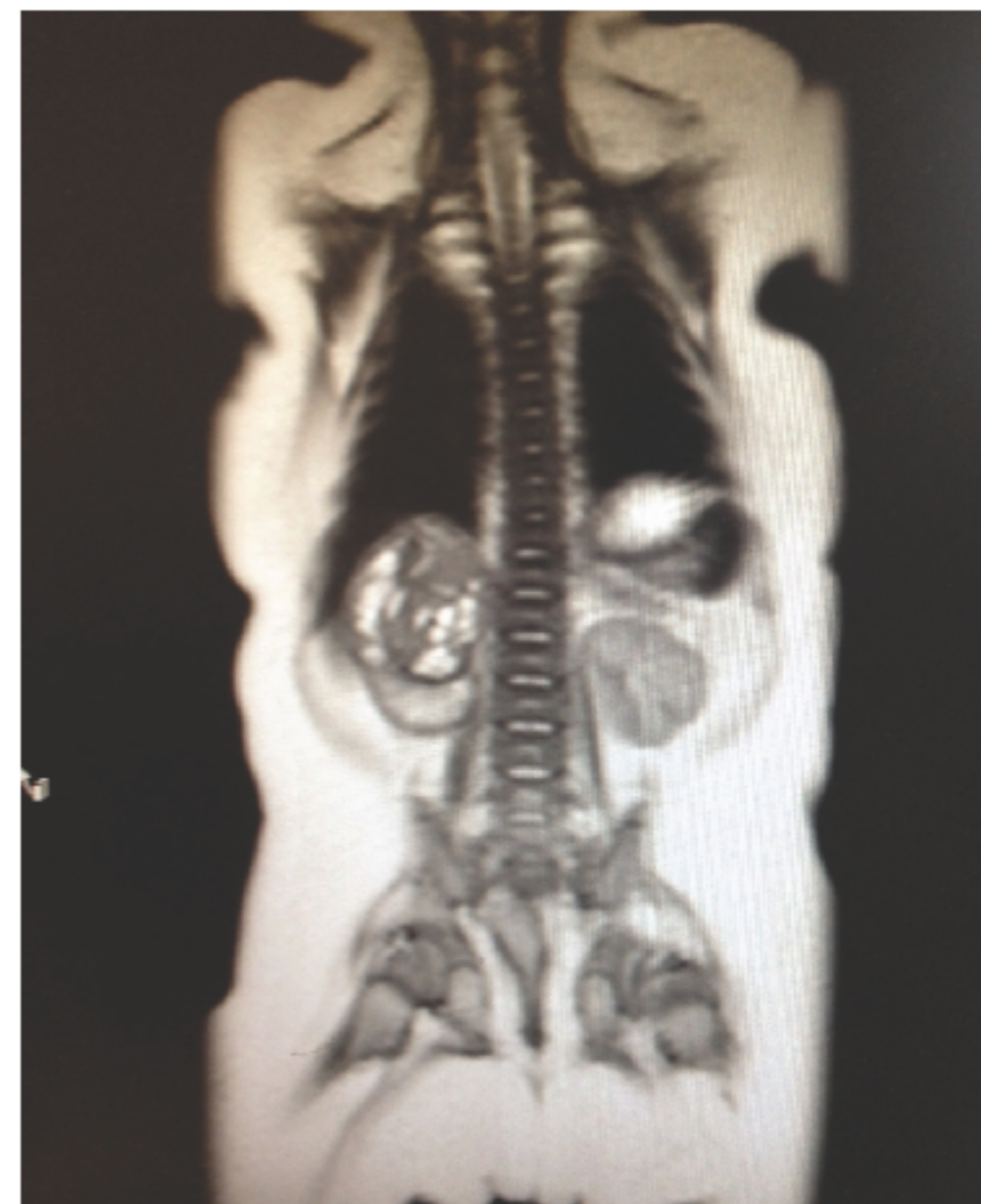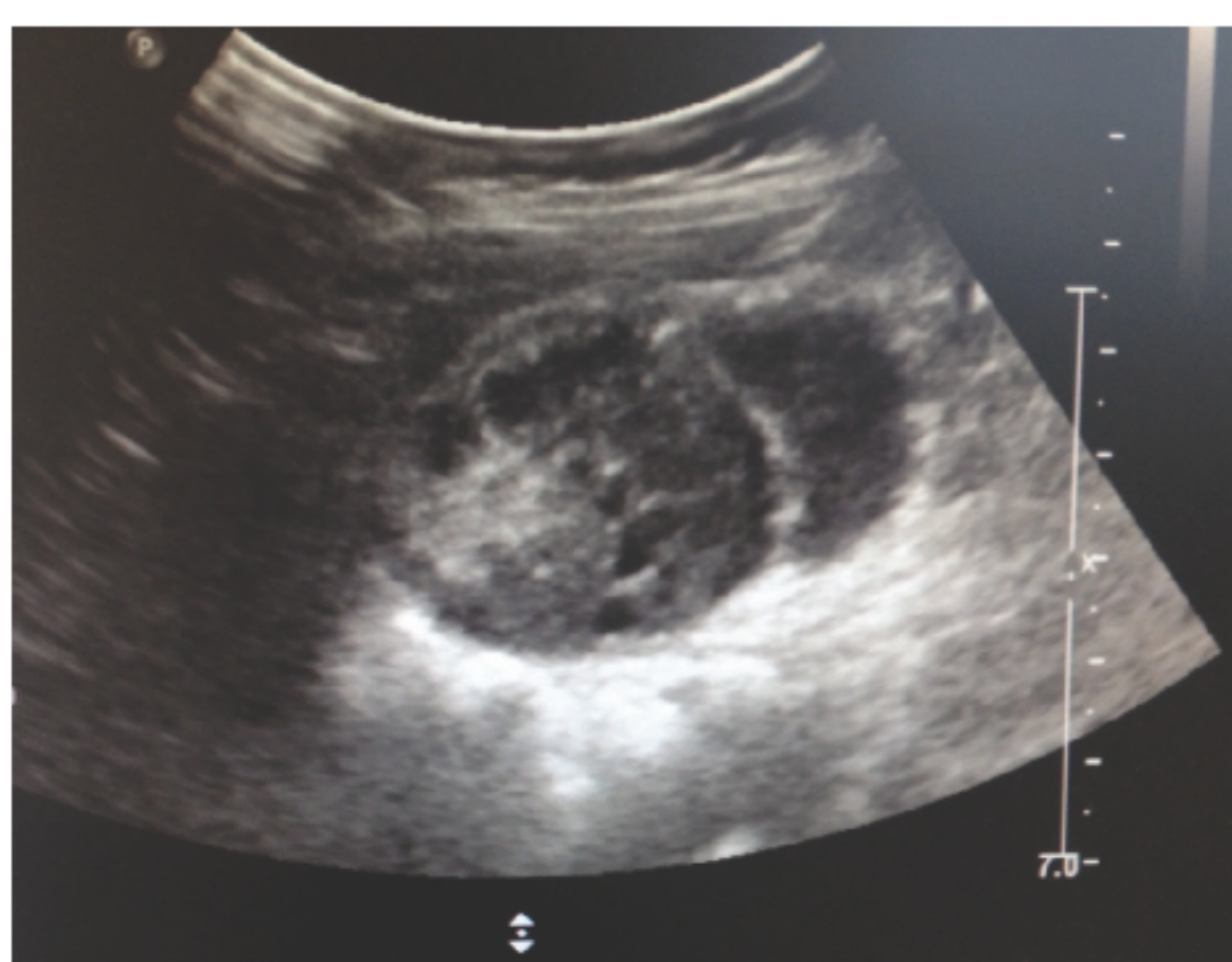


patient at age of 3 months

- **Former history:** uneventful pregnancy, uncomplicated birth at 42 weeks of gestational age (3670 g, 53 cm), postnatal diagnosis of clubfoot and cryptorchidism on the right side.
- **Auxology:** length: 56 cm (- 4 cm or - 2 SDS), growth rate over the last 3 months: 10,1 cm/year (- 31 cm/year or - 4.4 SDS) (data of Reinken et al.)
- **hormonal evaluation:** ACTH-independent hypercortisolism

Time	8 am	4 pm	24 pm
Cortisol ng/ml (43-224)	97	96	135
ACTH pg/ml (4,7-48,8)	3.3	1,9	4,1

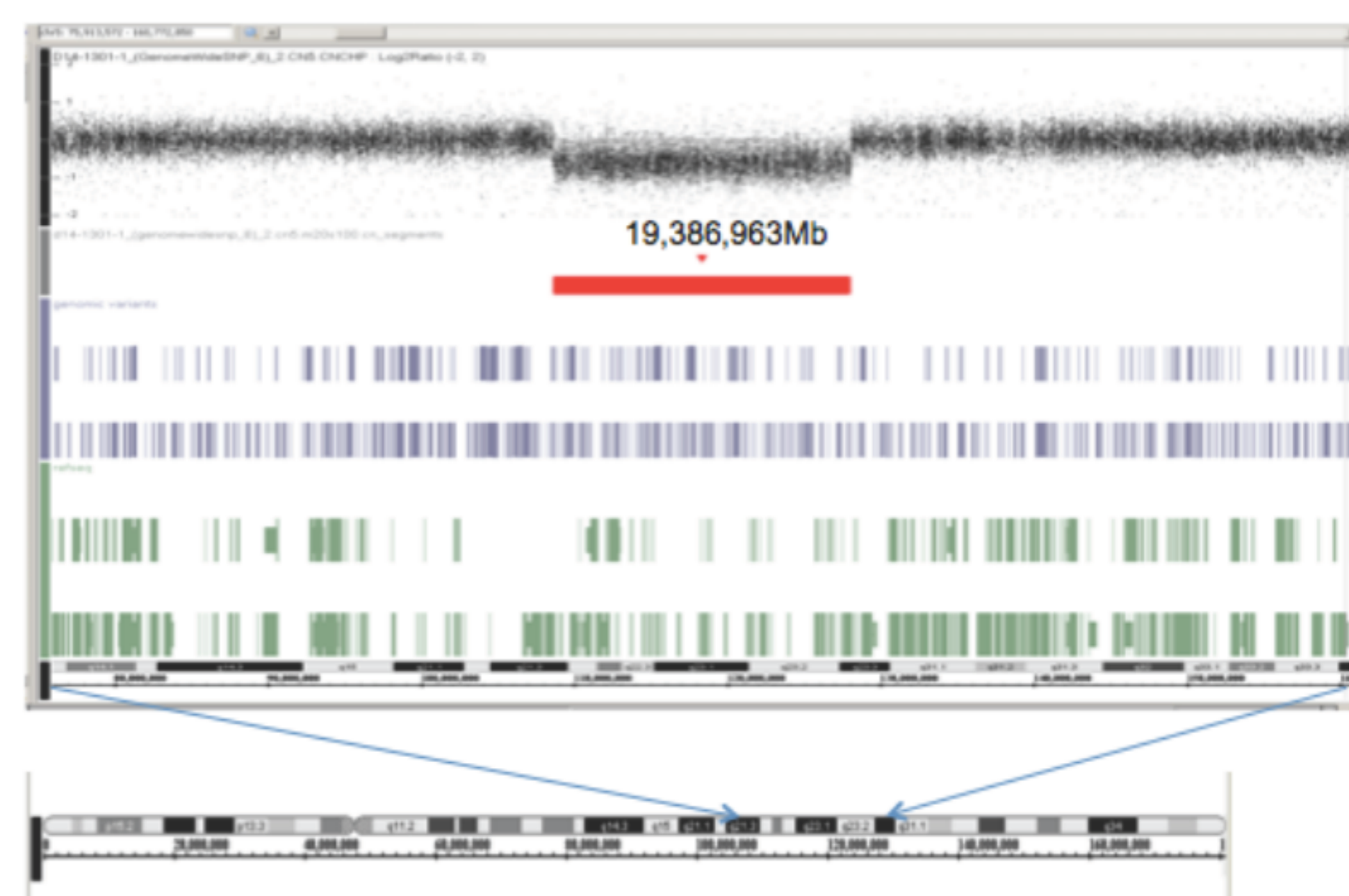
- **Ultrasonography and MRT:** adrenal tumor on the right side, 3,8 cm x 2,8 cm x 2,5 cm, volume 14 ml, irregular echogenity with small cystic lesions, no lymph node involvement, no metastases elsewhere



- **Further course:** Tumor resection at the age of 4 months, histologic classification as ACT (T2 N0 M0). Resolution of hypercortisolism within months. Continuing growth retardation. IGF1 and IGF BP3 levels far below the normal range (17 ng/ml \approx P0.3 bzw. 0.4 \approx P0). Diagnosis of severe growth hormone deficiency due to neurosecretory dysfunction at the age of 10 months. Subsequent growth hormone therapy with catch-up growth.

Molecular diagnosis

- further diagnostic evaluation because of facial dysmorphic signs becoming obvious after resolution of hypercortisolism along with unilateral clubfoot and cryptorchidism, horseshoe kidneys, nail dysplasia, muscle hypotonia and severely retarded psychomotor development at the age of 12 months.
- **comparative genomic hybridization:** identification of a large interstitial deletion in chromosome 5q expanding over a 19.4-Mb region (5q21.3–5q23.3) including the APC gene and a 3.1-Mb duplication in Yq (Yq11.223q11.23) {here not shown}.



Discussion: Large deletions of 5q as described in our patient were identified by conventional methods and reported early in the 90's. All these patients showed severe psychomotor development and variable other symptoms like short stature, abnormal ears and kidneys as well as limb abnormalities (1). The additional duplication is considered to be functionally irrelevant.

It is to assume that the deletion of the APC gene which is regarded as a tumor suppression gene caused the development of ACC in our patient. Germinal inactivating mutation of APC induces an autosomal dominant inherited syndrome called familial adenomatous polyposis (FAP), mainly characterized by multiple polyposis in the colon and rectum. The development of ACT in FAP rare, but its incidence in FAP patients is at least 2 times higher than in general population (2). In these patients two inactivating APC mutations are found: one inherited germinal mutation and another acquired somatic mutation in the tumor. The APC protein is part of a complex responsible for the degradation of beta-catenin which controls adreno-cortical proliferation in humans and mice (4). Its constitutive activation leads to adrenal tumorigenesis and promotes progression to malignancy. Activating mutations of beta-catenin or inactivating mutations of APC result in its abnormal nucleo-plasmatic accumulation which has been described in ACT's of patients with beta-catenin and APC mutations (4). These are not found in sporadic ACT cases, probably because of the need for 2 acquired mutations for tumorigenesis. Until now ACC has been reported only in adult patients (2). Development of other tumors like hepatoblastoma, papillary carcinoma of the thyroid and medulloblastoma are described in younger patients (2). Therefore a specific screening program is recommended in childhood, adolescence and young adulthood (3).

Conclusion: ACT caused by the deletion of the APC gene may occur even in childhood and infancy. Children with ACT and unexplained additional features should be screened for chromosomal deletions including known cancer susceptibility genes as APC in order to facilitate early detection of other malignancies which may develop in childhood, adolescence and young adulthood.

Literature:

1. Lindgren V et al.: Phenotypic, Cytogenetic, and Molecular Studies of Three Patients with Constitutional Deletions of Chromosome 5 in the Region of the Gene for Familial Adenomatous Polyposis. Am. J. Hum. Genet. 1992; 50:988-997
2. Mazzucco TL et al.: Genetic aspects of adrenocortical tumours and hyperplasias. Clin Endocrinol (Oxf). 2012; 77:1-10
3. Syngal S et al.: ACG clinical guideline: Genetic testing and management of hereditary gastrointestinal cancer syndromes. Am J Gastroenterol. 2015;110:223-62.
4. Berthon A, Stratakis CA. From β -catenin to ARM-repeat proteins in adrenocortical disorders. Horm Metab Res 2014; 46: 889-896

