

Novel Compound Heterozygous BMP1 variants associated with Osteogenesis Imperfecta

Aram Yang, Rimm Huh, Jinsup Kim, Sung Yoon Cho, Dong-Kyu Jin

Department of Pediatrics, Samsung Medical Center, Sungkyunkwan University School of Medicine, Seoul, Republic of Korea



All of the authors have nothing to disclose.

INTRODUCTION

- **Osteogenesis imperfecta (OI)** includes a group of disorders with a susceptibility to bone fractures, the presentation ranging from slightly increased fracture frequency to death in the perinatal period.
- Autosomal-dominant inheritance with type I collagen biosynthesis defects is the most common, but many autosomal-recessive genes have been previously reported.
- In the present study, we conducted Whole-exome sequencing to simultaneously investigate **multiple genes associated with the autosomal-recessive OI** in a Korean patient with umbilical hernia, frequent fractures, scoliosis, markedly short stature and dislocation of the radial head.

CLINICAL REPORT

- The patient was referred to us when she was 12 months of age. She was born after 37 weeks of gestation by spontaneous vaginal delivery. Her birth length was 49 cm (50–75th centile), and her birth weight was 3,400 g (75–90th centile).
- No family history of OI or other skeletal disorders was noted. The parents were nonconsanguineous and healthy. The patient's older sister was unaffected.

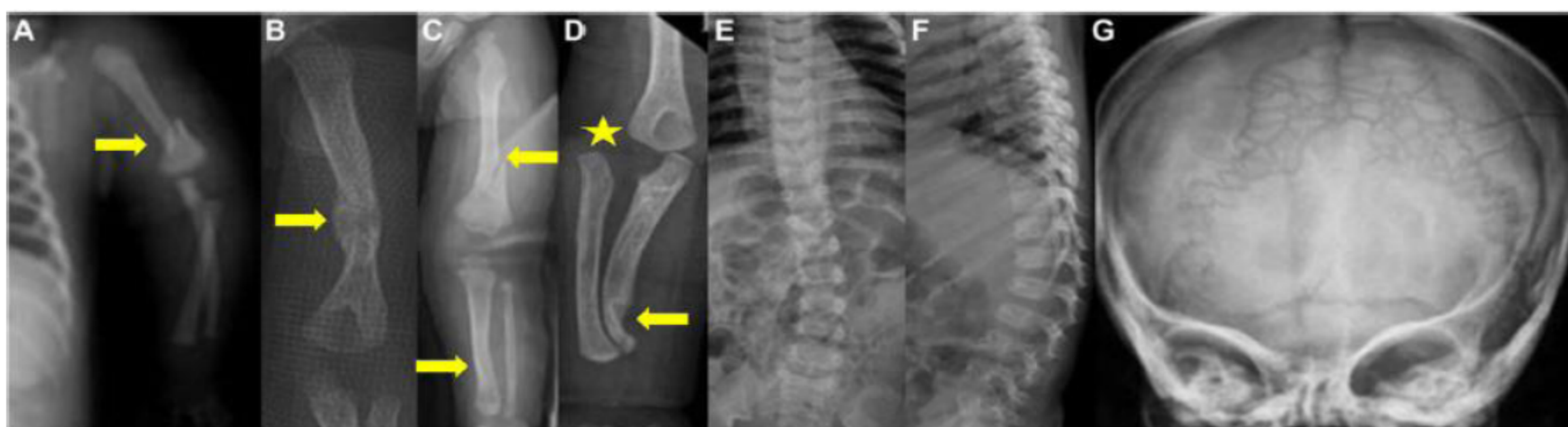


Figure 1 A-G

- A fracture of the left humerus with displacement was noted immediately after birth (**Fig. 1A**).
- **Right clubfoot**, an **umbilical hernia**, and a **simian line** on both hands were also noted.
- Physical examination revealed no dysmorphic features. The sclera was white and no dentinogenesis imperfecta was present. Her skin had normal extensibility with no bruising or scars. She had an **umbilical hernia**, **generalized hypotonia**, and **muscle wasting**. We noted **hyperextensibility** of the elbow, wrist, and interphalangeal joints. Mental development was apparently normal, but motor development was delayed. She was not able to sit unsupported at 12 months of age.
- Biological tests, including a routine blood cell count, blood and urinary levels of calcium, phosphate, creatinine, serum alkaline phosphatase, 25-hydroxyvitamin D, parathyroid hormone, and urine analysis appeared within normal ranges.
- A skeletal survey at the age of 12 months showed **multifocal fractures of the humerus, femur, and tibia** (**Fig. 1B and C**).
- Notably, there were bilateral radial head dislocations, with distal bowing of the radius and ulna (**Fig. 1D**).
- Mild scoliosis was noted, but spinal fracture was not observed (**Fig. 1E and F**).
- Skull radiographs at 20 months of age revealed wormian bones and a wide open anterior fontanel (**Fig. 1G**).
- We first sequenced the coding regions of COL1A1, COL1A2, and IFITM5. All of the coding exons and flanking intronic regions of the COL1A1, COL1A2, and IFITM5 genes were amplified for **Sanger sequencing** using primer sets designed by the authors.
- In result, **no pathogenic changes were detected in COL1A1, COL1A2, and IFITM5**.

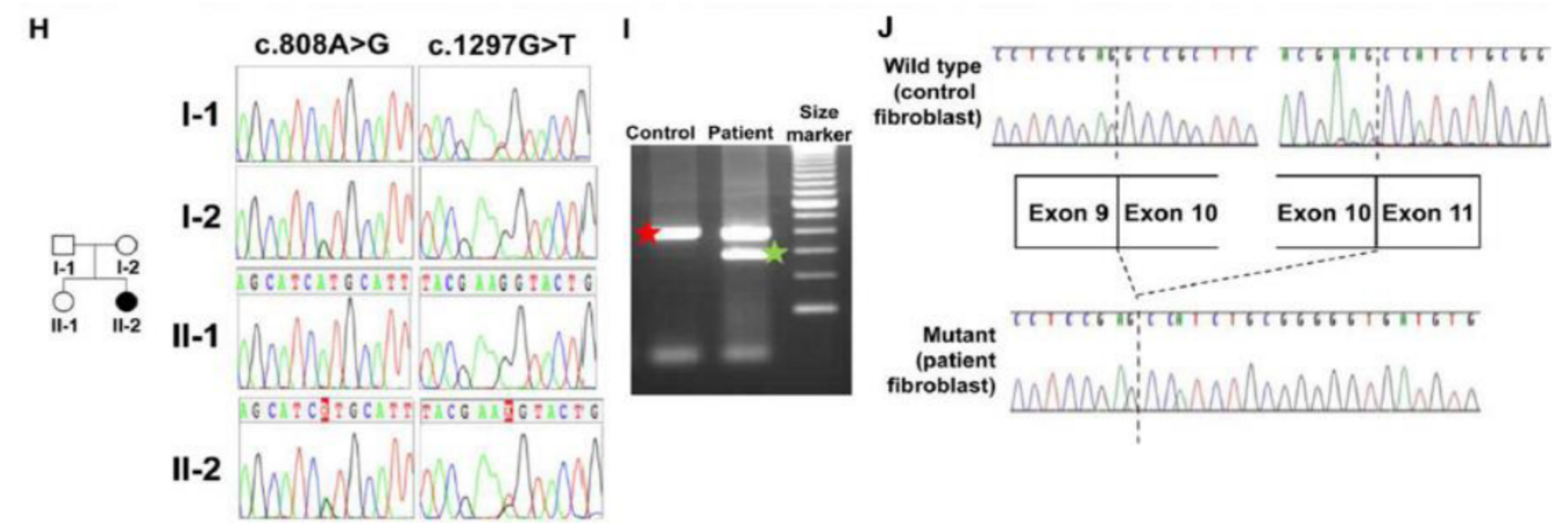


Figure 1 H-J

- We conducted **WES** to simultaneously examine multiple genes associated with autosomal-recessive OI.
- The examination of the known OI-associated genes revealed two novel variants in **BMP1**, **c.808A>G**, and **c.1297G>T**.
- Sanger sequencing validated the two variants using two independent samples. The patient was **compound heterozygous for the two variants**, which were inherited from both parents (**Fig. 1H**).
- **Reverse-transcription (RT)-PCR** analysis was performed to check whether the variant c.1297G>T caused aberrant splicing. RT-PCR analysis confirmed the **skipping of exon 10** in the skin fibroblasts of the patient but not in the normal controls (**Fig. 1I**).

Table 1. Zebrafish BMP1 Rescue Assay

Construct	Uninjected		Wild type			p.(Met270Val)			Exon 10 deletion		
	-	+	-	+	+	-	+	+	-	+	+
Viewed at (dpf)	3	3	3	3	6	3	3	6	3	3	6
Wild type fin (n)	186	185	154	265	155	55	147	116	178	196	193
Fruited fin (n)	63	64	49	10	36	20	38	30	64	59	60
Probability ^a	ns	ns	ns	P < 0.001	ns	ns	ns	ns	ns	ns	ns

- To examine whether the variants showed loss of proteinase function, we assessed the ability of variants to rescue the larval phenotype of the zebrafish *bmp1a* mutant, frilly fins (*frf*).
- Following larval sorting and heat-shock, the wild type construct transiently rescued the *frf* larval fin phenotype at 3 dpf (**Table 1**).
- In contrast, the two mutant BMP1 constructs did not rescue the fin defect (**Table 1**), despite similar expression levels.

DISCUSSION

- We identified two novel variants in the **BMP1 gene**: **c.808A>G** and **c.1297G>T**. The former variant caused a **missense change p.(Met270Val)** and the latter variant caused the **skipping of exon 10**.
- The **hypofunctional nature** of the two variants was demonstrated in a zebrafish assay.

- Our patient was classified as having **progressive deforming-OI type 3**.
- **BMP1** plays essential roles in osteogenesis and extracellular matrix formation and influences dorsal-ventral patterning through the indirect activation of some transforming growth factor β -like proteins. The c.808A>G:p.(Met270Val) variant in our patient corresponds to a fully conserved amino acid in both BMP1 and mTLD in all vertebrates.

- Indeed, mutant BMP1 cDNAs did not rescue larval fin ruffling in the *bmp1a* zebrafish mutant (**Table 1**), which is a phenotype due to defective collagen-rod formation.

SUMMARY

- In summary, we describe a patient with **autosomal-recessive OI** and identify **two novel compound heterozygous variants in BMP1**. We demonstrate the **hypofunction of these two variants in zebrafish**, which supports the involvement of these variants in causing abnormal bones. This observation **highlights the importance of BMP1** as a contributing gene to autosomal-recessive OI. Further investigations in other patients with BMP1 variants are needed.

