

Sirolimus therapy in an infant with Persistent Hyperinsulinemic Hypoglycemia

Yvonne Lim Yijuan¹, Andrew Sng An-jian¹, Khalid Hussein², Loke Kah Yin¹

¹Division of Paediatric Endocrinology and Diabetes, Khoo Teck Puat-National University Children's Medical Institute, National University Hospital

²Department of Paediatric Endocrinology, Great Ormond Street Hospital for Children, London



Introduction:

Persistent hyperinsulinemic hypoglycemia of infancy (PHHI) is a rare condition which presents with severe hypoglycemia during the neonatal period. For medically unresponsive forms of diffuse hyperinsulinemic hypoglycemia (HH), subtotal pancreatectomy was previously the only treatment option, with the potential consequences of recurrence of hyperinsulinism, diabetes mellitus and exocrine pancreatic insufficiency. The novel use of sirolimus treatment was recently reported in 4 infants who achieved good glycemic control¹. We report our experience with Sirolimus in an infant with PHHI who was partially responsive to diazoxide.

Case Report:

A neonate was diagnosed with PHHI when she presented with severe refractory hypoglycemia at birth. She was initially treated with diazoxide at 20mg/kg/day and a carbohydrate-rich diet. She responded well with minimal hypoglycemia until 7 months of age when she started having episodes of recurrent hypoglycemia. The side effects of diazoxide she experienced were hypertrichosis and decreased appetite. Mutational analysis demonstrated that she was heterozygous for a novel missense mutation on the ABCC8 gene. An 18-F DOPA PET scan showed that she had diffuse disease. At 18 months, she was commenced on sirolimus at an initial dose of 0.5mg/m²/day, gradually increasing weekly until the dose was 4.8mg/m²/day, with a therapeutic trough between 20-30 ng/ml. Diazoxide was eventually discontinued 2 months after sirolimus was started. She has continued on sirolimus for the past 15 months. As her blood sugars stabilized with normal meal times and overnight fasting, her dose was slowly decreased. At present, she is on sirolimus 0.7mg thrice a day (3.1 mg/m²/day). She only experienced 1 episode of severe hypoglycemia contributed by viral gastroenteritis, during which the sirolimus trough was suboptimal at 13 ng/ml. Side effects included transient mild elevation of transaminases, transient asymptomatic elevation of creatine kinase level (highest level was 1051 U/L, normal reference being 20-300 U/L) and intermittent oral ulcers. There were no hyperlipidemia, renal dysfunction and bone marrow suppression which were checked regularly with blood tests.

Discussion:

Mutations in ABCC8 are associated with severe hyperinsulinemic hypoglycaemia that is unresponsive to medical treatment with diazoxide and octreotide. Most of these children had to undergo subtotal pancreatectomy which involves removing 95-98% of the pancreas. The risk of recurrence of hyperinsulinism, diabetes mellitus and exocrine pancreatic insufficiency is high. The phosphatidylinositol-3-kinase (PI3K)/Akt/mTOR pathway has been implicated in the pathogenesis of hyperinsulinemic hypoglycaemia (Figure 1)². This was observed in insulinoma and mTOR inhibitors were used to treat insulinoma. mTOR serves as a master switch for cell growth, proliferation and apoptosis². It is hypothesized that mTOR inhibitors reduce beta-cell proliferation and inhibit insulin production. Also, it may induce their apoptosis and promote insulin resistance. Side effects include stomatitis, increased risk of infection, immunosuppression, abnormal renal function, fatigue, pneumonitis and transient elevation of liver enzymes³. In this case, we observed transient elevation of liver enzymes, asymptomatic elevation of creatine kinase level and intermittent mouth ulcers.

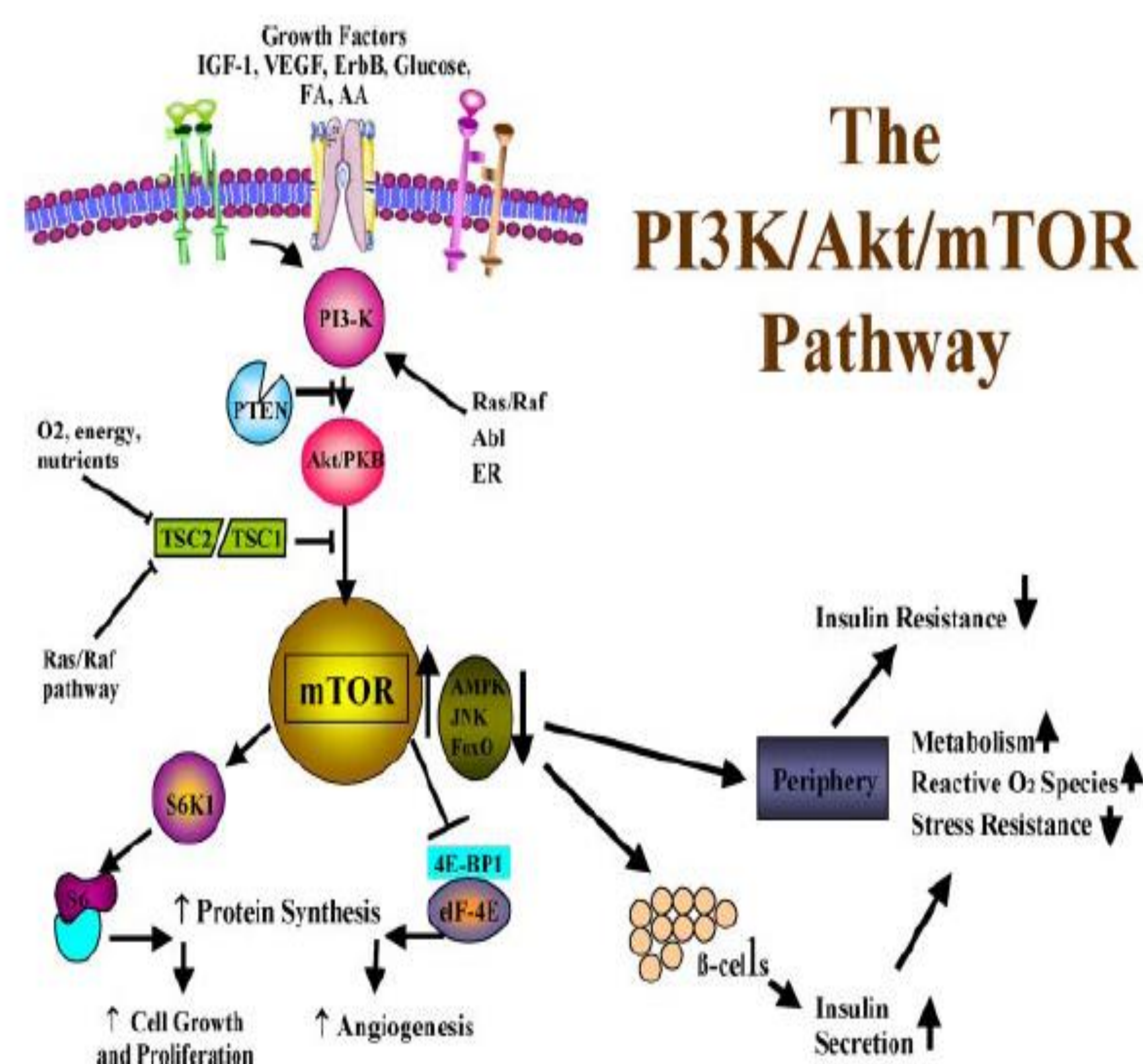


Figure 1: The phosphatidylinositol-3-kinase (PI3K)/Akt/mTOR pathway

Conclusion:

Sirolimus therapy is an alternative to subtotal pancreatectomy in severe diffuse PHHI, avoiding the side effects of hypertrichosis and fluid retention associated with diazoxide therapy. However, the duration of therapy in PHHI and the long term side effects have yet to be established.

Reference:

1. Khalid Hussain et al. Sirolimus Therapy in Infants with Severe Hyperinsulinemic Hypoglycemia. N Engl J Med 2014;370:1131-7.
2. Aaron I. Vinik et al. Successful Control of Intractable Hypoglycemia Using Rapamycin in an 86-Year-Old Man with a Pancreatic Insulin-Secreting Islet Cell Tumor and Metastases. J Clin Endocrinol Metab 94:3157-3162,2009
3. Monica Mita et al. The emerging safety profile of mTOR inhibitors, a novel class of anticancer agents. Targ Oncol (2009) 4:135-142

