

Be aware of congenital panhypopituitarism in children with a family history of polydactyly



Wilhelmina Children's Hospital

Idske C.L. Kremer Hovinga¹, Aimee D.C. Paulussen², Jacques C. Giltay³, Hetty J. van der Kamp¹.

¹ Dep. of Pediatric Endocrinology UMCU Utrecht; ² Dep. of Clinical Genetics UCMC Maastricht; ³ Dep. of Clinical Genetics UMCU Utrecht

Background

Congenital panhypopituitarism is associated with a variety of gene mutations. Abnormalities in the *GLI2* gene were only recently described to be associated with congenital panhypopituitarism (1). *GLI2* is a gene that encodes a transcription factor downstream of the Sonic Hedgehog pathway, a pathway known to play an important role in morphogenesis during embryology. *GLI2* mutations were initially described to be related to holoprosencephaly. However, more recent papers show that pituitary hormone dysfunction and polydactyly are mostly observed (2).

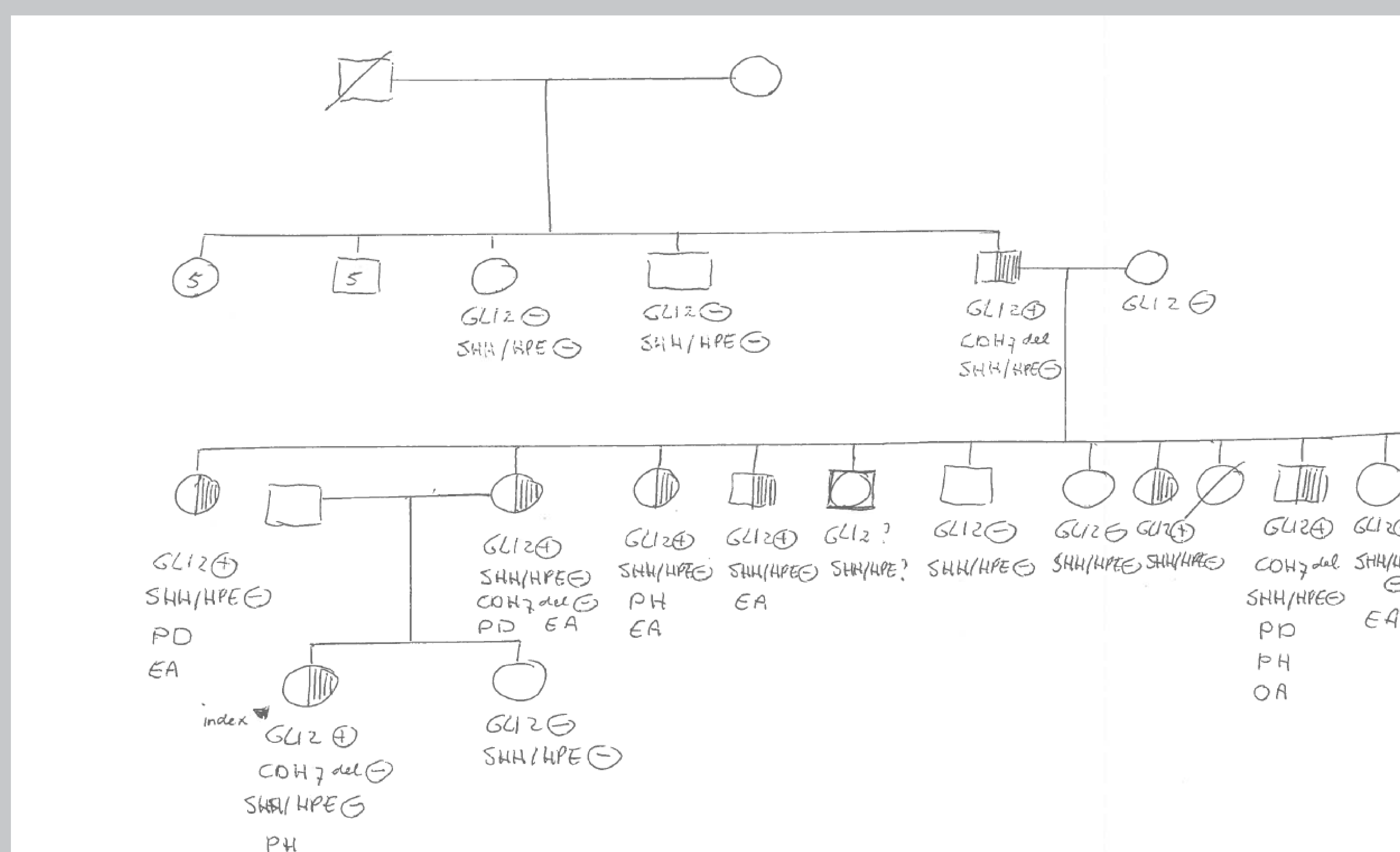
Case

The index case was a girl admitted with extreme failure to thrive at the age of six weeks. The heel prick screening for congenital hypothyroidism was normal. She experienced hypoglycaemia and hyperbilirubinemia in the neonatal period. Hormonal testing and MRI investigations showed panhypopituitarism and an ectopic neurohypophysis. Her mother had isolated polydactyly. Family history showed that out of twenty-six family members of three generations, six persons had either panhypopituitarism, polydactyly or both. One person had cryptorchidism, choanal atresia and a single median incisor, besides panhypopituitarism and polydactyly.

Research question

Our aim was to document the different phenotypes of family members with the same *GLI2* mutation and to investigate whether mutations in other holoprosencephaly or Sonic Hedgehog pathway related genes could be responsible for the difference in phenotype.

Results



SHH/HPE: *SHH*, *SIX3*, *ZIC2*, *TGIF*, *DISP1*, *PTCH1*, *GLI3*

PD: polydactyly; PH: panhypopituitarism; EA: glasses or eye abnormalities; OA: choanal atresia, cryptorchidism, single median incisor

Methods

From 13 of 26 family members DNA was extracted from peripheral blood samples. Dysmorphic features and patient histories were documented. Genetic analysis of the complete coding regions of the genes *SHH*, *SIX3*, *ZIC2*, *TGIF*, *DISP1*, *PTCH1*, *GLI2* and *GLI3* was performed by direct sequence analysis in both directions. Either available primers sets as designed by Applied Biosystems (AB) for VariantSeqr SNP discovery, or in-house designed primers following the same standards, were used. Sequences were aligned with known coding sequences. Mutation analysis was performed using Mutations Surveyor V3.30 (©Softgenetics).

Conclusions

In this family the same *GLI2* mutation is related either to a relatively mild phenotype of isolated polydactyly, or to a more severe phenotype consisting of pituitary dysfunction, in the absence of holoprosencephaly. This difference in phenotype is not the result of an additional mutation in the genes *SHH*, *SIX3*, *ZIC2*, *TGIF*, *DISP1*, *PTCH1* or *GLI3*. Two family members had a deletion in the *CDH7* gene. Since they had a different phenotype this deletion could not explain the phenotype. Knowledge of the co-occurrence of polydactyly and panhypopituitarism with the same gene defect is important for clinicians because (1) it provides a tool for early recognition of congenital panhypopituitarism and (2) it enables targeted genetic testing. Furthermore, these data confirm the role of *GLI2* in the embryogenesis of both the extremities and the pituitary gland. So be aware of congenital panhypopituitarism in children with a family history of polydactyly.

References

- (1) Novel heterozygous nonsense *GLI2* mutations in patients with hypopituitarism and ectopic posterior pituitary lobe without holoprosencephaly. França MM et al. J Clin Endocrinol Metab. 2010 5.
- (2) Pathogenic mutations in *GLI2* cause a specific phenotype that is distinct from holoprosencephaly. Bear KA et al. J Med Genet. 2014

