

Von Hippel-Lindau disease in an adolescent with a newly described alteration in the VHL gene

Sevil Ari Yuca¹, Emine Ayca Cimbek¹, Yasar Sen¹, Fuat Bugrul¹, İlhan Çiftçi², Doğan Köse³, Yavuz Köksal³

¹Selcuk University Medical School, Department of Pediatric Endocrinology, Selcuklu, Konya, TURKEY

²Selcuk University Medical School, Department of Pediatric Surgery, Selcuklu, Konya, TURKEY

³Selcuk University Medical School, Department of Pediatric Oncology, Selcuklu, Konya, TURKEY

Objectives:

Von Hippel-Lindau (VHL) disease is an autosomal dominant disorder characterized by susceptibility to tumors including hemangioblastomas of retina and central nervous system, renal cell carcinoma and pheochromocytomas. The disease is caused by mutations in the VHL tumor suppressor gene. We present an adolescent with VHL disease confirmed by genetic analysis which revealed the mutation p. A149P (PCC>GCC), which has not been reported to date.

Methods:

A 16-year-old boy presenting with headache and nausea to another medical center was referred to our clinic when diagnostic workup revealed bilateral adrenal masses.

Family history

Father: Central nervous system tumor, renal cell carcinoma, pancreatic cyst, bilateral adrenal tumors, and had died after bilateral surranelectomy.

Uncle: Central nervous system tumor, renal cell carcinoma, pancreatic cyst, bilateral adrenal tumors,

Aunt: Central nervous system tumor

Grandmother: Central nervous system tumor

Physical examination:

Weight: 67 kg (50th perc)

Height: 170 cm (25-50th perc)

Blood pressure: 125/75 mmHg (95th perc, 134/84 mmHg)

Tanner stage 5

MRI of the abdomen showed **bilateral adrenal tumors** (25x41 mm and 35x50 mm) (positive on metaiodobenzylguanidine **scintigraphy**)

Serum

Cortisol: 16.44 µg/dL (normal range, 8-19 µg/L)

ACTH: 30 pg/mL (normal range, 6-48 pg/mL)

TSH: 4.25 µIU/ mL (normal range, 0.56-5.57 µIU/ mL)

Free T4: 0.94 ng/dL (normal range, 0.89-1.76 ng/dL)

Calcitonin: 4.48 pmol/L (normal range, 0-18.2 pmol/L)

Urine

Epinephrine: 6.41 µg/L (normal range, 4-20 µg/L)

Norepineprine: 460.86 µg/L (normal range, 23-105 µg/L)

Normetanephrine: 4607 µg/L (normal range, 0-390 µg/L)

HVA: 3.76 mg/24h (normal range, 0-6.9 mg/24h)

VMA: 5.83 mg/24h (normal range, 1.4-6.5 mg/24h)

5HIAA: 1.42 mg/24h (normal range, 2-9 mg/24h)

Normal liver functions, renal functions and biochemistry

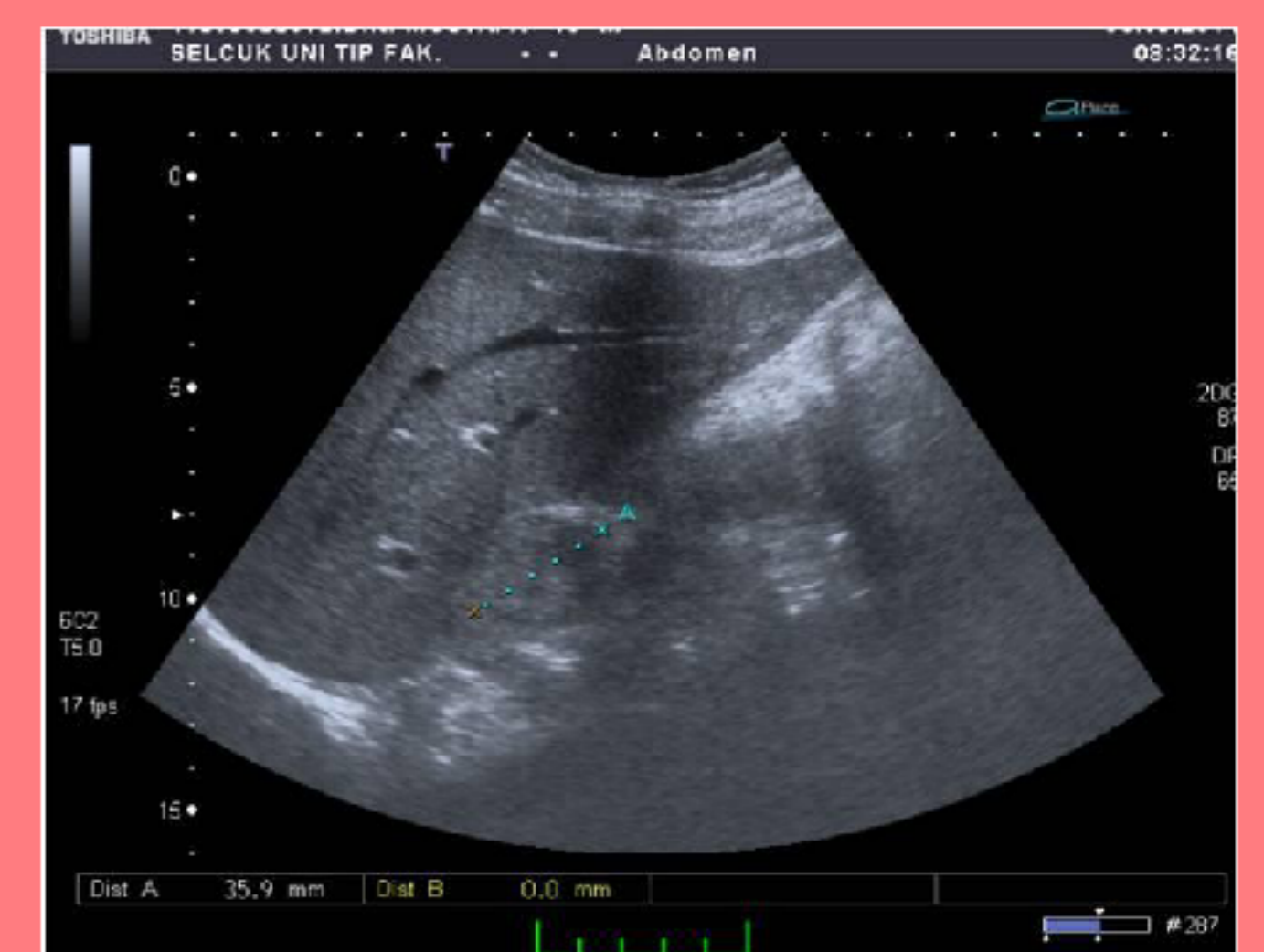


Figure 1. Ultrasonography showing left adrenal mass

MRI of the brain: Normal

Fundoscopy: Normal

Results:

The patient presenting with headache and nausea was diagnosed as **VHL disease** based on a **careful assesment of the family history**.

Bilateral adrenalectomy was performed. (Sympathetic blockade was established prior to definitive surgical treatment).

Immunohistochemical studies confirmed **pheochromocytoma**.

A heterozygous variant of the VHL gene, p. A149P (PCC>GCC), was verified.

RET proto-oncogene mutation: (-)

The patient was free of further manifestations of VHL disease 5 months after surgery.

Family screening: 9- year-old sister was found to harbor the same mutation.

Conclusions:

VHL disease should be clinically suspected in any individual presenting with bilateral pheochromocytoma and a positive family history.

Molecular analysis of the VHL gene is useful in the management and follow-up and can lead to the identification of presymptomatic relatives carrying the mutation.

Screening of patients and at-risk family members for VHL-associated tumors should be essential in management.

References:

1. Abbott MA, Nathanson KL, Nightingale S, Maher ER, Greenstein RM. The von Hippel-Lindau (VHL) germline mutation V84L manifests as early-onset bilateral pheochromocytoma. *Am J Med Genet A*. 2006 Apr 1;140(7):685-90.
2. Qi XP, Liu WT, Li JY, Dai Y, Ma JM, Zhao Y, Fei J, Li F, Shen M, Jin HY, Chen ZG, Du ZF, Chen XL, Zhang XN. p.N78S and p.R161Q germline mutations of the VHL gene are present in von Hippel-Lindau syndrome in two pedigrees. *Mol Med Rep*. 2013 Sep;8(3):799-805.
3. Abbott MA, Nathanson KL, Nightingale S, Maher ER, Greenstein RM. The von Hippel-Lindau (VHL) germline mutation V84L manifests as early-onset bilateral pheochromocytoma. *Am J Med Genet A*. 2006 Apr 1;140(7):685-90.

