

Congenital adrenal hyperplasia revealed by adrenal nodules

INTRODUCTION

Congenital adrenal hyperplasia (CAH) is a pathology with a genetic deficiency of one of the enzymes of steroidogenesis. It is due to 21-OHase deficiency in 90-95% of cases. The complete deficiency of this enzyme is responsible for the classic form (sexual ambiguity at birth with or without salt loss). While the partial deficiency results in a polymorphic clinical presentation occurring in childhood or adolescence. In rare neglected cases, the diagnosis is made during the exploration of adrenal masses

OBJECTIVE

Reporting phenotypic characteristics of adolescents with HCS revealed later during the exploration of adrenal masses

POPULATION, methodology

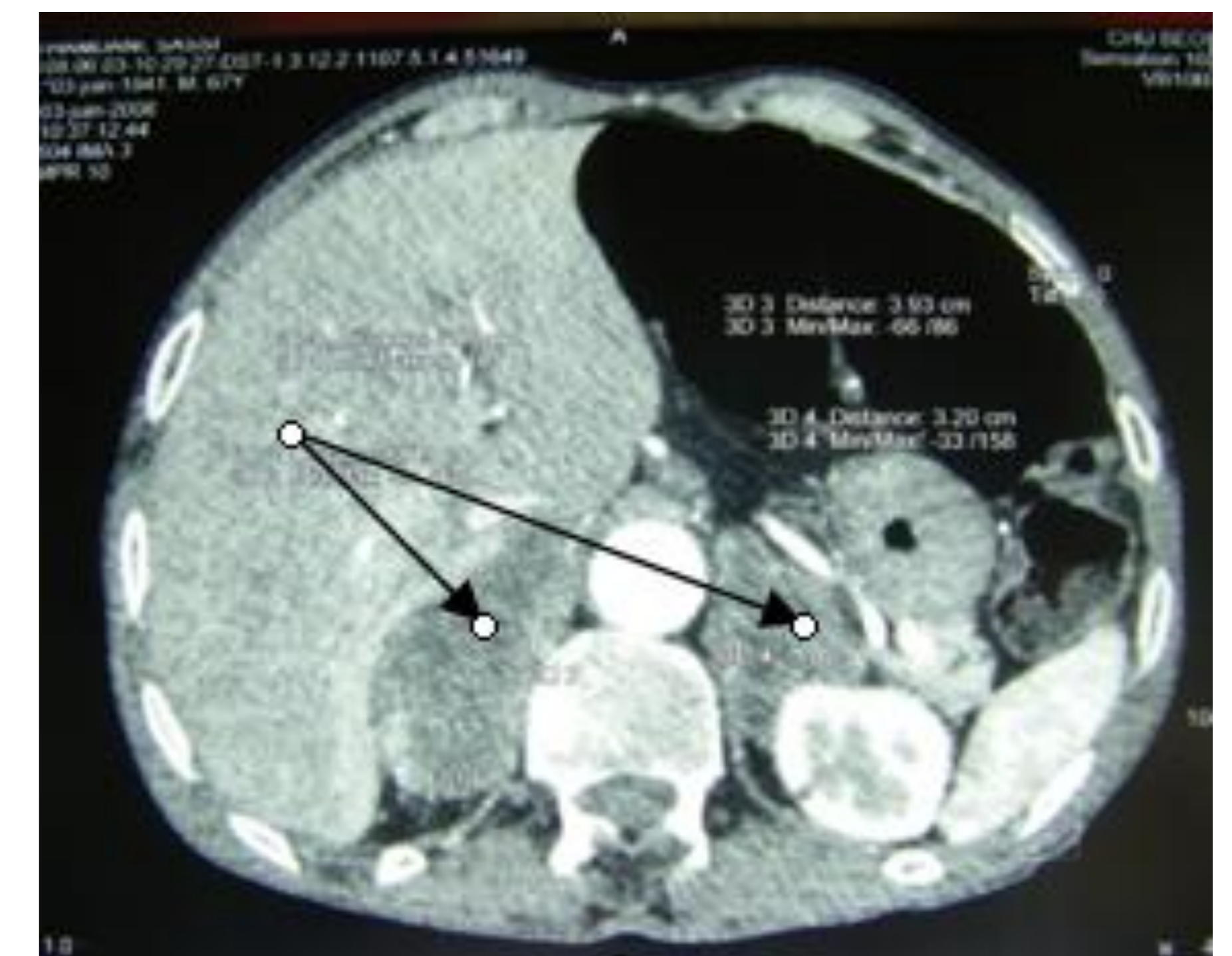
This is a retrospective study involved 6 teens carry a HCS unknown. A clinical and oriented paraclinical (biological and radiological) assessment was conducted.

Results

All patients were female. Their average age was 14 ± 0.8 (15- 18). The HCS was due to deficit in 21-OHase. Diagnostic circumstances are: exploration of amenorrhea : 4; Radiological discovery : 2.

The clinical picture found in all cases, an array of significant virilization with primary amenorrhea and small stature (average size - 2.5 SD / M SEMPE - 2 DS / TC)

Laboratory tests were in favor : DHA S average : 1245 ug / dl, 17 OH P average : 49.6 ng / mL, ACTH average : 90 pg / ml. Abdominal CT found bilateral nodular adrenal hypertrophy n: 6. Pelvic ultrasound found a small uterus with polycystic ovaries.



DISCUSSION

Enzymatic block is an autosomal recessive genetic disease with an incidence of 1/200 000 in the general population. It is linked to a hereditary endocrine disorder caused by a deficiency of enzymes of steroidogenesis. It is characterized by adrenal insufficiency and various degrees of hyperandrogenism (or hypoandrogenism), depending on the type and severity of the disease. Cortisol deficiency is responsible for increased production of ACTH responsible of hyperplasia adrenal glands. In case of chronic stimulation, secondary nodularisation appear and these may remain unchanged, or increase in size and become compressive same or degenerate.

The nodular hyperplasia risk is particularly important that the diagnosis is late and or replacement therapy is not taken regularly and effectively. Therefore, the search for a bilateral adrenal hyperplasia is systematic in any bilateral adrenal incidentaloma .

Similarly in case of long evolution of congenital hyperplasia or wrong or late treated, it should search an adrenal hyperplasia

CONCLUSION

HCS late-onset is a diagnosis to be systematically sought in front adolescent patients with signs of hyperandrogenism associated with virilization and cycle disorders. The diagnosis must be as early as possible to allow normal growth, female puberty and satisfactory fertility.

