

Saygin Abali^a, Ahmet Arman^b, Zeynep Atay^a, Serpil Bas^a, Sevda Cam^a, Zeliha Gormez^c, Huseyin Demirci^c, Yasemin Alanay^d, Nurten Akarsu^e, Abdullah Bereket^a, Serap Turan^a

^aPediatric Endocrinology, Marmara University, Istanbul, Turkey; ^bMedical Genetics, Marmara University, Istanbul, Turkey;

^cAdvanced Genomics and Bioinformatics Research Center TUBITAK-BILGEM-UEKAE, Kocaeli, Turkey;

^dDepartment of Pediatrics, School of Medicine, Acibadem University, Istanbul, Turkey;

^eMedical Genetics, Hacettepe University, Istanbul, Turkey

Background

Osteogenesis imperfecta type XVII (OI17) (MIM#182120) have been described recently¹ due to mutation in secreted protein, acidic, cysteine-rich (*SPARC*) gene located on 5q33.1.

Objective and hypotheses

Here we report a novel mutation in *SPARC* causing OI17.

Case

Two siblings presented to our clinic at the age of 10.3 and 0.5 years old. Parents were consanguineous.

The older one was born with birth weight -2.5 SDS and had contracture in distal part of the extremities. Severe scoliosis and hypotonicity was noted in early infancy. He stated to walk at the age 2.5 years and his first fracture has been detected at the age of 3 years in humerus. He was diagnosed as OI and pamidronate therapy had been initiated. Since then, patient has frequent long bone fracture i.e. humerus, femur with 4 fractures per year. Several long bone fractures, deformities, joint hyperlaxity, blue sclerae and inguinal hernia operation was noted in the patient. He had no dentinogenesis imperfecta. He had mild conductive hearing loss. His lumbar DEXA Z-score was -0.2 under pamidronate therapy for 6 years.

His sister was born term via C/S with a BW of -1.2 SDS. She was evaluated for OI when she was 6 month of age and a humeral fracture had been detected. Pamidronate treatment has been initiated and no fracture has been detected until the age of 16 months. The patient had axial hypotonicity and blue sclerae. The clinical feature of the patients has been given on the table

Whole-exome sequencing was performed and, homozygosity for nonsense variant, c.160G>T, p.Glu54X was identified in *SPARC* gene.

No other variants for known OI genes were detected.

Both siblings were homozygous for the mutation and their healthy parents were heterozygous for p.Glu54X mutation. This mutation was not found in IGBAM in house exome database including 1013 samples. This mutation was confirmed by Sanger sequencing.

Table 1. Clinical features of patients

| Age of diagnosis | 3 months | 15 days |
|--|-------------------|-----------|
| Birth | Term, spontaneous | Term, C/S |
| Birth weight (g) | 2500 | 2900 |
| Deformity in extremities | + | |
| Deformity in vertebrae | + | + |
| Fractures of ribs/ Deformity in thorax | NA/- | -/- |
| Joint hyperlaxity | + | + |
| Blue sclerae | + | + |
| Dentinogenesis imperfecta | - | |
| Umbilical Hernia | - | - |
| Inguinal Hernia | + | - |
| Nephrolithiasis | - | - |

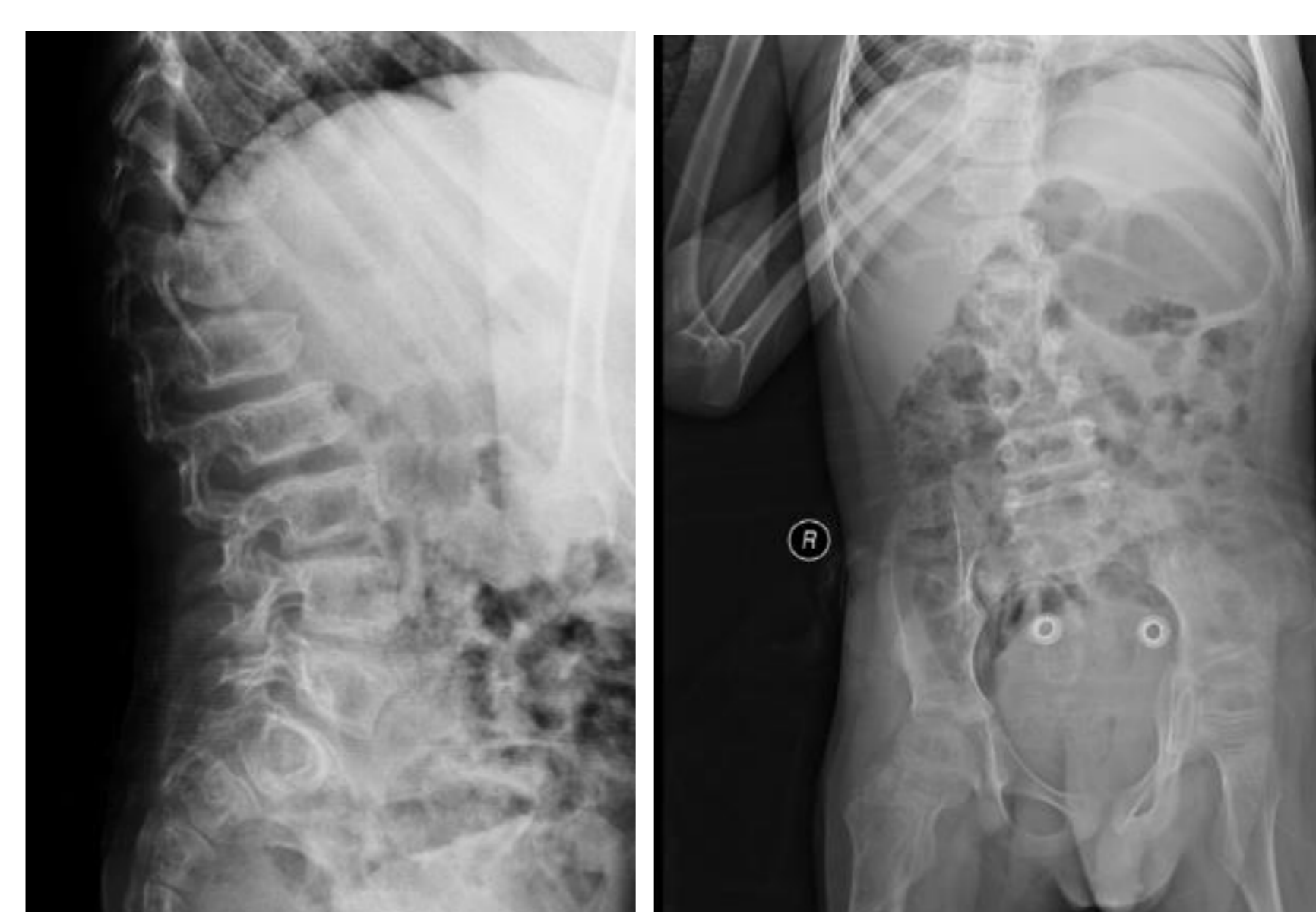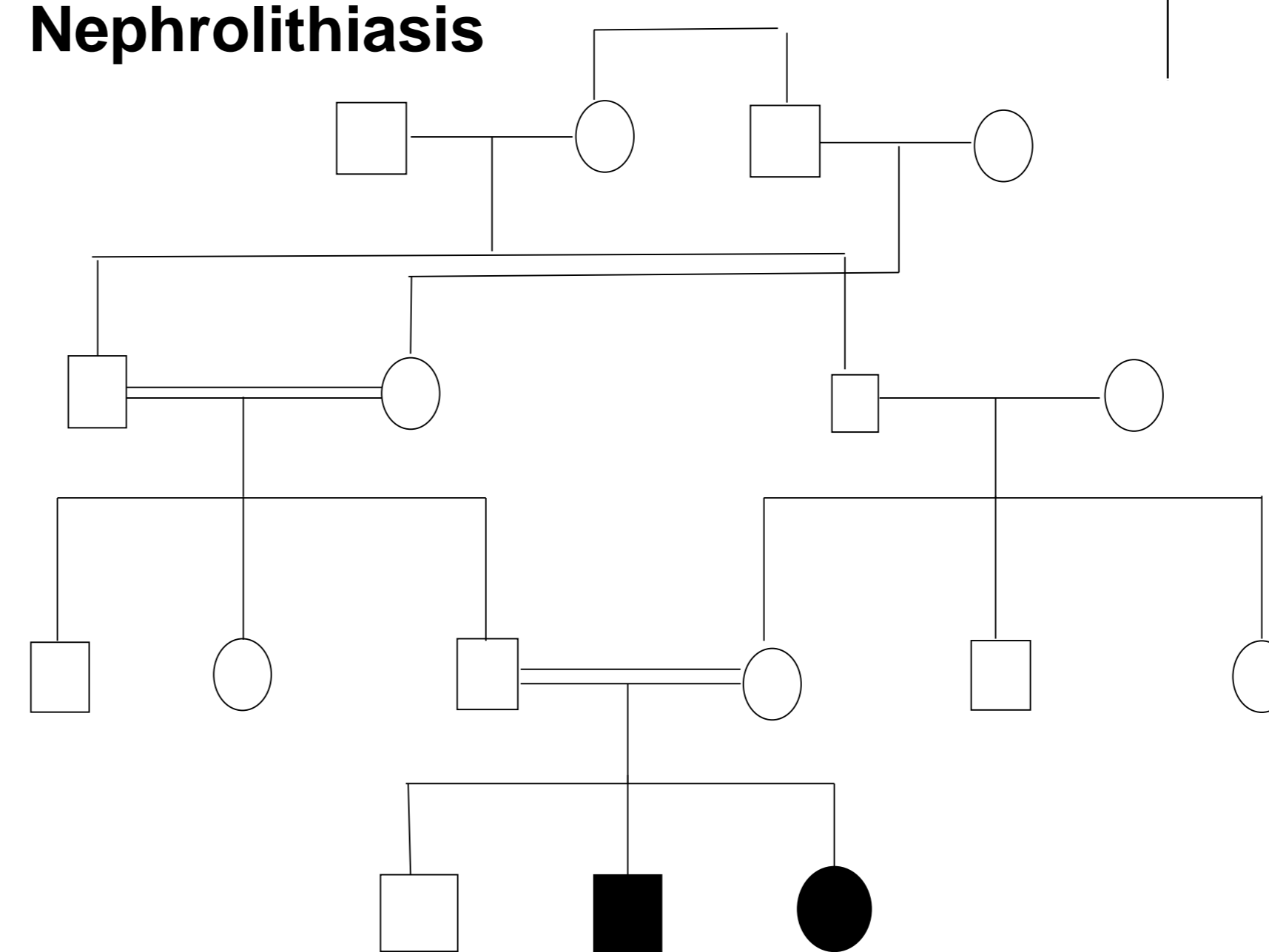


Figure 1. Lateral vertebrae and AP graphy of the boy

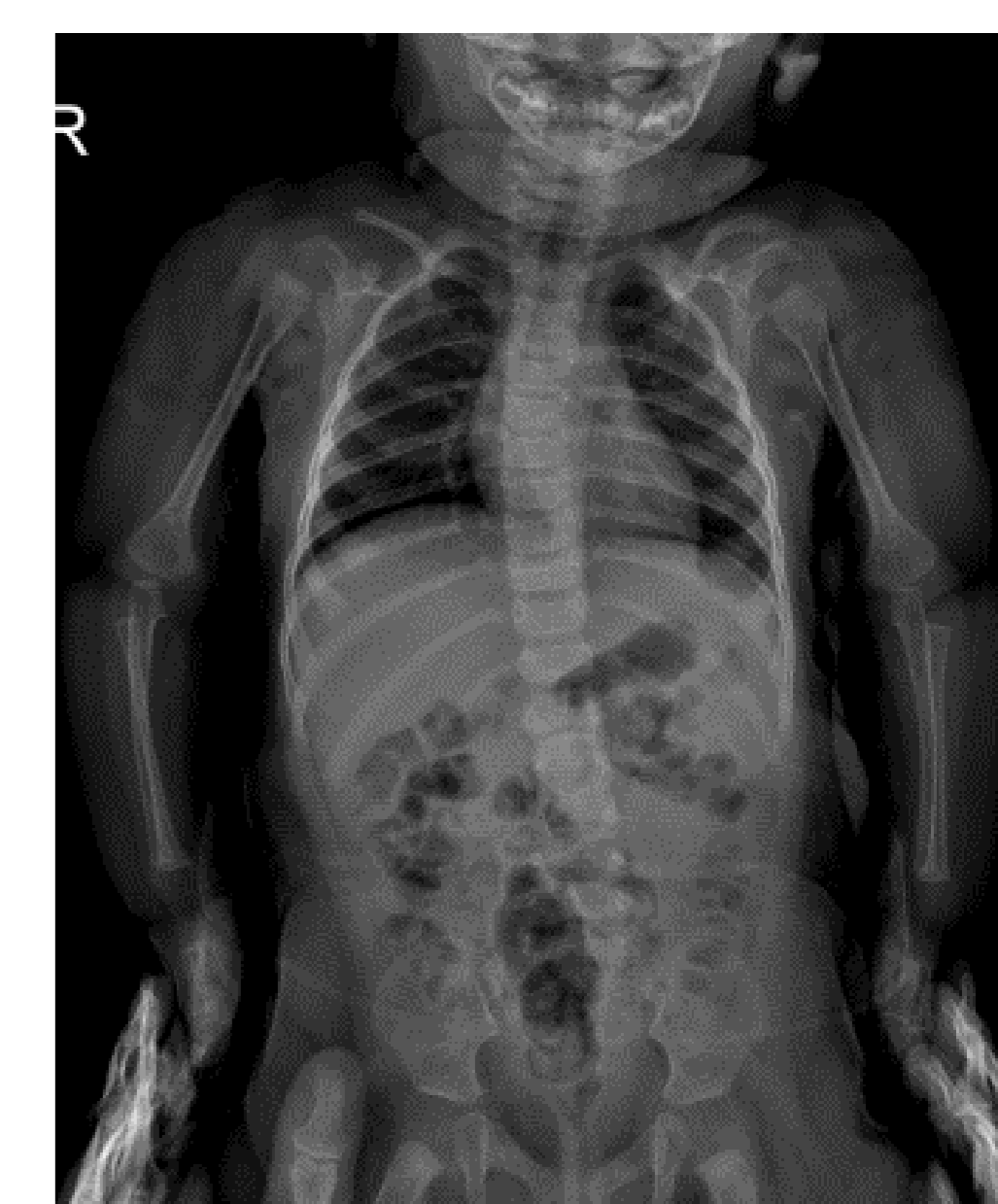

Figure 2. AP graphy of the girl

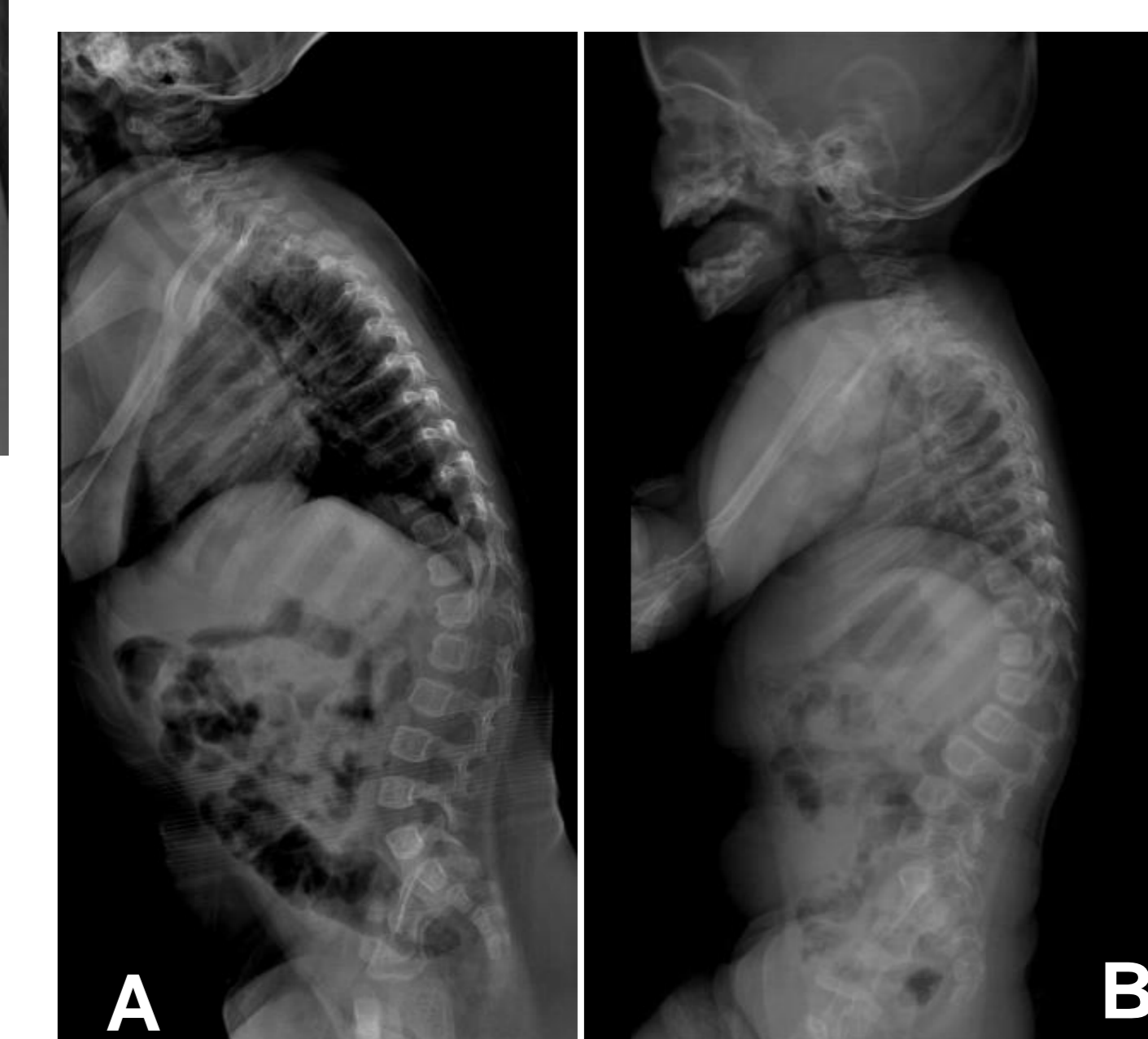


Figure 3. Lateral vertebrae graphy A. at admission and B. under pamidronate therapy

Conclusion

- ✓ We described clinical characteristics of two siblings with recently described OI17, new mutation in *SPARC* gene, which can be clinically classified as Sillence type 4.

Reference

- Mendoza-Londono R, Fahiminiya S, Majewski J. et al. Recessive osteogenesis imperfecta caused by missense mutations in *SPARC*. Am J Hum Genet. 2015 ;96: 979-85.