

# Antenatal Bartter's syndrome with bone-destroying hyperparathyroidism: about two cases, genetically proved, with long-lasting follow-up

Lefevre Christine<sup>1</sup>, Cartigny Maryse<sup>1</sup>, Weill Jacques<sup>1</sup>, Novo Robert<sup>2</sup>

1) Paediatric Endocrine Unit 2) Paediatric Nephrologic Unit. Lille (France) University Hospital

## OBJECTIVES

Bartter syndrome is a rare autosomal recessive syndrome caused by a defect of chloride reabsorption in the thick ascending limb in the loop of Henle. Its antenatal variant is accompanied by polyhydramnios intrauterine growth retardation and, after birth, hyponatremic polyuric hypokaliemia, alkalosis, hypercalciuria with nephrocalcinosis. It is principally underlain by the mutation of 3 genes coding for chloride channels.

## CASE REPORT 1

MV, born 01/07/2001, Born at 30 WA, With intrauterine growth retardation (Birth weight: 1160g)

Developed at one month of life: a typical Bartter syndrome with hypercalcemia (113 mg/L) and hyperparathyroidism (~ 200 pg/ml), hypercalciuria, stage 3 nephrocalcinosis.

Molecular genetic analysis confirmed an homozygous mutation of NKCC2 (**Bartter I**).

Classical treatment was undertaken, including indomethacin, water and salt supplementation, first through intravenous route and later through gastrostomy.

### Bone lesions:

From the age of 6, stiffness of elbows, knees, ankles were noted, with an handicapping limitation of movements, without biological stigmata of inflammation nor autoimmunity. X-ray examinations showed bone demineralization, subperiosteal resorption, chronic arthropathy of the mentioned articulations (figure 1).

At DEXA, density of the femoral neck is - 3.6 DS.

Growth was severely impacted but difficult to measure because of joint flexum (Fig 2).

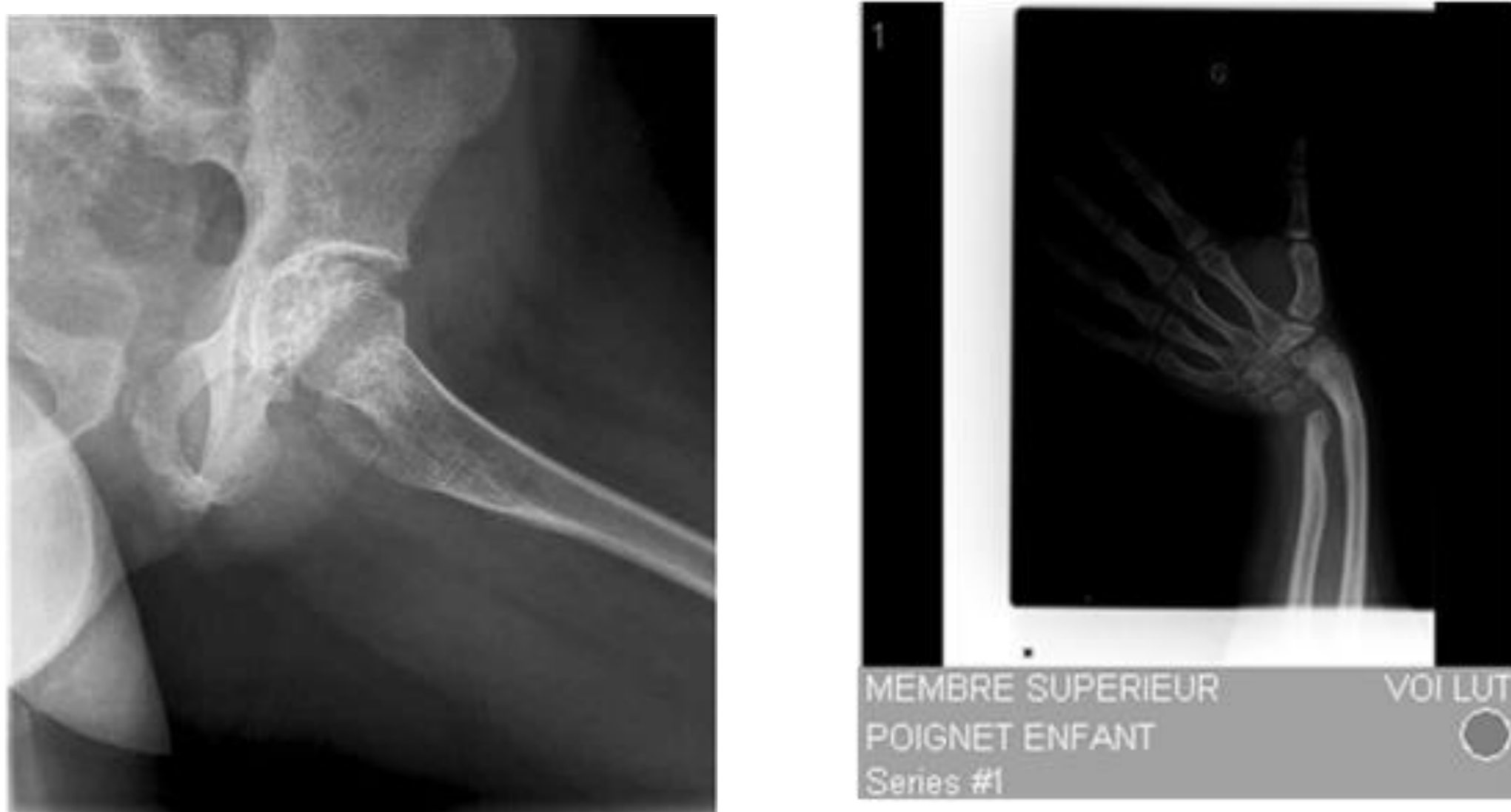

Figure 1: X-Ray aspect of hip and wrist

### Therapeutic attempts:

Cinacalcet, an agonist of the Calcium Sensible Receptor, from the age of 12 at doses of 15 and then 30 mg/d: reduces parathormone levels from ~ 300 to ~100 pg/ml and calcemia from ~120 to ~90 mg/L, which does not completely prevent bone resorption.

Surgical ablation of the right superior parathyroid gland, pointed out by the combination of a nodule at tomography and an increased fixation at MIBI scintigraphy after subtraction of I<sup>123</sup> thyroid imaging, at the age of 12. After a partial remission, hyperparathyroidism resumed.

Growth hormone (0.3 mg/kg/d) was administered from the age of 11y ¾ during 6 months and stopped because of the absence of any effect on height.

The biphosphonate zoledronate, an antiresorptive agent, obtained a partial beneficial result on calciuria and on plasma cross-laps, markers of bone resorption (figure 3).

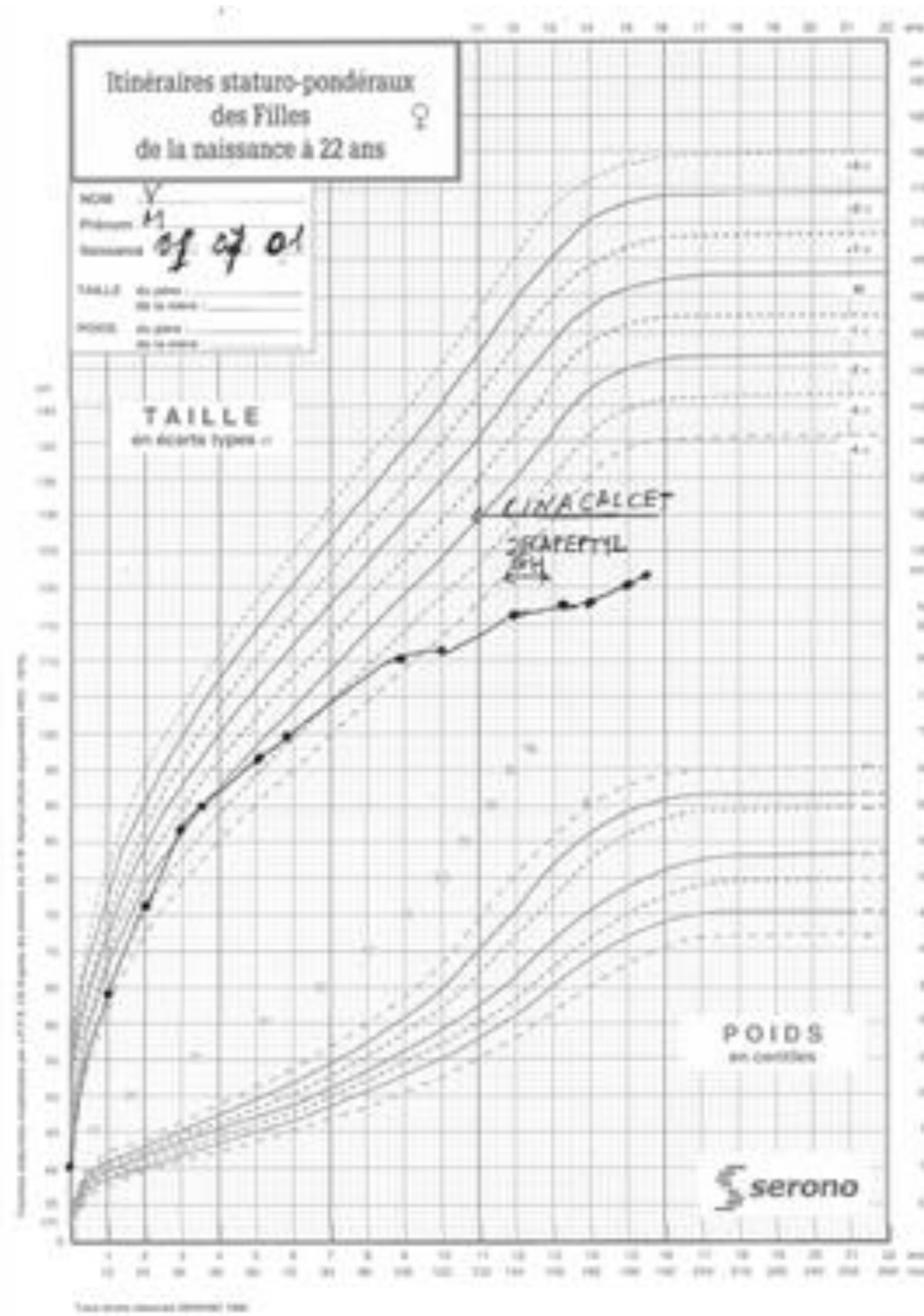


Figure 2: growth curve

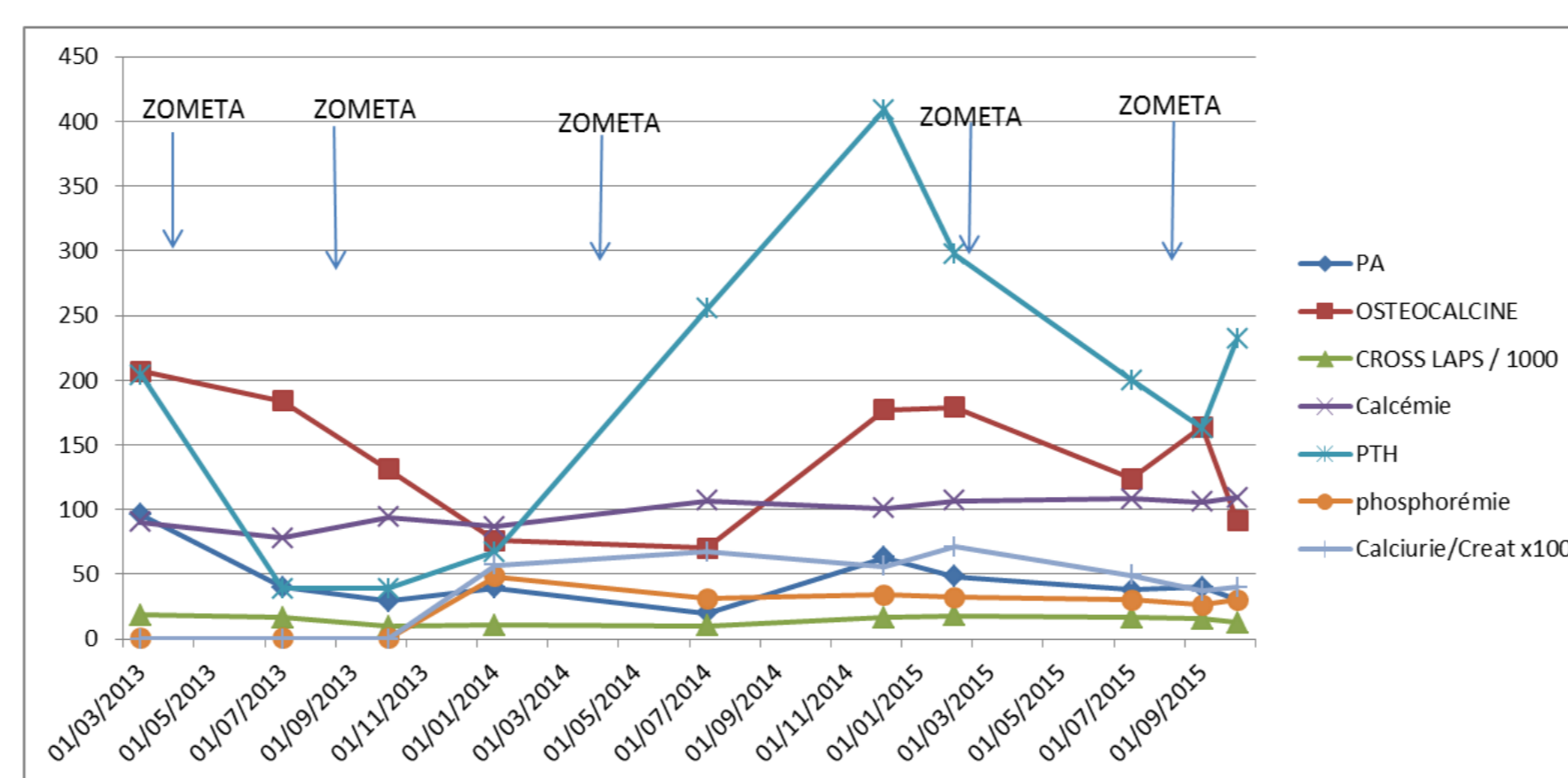


Figure 3 : effect of bone resorptive agent

## CASE REPORT 2

EM, born on 29/11/2007, presented during pregnancy and the neonatal period a typical Bartter syndrome. A classical treatment was started at day 10. Additionally, a deep bilateral transmission deafness was diagnosed later

Molecular confirmation was obtained with a heterozygous composite mutation of CIC-Kb gene, coding for Barttin (type III).

### Bone lesions

From age 3 months, calcemia ~120 mg/L and high plasma parathormone levels from 130 to 200 pg/ml were recorded.

4 y: X-ray aspects superposable to those of case 1.

Growth curve is displayed on figure 4.

### Therapeutics

- Cinacalcet, 15 mg/d, from the age of 4y, efficient on calcemia, parathormone levels and cross laps, markers of bone resorption, but stopped after 1y ¾ duration because of hypocalcemic convulsions
- Growth hormone was started at the age of 6y ¾ but did not improve growth velocity
- The biphosphonate, pamidronate was started at the age of 6y (posology: 1 mg/kg/d X 3), but did not influence biological data of bone resorption (calciuria, cross-laps) (figure 5)

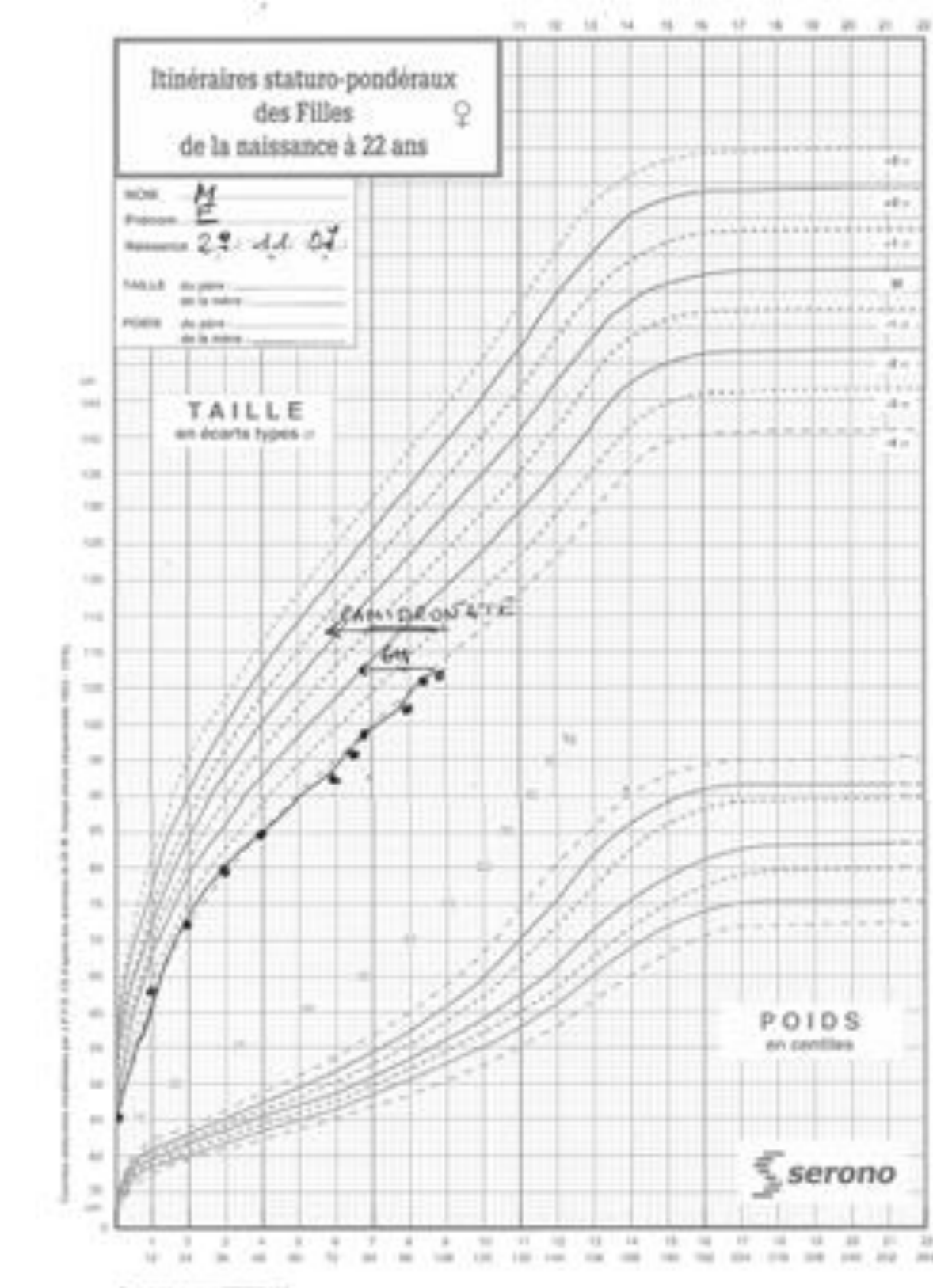


Figure 4: growth curve

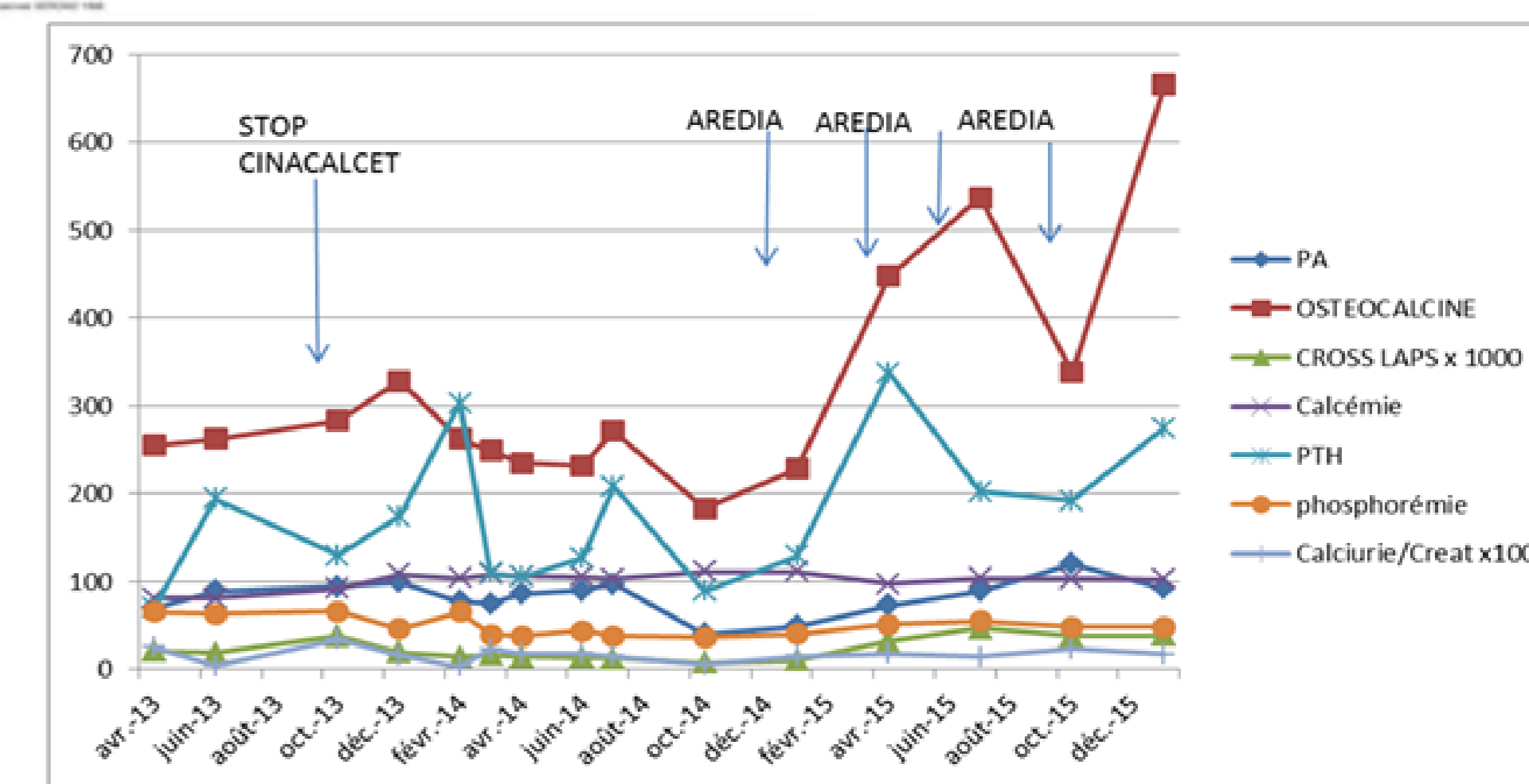


Figure 10: Effects of pamidronate on phosphocalcic and bone metabolism

## CONCLUSIONS

- 1) To our knowledge, only 15 cases of Bartter's syndrome with hypercalcemia due to hyperparathyroidism have been described till yet in the literature
- 2) These are the most long-lasting and severe recorded cases
- 3) Present hyperparathyroidism is probably linked to secondary autonomous development of a parathyroid reaction to calcium urinary leakage
- 4) It should be detected by a careful follow-up of calcemia in case of neonatal Bartter's syndrome
- 5) The administration of cinacalcet seems to be the most efficient treatment but should be carefully monitored and titrated because of the risk of severe hypocalcemia. The use of intravenous biphosphonates may be an option, but is not always efficient on bone resorption.

## REFERENCES

Gross I, Siedner-Weintraub Y, Simckes A, Gillis D. Antenatal Bartter syndrome presenting as hyperparathyroidism with hypercalcemia and hypercalciuria: a case report and review. J Pediatr Endocrinol Metab 2015; 28: 943-946

