

Ischemic intestinal necrosis as a Rare Complication of Diabetic Ketoacidosis in a Child with New-onset Type I Diabetes : a Case Report

Ji-Eun Lee, Hyung-Jin Kim, Sun-Ki Kim

Department of Pediatrics, Graduate School of Medicine, Inha University of Medicine, Inha University Hospital, Incheon, Republic of Korea

INTRODUCTION

Diabetic ketoacidosis (DKA) is the leading cause of morbidity and mortality in children with type 1 diabetes (T1DM). Although dehydration and electrolyte imbalance can be present in patients with DKA and T1DM, gastrointestinal tract complication remains unusual, especially in children. We report a child case of newly onset T1DM who developed acute ischemic intestinal necrosis with severe DKA combined with hypernatremic hyperosmolarity.

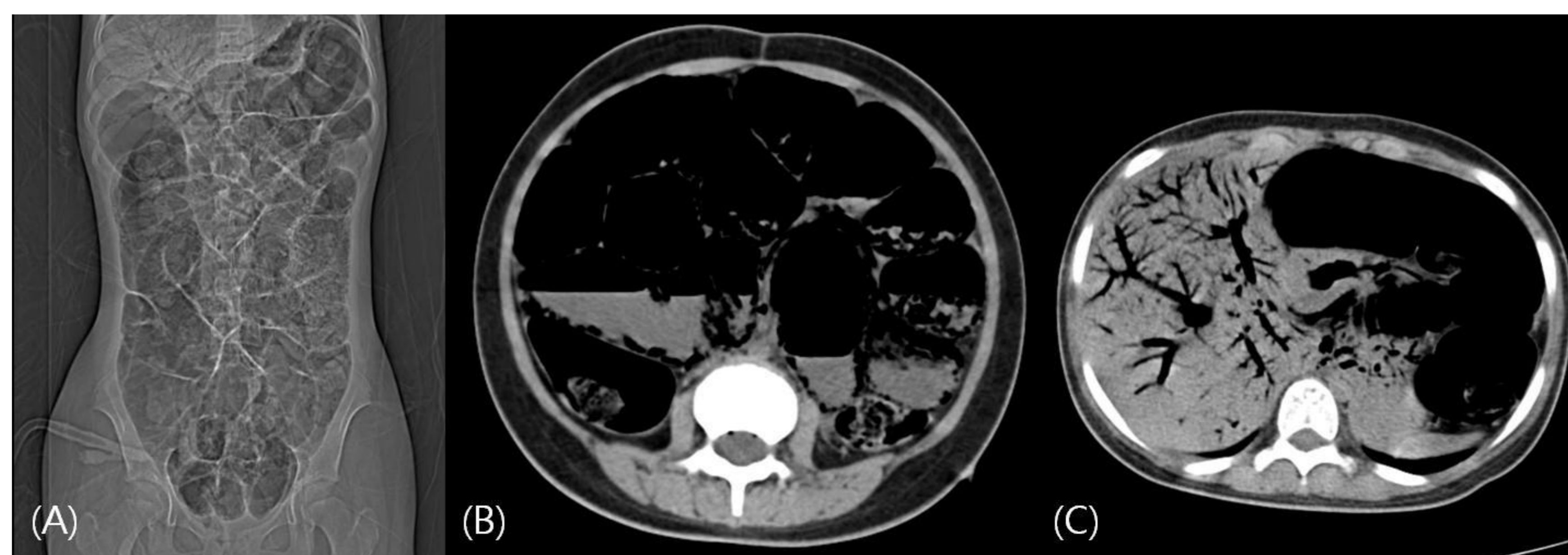
MATERIAL & METHODS

A 13-year-old previously healthy Korean girl presented with vomiting and progressive lethargy lasting 3 days. She had a 1-month history of polyuria and polydipsia and a 13 kg weight loss over a period of 1 month. Over the 1-month, the patient had intermittent episodes of vomiting but she only treated with intermittent medication for acute gastritis.

Initial Laboratory findings were as follows:

Hb 15.2 mg/dL Hct 47.5% WBC 24600 Plt 437K
CRP 0.2 mg/dL serum Glucose 1330 mg/dL HbA1c 17.6% Serum Ketone 1:8 positive, Urine Ketone 3+
ABGA pH 7.1-PCO₂ 13 mmHg- PO₂ 97 mmHg- Bicarbonate 4 mmol/L , Anion gap 48
C-Peptide 0.9 pmol/ml, Serum Insulin 10 uU/ml
Insulin Ab(-) Anti-Islet Cell Ab(-) Anti GAD Ab(-)
Serum Na 162 -K 3.7 - Cl 110 mmEq/L
Serum Osmolality 441 mmol/H₂O
Serum BUN /Creatinine 44.1 /1.3 mg/dL
Uric acid 15.7 mg/dL

Fig.1. Abdomen – pelvis CT image. (A) Scout image of abdomen – pelvis CT of patient. Aggravated state of gaseous collections in small bowel loops. (B) Generally distended small bowel and large bowel and showed air density in bowel wall. These findings were compatible with necrotizing enterocolitis with pneumatosis intestinalis. (C) There is marked portal venous gas. Portal air is usually a late finding and is associated with a poor prognosis



MANAGEMENT & PROGRSS

After 2hr from the time of initial presentation, she clinically improved with alert mental state and It continued infusion of a regular insulin. Despite intensive fluid resuscitation and insulin infusion, her consciousness level was rapidly worsened and abdomen wall was distended with rigidity. Emergent abdominal computed tomography showed necrotizing enterocolitis with pneumatosis intestinalis. Twenty hours after admission she died of ischemic intestinal necrosis induced shock.

CONCLUSIONS

DKA and hyperosmolar hypernatremia predispose the patient to develop thrombosis. Hypovolemia and hypernatremic hyperosmolarity in childhood DKA can lead to poor tissue perfusion and subsequent bowel ischemic necrosis. A high index of suspicion of intestinal ischemia as a potential complication of childhood DKA is critical factor influencing survival

Reference

1. *Pediatric diabetes*. 2005;6:90
2. *J Pediatr Surg*. 2003;38:1537

