

¿ IS IT CAUTIOUS TO WAIT FOR SERUM BASAL CALCITONIN LEVELS RISE IN PATIENTS WITH RET CODON C634 MUTATION?

E. González Ruiz de León, M. Sanz Fernández, MC. Rivas Mercado, MD. Rodríguez Arnao, A. Rodríguez Sánchez.
Unidad de Endocrinología Pediátrica. Hospital General Universitario Gregorio Marañón, Madrid.

Background :

2015 ATA Guidelines for management of medullary thyroid cancer (MTC) include C634 RET codon mutation in "High risk" group, recommending prophylactic thyroidectomy before 5 years old based on serum basal calcitonin levels (SBCt).

Objective and hypotheses :

We present 14 pediatric patients with C634 RET codon mutation, who underwent prophylactic thyroidectomy in our center, their clinical and analytical features and anatomopathological findings.

Method:

Preoperative tests:

- physical examination
- SBCt
- thyroid function
- parathyroid hormone
- urinary catecholamines
- cervical ultrasound.
- RET genetic test (most performed before consulting at our center)

Treatment:

- **Total thyroidectomy** ± cervical lymphadenectomy
- Substitutive lifelong levothyroxine was initiated as well as temporarily calcium and calcitriol.

Postsurgery follow up:

- Twice a year:
 - physical examination
 - SBCt
 - thyroid function
 - parathyroid hormone
- Yearly:
 - urinary catecholamines

Results:

- At the time of diagnosis all our patients were asymptomatic. They were studied as part of familial study when a first degree relative was diagnosed MEN2A.
- Clinical examination showed palpable thyroid nodule in only one patient (n°12), and was normal in the rest of them.
- Surgery was programmed at MEN2A genetic diagnosis confirmation, except in youngest patients (surgeons waited until 3 years of age).
- Total thyroidectomy was performed to the whole cohort, central neck lymphadenectomy was associated in 4 cases (suspicious lymph nodes).

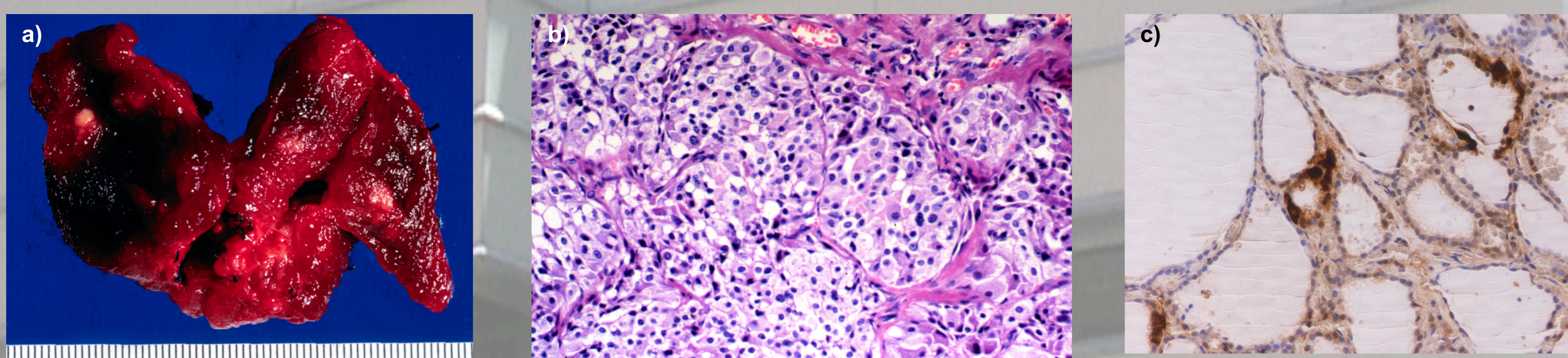
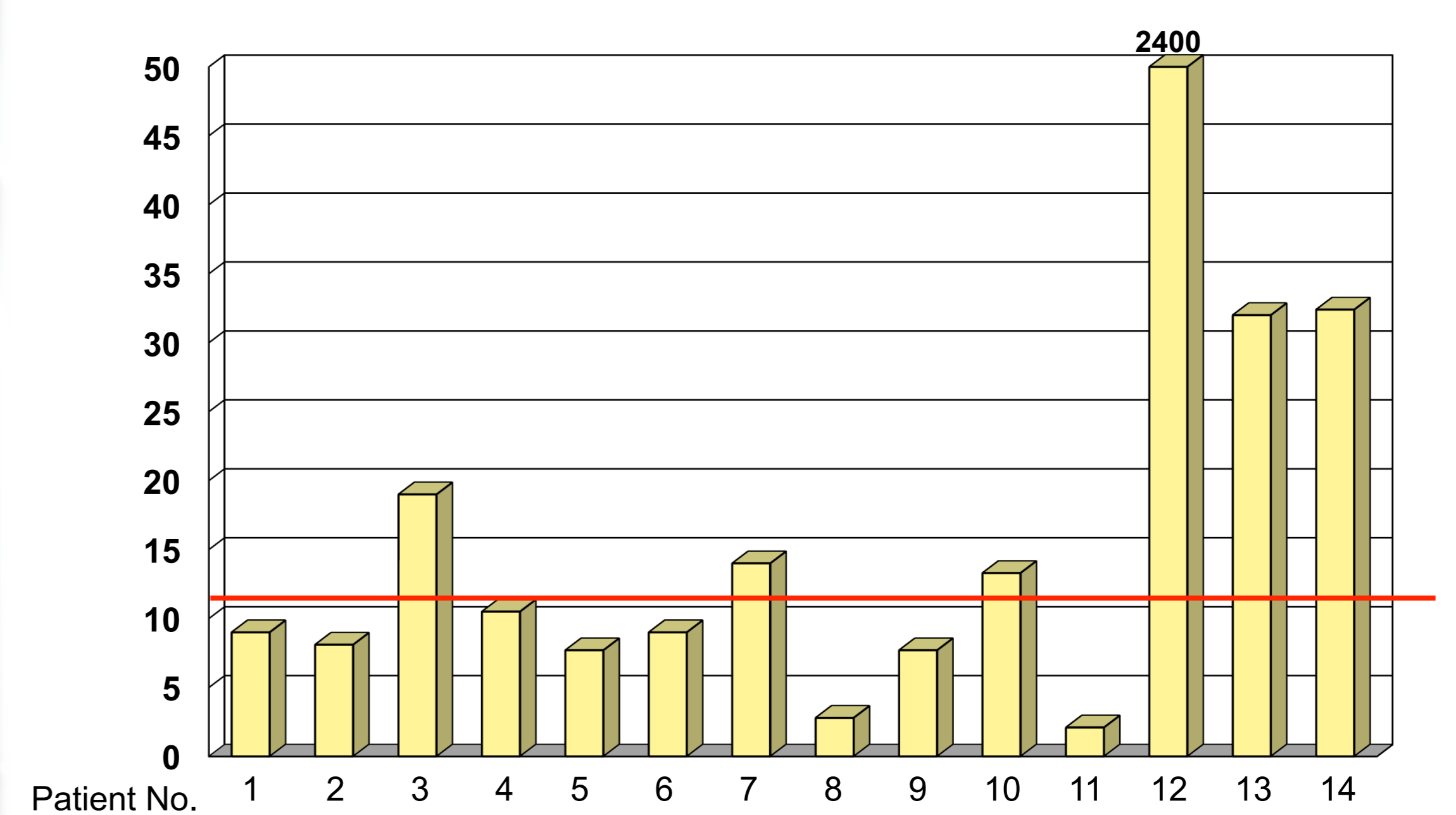


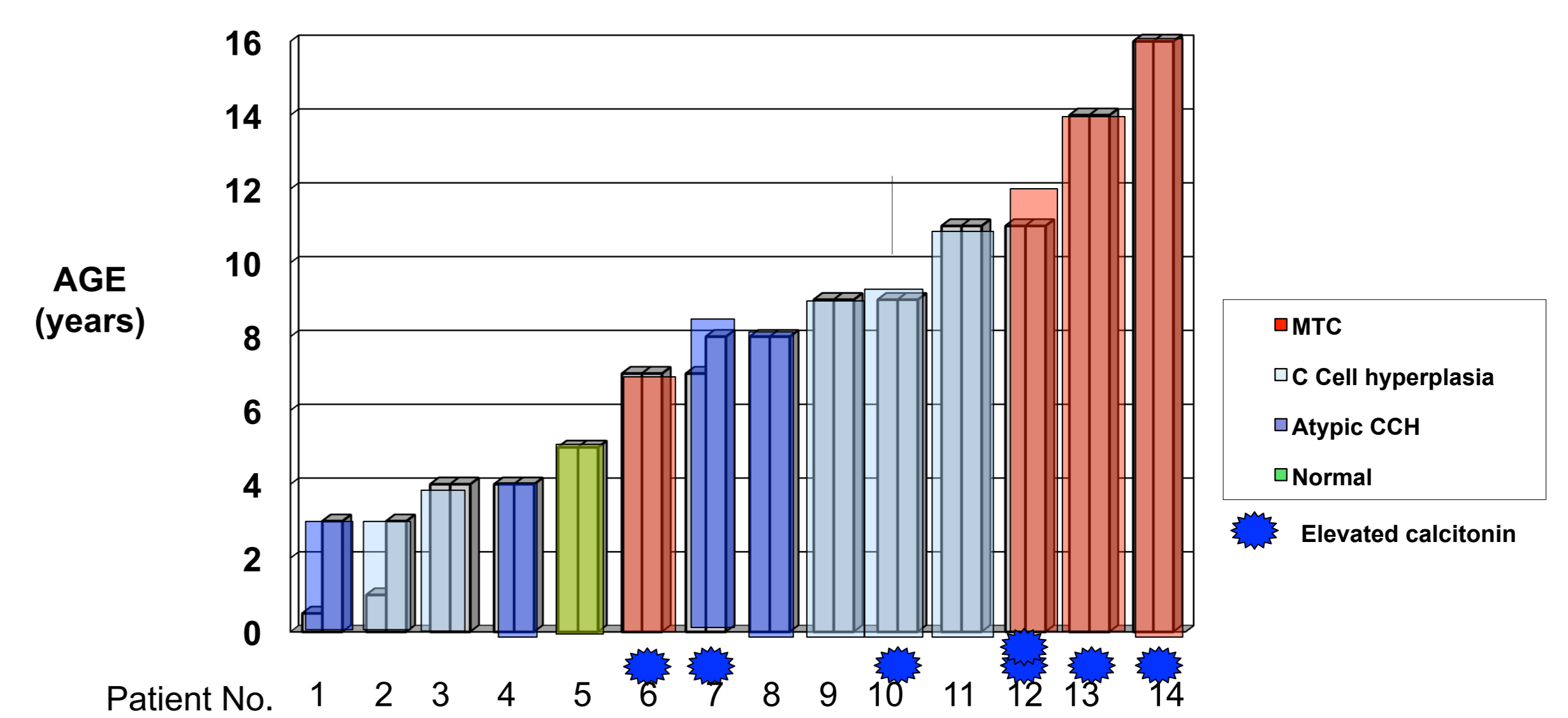
Figure 1. a) Removed thyroid in a patient presenting CMT. b) Haematoxylin and eosin staining of a medullary thyroid cancer. Eosinophilic granular cytoplasm cells infiltrate and destroy normal thyroid parenchyma. c) Immunohistochemistry calcitonin staining of the same MTC.

- One patient (n° 12) suffered a surgical site hemorrhage solved with a Penrose drainage for 24 hours. No other postsurgical complications occurred.
- During postsurgery follow-up the girl (n° 12) presenting CTM with lymphatic metastases who had elevated SBCt with negative extension studies. The rest of patients presented negative SBCt and controlled thyroid function with substitutive treatment.

PRESURGICAL CALCITONIN (ng/L)



AGE AT SURGERY, PATHOLOGY AND ELEVATED CALCITONIN



Conclusion:

- ✓ SBCt cannot reliably discriminate between C cell hyperplasia (CCH) and MTC. In our cohort every MTC patient had elevated SBCt, the same as three patients having CCH. The rest of CCH patients presented normal SBCt, even those having atypias.
- ✓ Elective total thyroidectomy is well tolerated by most infants, associated with minimal morbidity if performed by high-volume surgeons.
- ✓ Our recommendation is to perform prophylactic thyroidectomy as soon as high-volume surgeons accept in RET 634 codon mutations.