

# CANDLE syndrome – a new autoinflammatory lipodystrophic disorder with challenging diagnosis and limited therapeutic options

V. Boyadzhiev, M. Boyadzhiev, L. Marinov, V. Iotova  
Medical University/UMHAT „St. Marina“ Varna, Bulgaria

## Introduction

Autoinflammatory syndromes are by definition systemic diseases, caused by errors in the innate immunity, where main effectors are neutrophils, NK – cells, dendritic cells, the complement, acute phase reactants (1). For that reason they present with high inflammatory response and rarely are positive for immunologic markers. Most of the autoinflammatory syndromes have already discovered genetic basis.

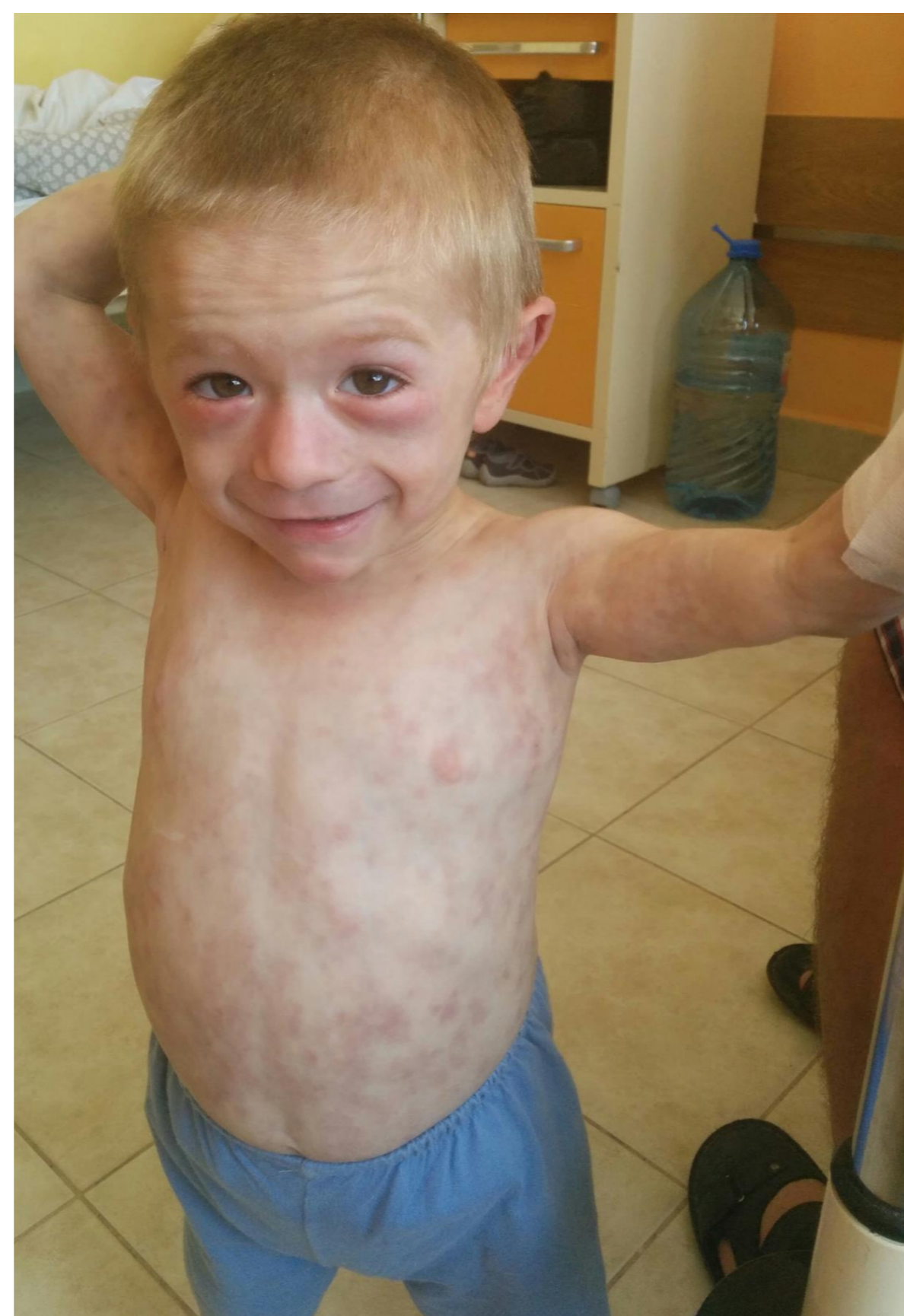## Case report

Our patient is a 4 years old boy, born from fist, uneventful and full-term pregnancy of unrelated couple, without relevant family history.

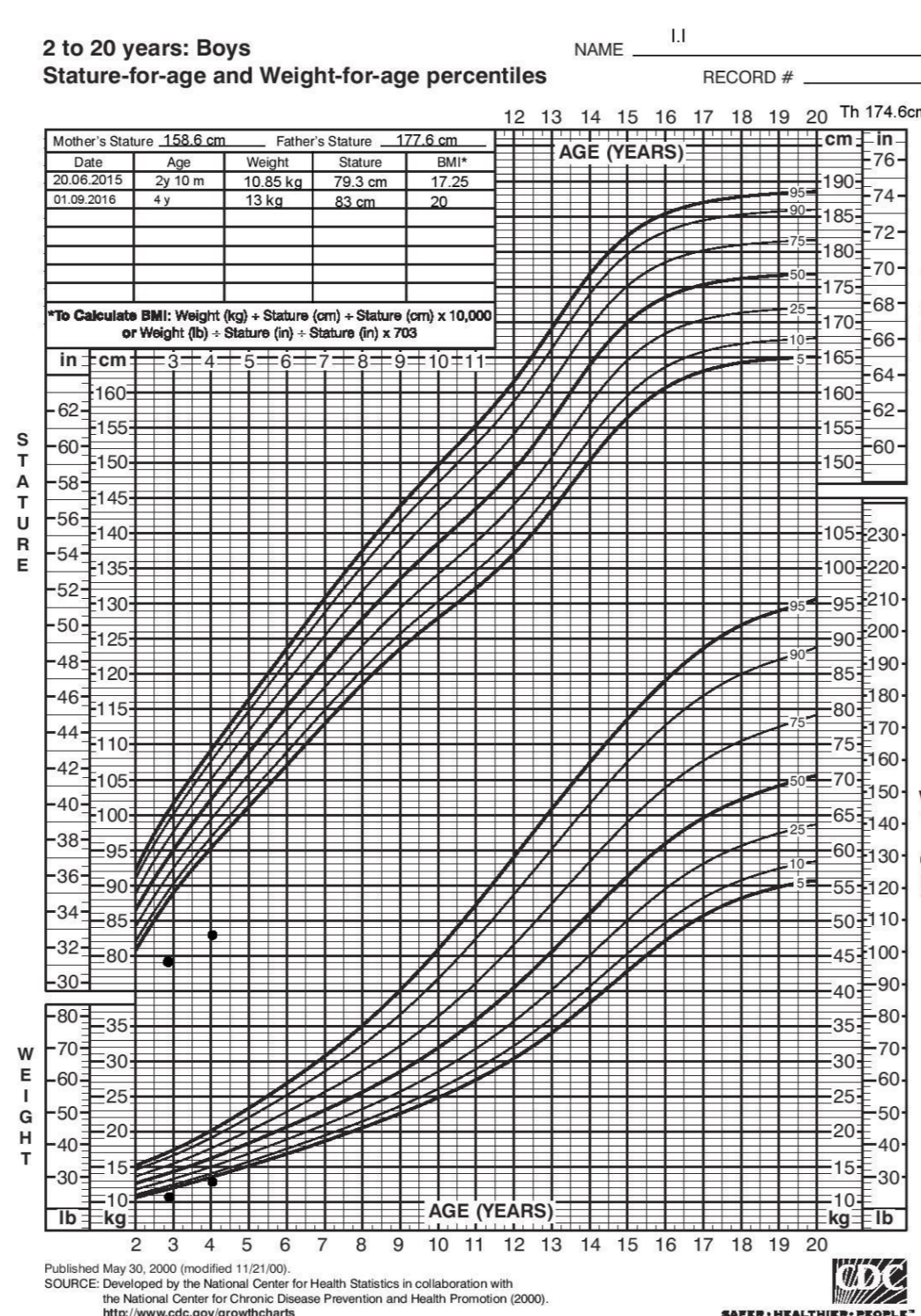
At 20 days of age erythemic eruption with hemorrhagic blisters appeared on the palms. In the next few months the rash spread all over the body, with solitary nodules, accompanied with violaceous periorbital swelling and elevated temperature during the flares.

At 2 years and 10 months the boy presented to us with the following features:

- **Lipodystrophy** on the arms and shoulders
- **Peculiar face** with an old man's look, slight hypertelorism and epicanthus
- **Hands** with long fingers
- **Hepatomegaly**
- **Anemia, elevated ESR and CRP**
- **Growth retardation** with significantly decreased height (-4 SDS) and weight (-2 SDS)



2 years and 10 months old



**T2-weighted magnetic resonance** image of the thighs, showed loss of subcutaneous fat, particularly on the posterior aspect of both thighs, and the increased signal intensity in the subcutaneous fat suggested panniculitis(2).

**Biopsies** from the lesions have been taken. Skin and subcutaneous tissue showed perivascular and periadnexial inflammation, consisting of lymphocytes, neutrophilic cells, macrophages and mastocytes (CD 117-positive). The latter were insufficient for the diagnosing mastocytosis. Sporadic Langerhans cells were also present.

After a search in the available data in the literature an autoimmune or an autoinflammatory disease was suspected.

Blood samples from the child and both parents were sent to NIH for genetic testing. Our patient was found to have two mutations in the PSMB8 gene. The inheritance type is compound heterogeneous.

The first mutation – p.A92V was recently described in a report from Brehm et al. in 2015. The second one – p.K105Q, has never been described before Both parents are carriers of one mutation.

The genetic testing was done at NIH (AI) and compound heterozygosity for the PSMB8 gene mutations was found (p.A92V and the novel p.K105Q).

## Discussion

Chronic atypical neutrophilic dermatosis with lipodystrophy and elevated temperature (CANDLE syndrome) has been described by Torello et al. in 2010, first in 4 children between 2 and 14 years (2)

Several mutations in proteasome genes are now proven to cause CANDLE syndrome - PSMA3, PSMB4, PSMB8, PSMB9, POMP (2,3). Different types of inheritance are possible – autosomal dominant, compound heterozygous, double heterozygous.

The main clinical features of the syndrome are (4):

- presentation in early infancy, most commonly in the neonate period
- frequent episodes of elevated temperature
- erythematous nodules on the body and the extremities, most prominent during flares
- violaceous periorbital swelling
- progressive loss of fat tissue (lipodystrophy)
- arthritis
- hepatomegaly
- low height and weight for age

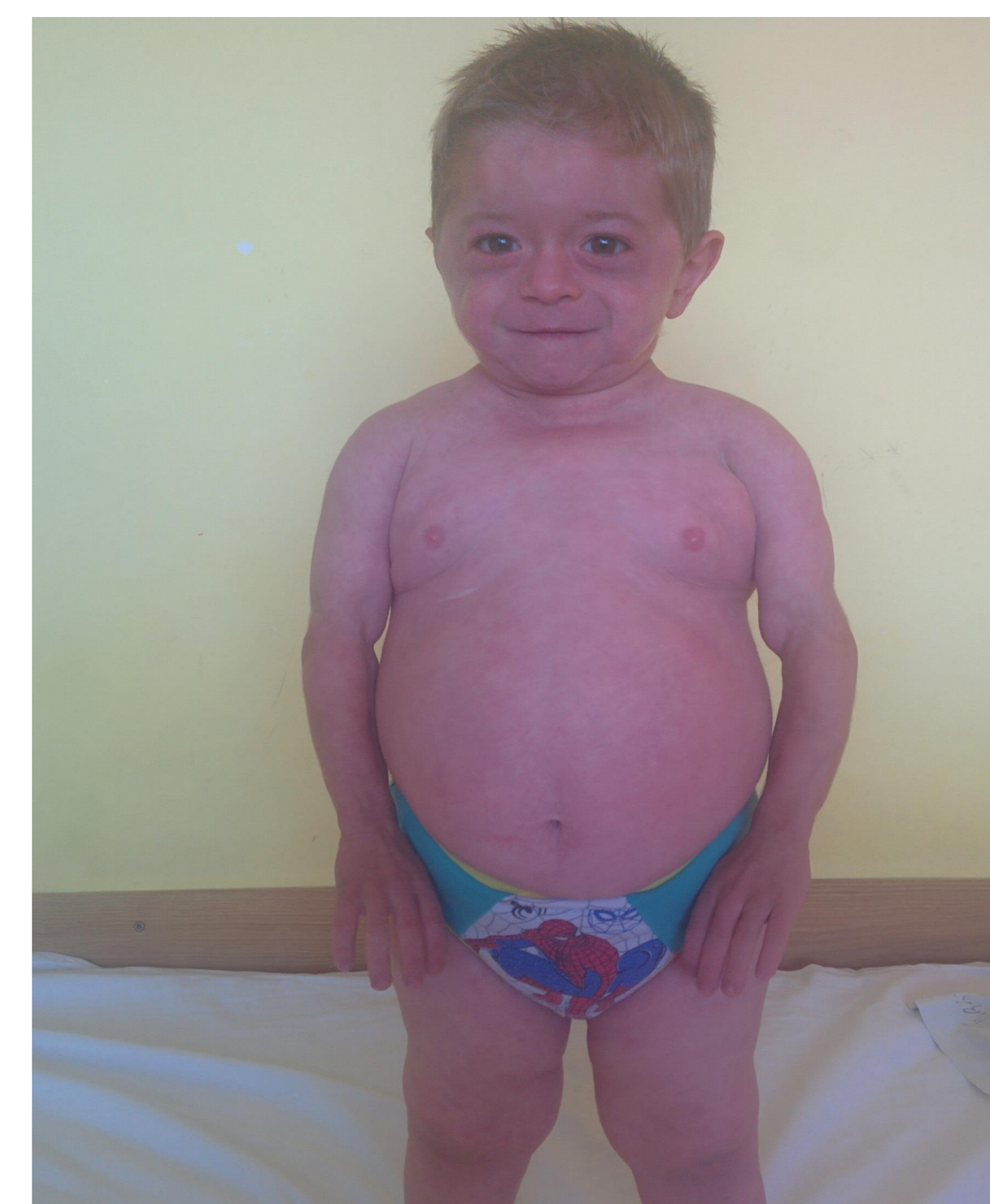Other not so common features are: clubbed fingers, hepatomegaly and splenomegaly, hypertrichosis, acanthosis, alopecia areata, hypertension, basal ganglia calcification

## Conclusions

Patients with CANDLE syndrome present as complex clinical cases and often remain undiagnosed for years.

Various anti-rheumatic and immunosuppressive drugs either have no effect or result in transient clinical improvement.

Preliminary data in 11 CANDLE patients treated with JAK-inhibitor are encouraging and suggest that targeting IFN signaling with a JAK1/JAK2 inhibitor may be a successful therapeutic strategy for CANDLE patients.



4 years old, already with Cushingoid appearance

## References

1. Brehm A., Liu Y., Sheikh A. et al. - Additive loss-of-function proteasome subunit mutations in CANDLE/PRAAS patients promote type I IFN production
2. Liu Y., Ramot Y., Torrelo A. et al. - Mutations in Proteasome Subunit beta Type 8 Cause Chronic Atypical Neutrophilic Dermatitis With Lipodystrophy and Elevated Temperature With Evidence of Genetic and Phenotypic Heterogeneity
3. Gomes. A - Genetics of Proteasome Diseases
4. McDermott A., Jacks J., Kessler M. et al.- Proteasome-associated autoinflammatory syndromes: advances in pathogenesis, clinical presentations, diagnosis, and management

**Contacts:** Dr. Martin Boyadzhiev - boyadzhiev.martin@gmail.com  
Clinic of Pediatric Endocrinology, Varna, Bulgaria - detendo.varna1@gmail.com

