


45,X/46,XY chromosomal disorders of sex development. Experience from a cohort of 50 patients followed in one single institution



Costanzo Mariana, Guercio G, Geniuk N, Berensztein E, Lazzati JM, Maceiras, M, Zaidman V, Rivarola MA, Belgorosky A. Endocrinology Department, Hospital de Pediatría J.P. Garrahan



HOSPITAL DE PEDIATRÍA
"PROF. DR. JUAN P. GARRAHAN"

Autors have nothing to disclose

Introduction

Disorders of sexual development (DSD) define a group of congenital conditions in which development of chromosomal, gonadal, or anatomical sex is atypical (1-2). Karyotype is the primary root in DSD classification.

The category "Sex Chromosome DSD" includes all subjects with a sex chromosome anomaly and is a major component of DSD causes (3).

45,X/46,XY mosaicism and its variants result in a large clinical spectrum of DSD ranging from female patients with Turner's syndrome to normal appearing males. Phenotypic variability depends on many

factors including the presence of the *SRY* gene, the complexity of structural rearrangements, and the prevalence of the 45,X cell line (4)

Short stature is a well-reported feature in patients with 45,X/46,XY mosaicism as a result of *SHOX* gene haploinsufficiency in the 45,X cell line (5).

In these patients, the presence of some specific regions on the Y chromosome increases the risk for the development of gonadal malignant germ cell tumors that appear to be negatively correlated with the degree of virilisation (6)

AIM

The main aim of this study is to review the clinical and gonadal histological findings in a cohort of chromosomal DSD patients followed at one single institution

Clinical Material

We analyzed the clinical records of 50 sex chromosome DSD patients (karyotype 45,X/46,XY or variants) evaluated between January 1/2000 and January 1/2016 at the Endocrine Department, Hospital de Pediatría "J.P. Garrahan".

Cytogenetic study was performed on peripheral blood lymphocytes using the G-banding technique, in at least 30 metaphases.

Patients were divided according to external genitalia into 2 groups (Gr):

Gr1: normal female phenotype (Turner's syndrome, n 18)

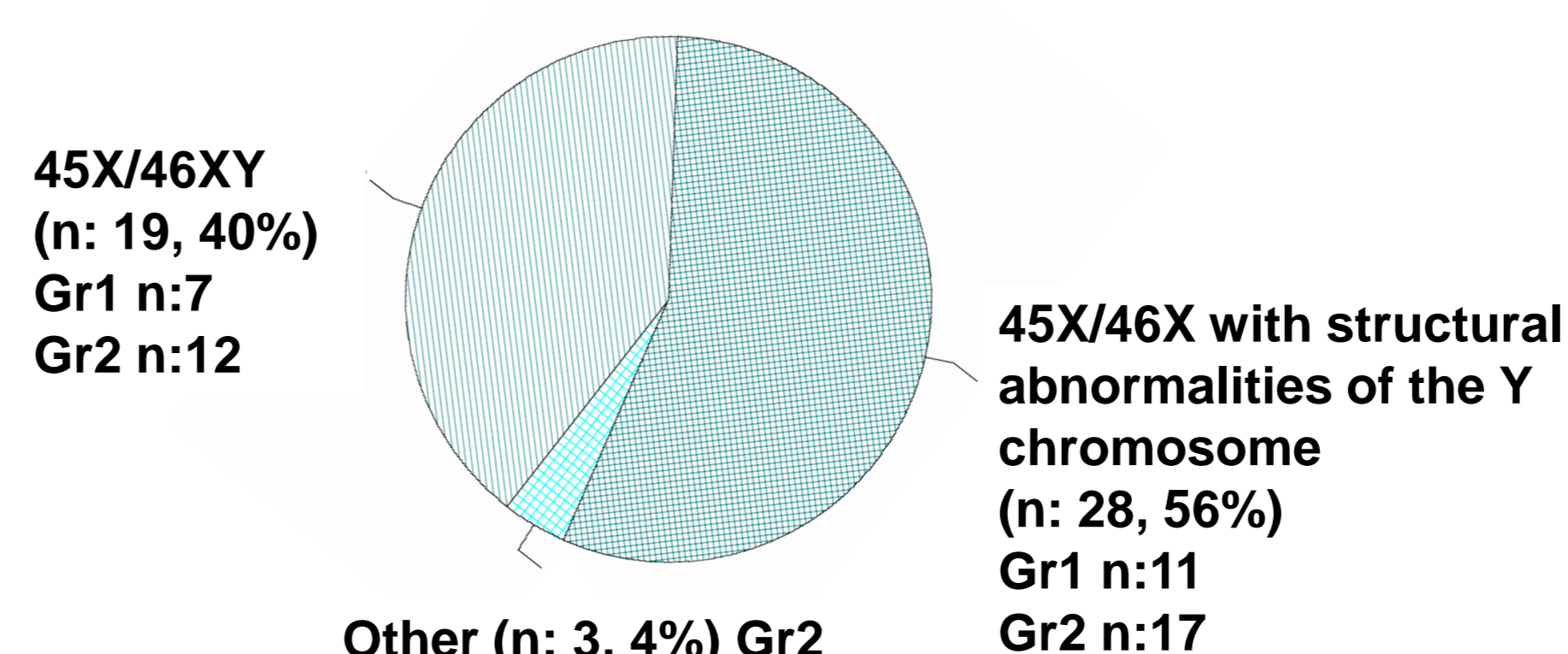
Gr2: atypical genitalia (n 32). Sex assignment: 10 Female / 22 Male.

Spontaneous pubertal development was observed in all the male assigned patients that have reached pubertal years (n:9). None of them required testosterone replacement.

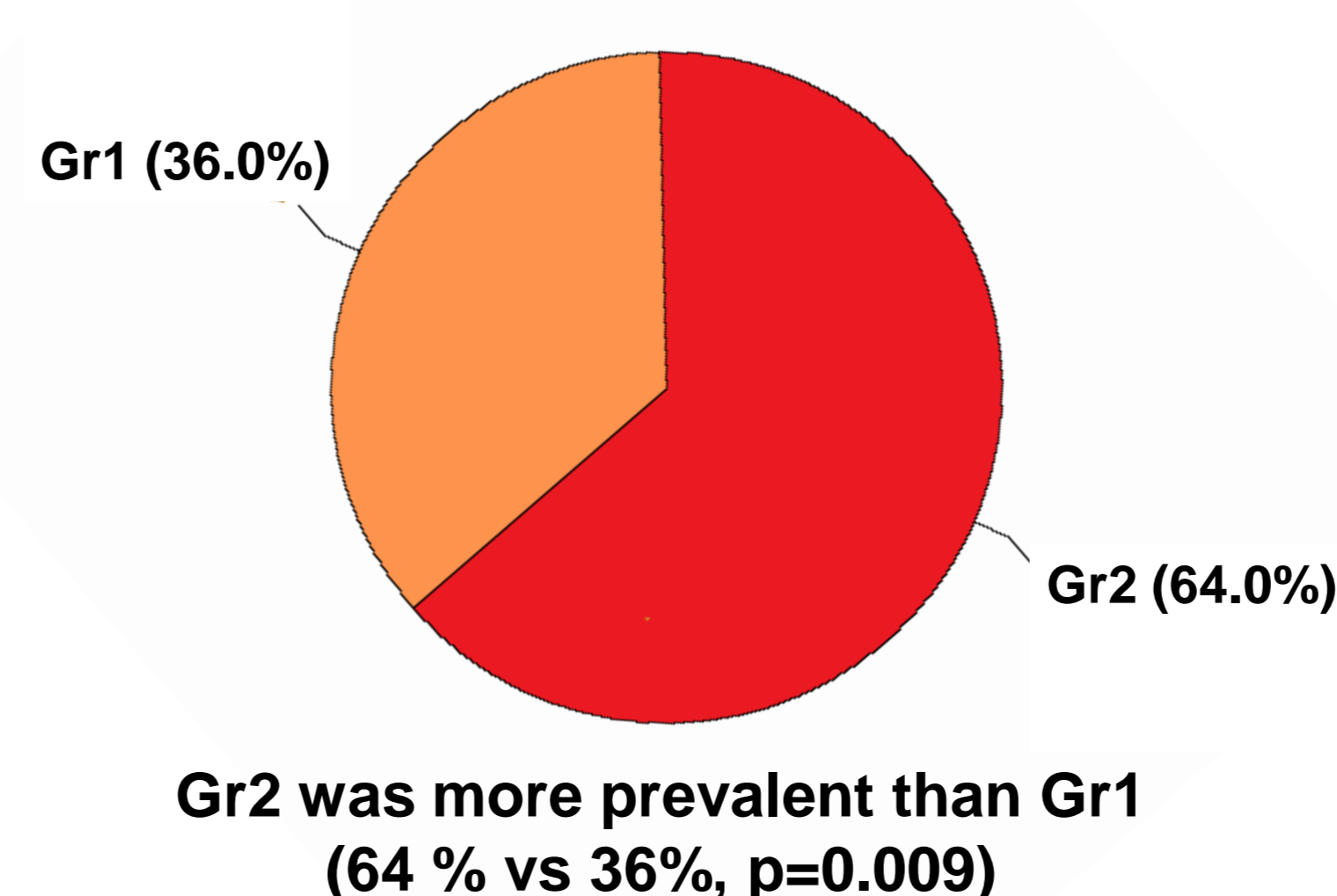
We also identified one patient with normal male phenotype evaluated because of short stature that was not included in the analysis.

Bilateral gonadectomy was performed in every patient from Gr1 and all the female assigned patients from Gr2. Bilateral biopsy was requested at diagnosis in all the male assigned patients from Gr2 but, at present, data is available for the histological analysis from 32 gonads.

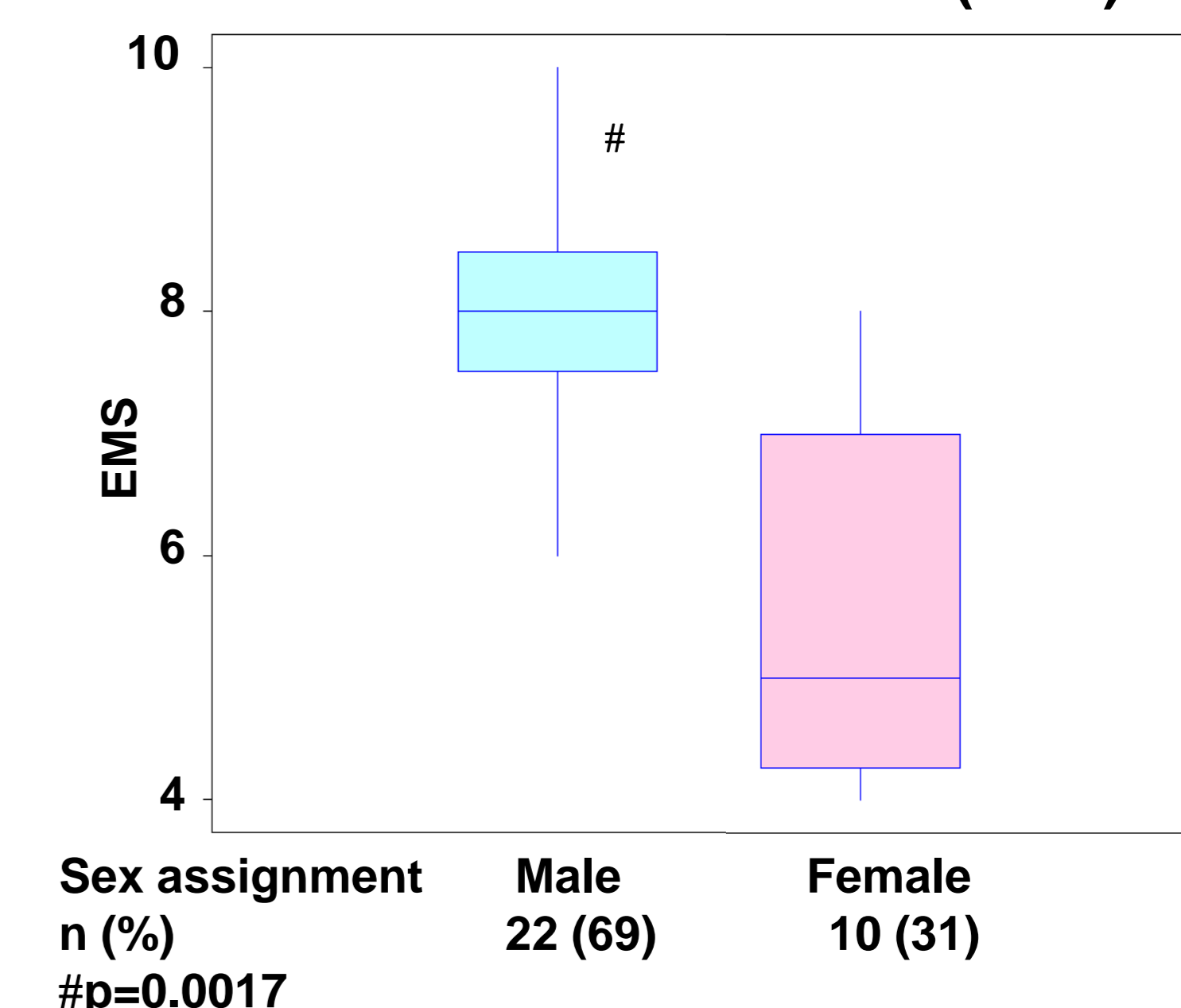
Karyotype distribution



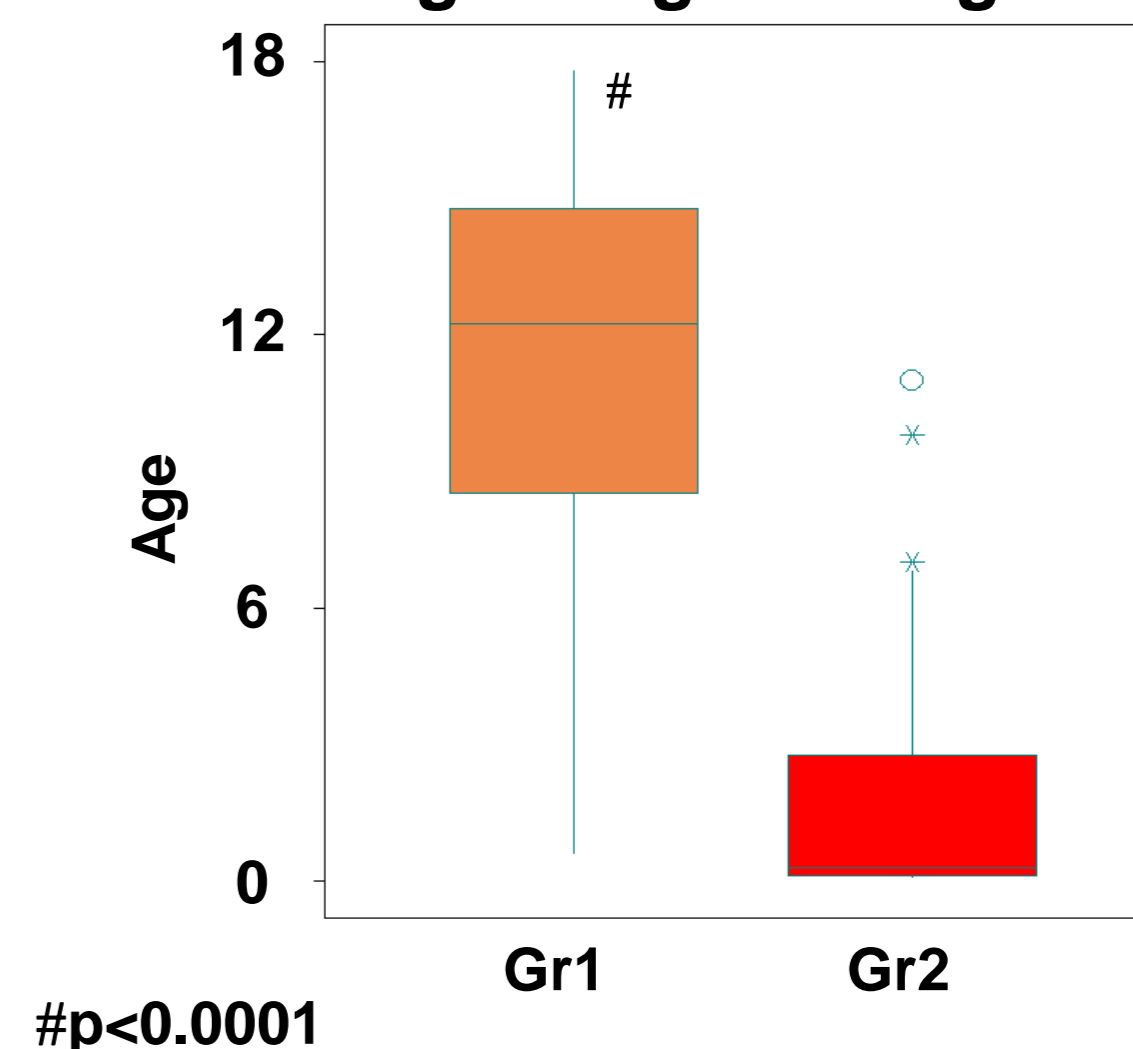
Distribution according to phenotype



External Masculinisation Score (EMS) in Gr2

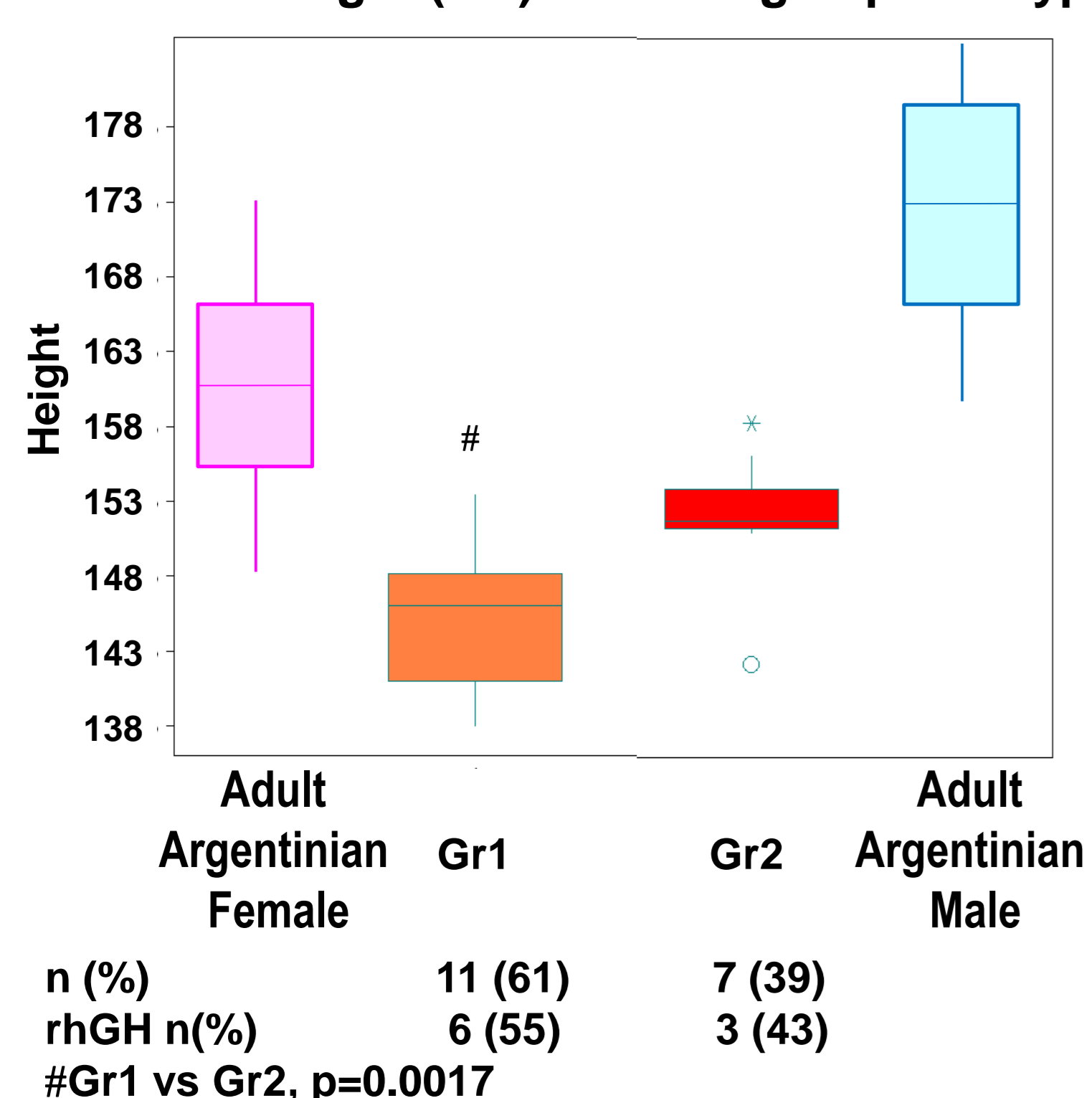


Chronological age at diagnosis (years)



Results

Adult height (cm) according to phenotype



Gonadal Histology according to phenotype

Gonadal histology: n (%)	Gr 1		Gr 2		Total
	Female	Male	Female	Male	
Testicular dysgenesis	2 (6) *	8 (40)	22 (69)	30 (58)	
Ovotestes	-	2 (10)	-	2 (4)	
Ovarian tissue	-	1 (5)	1 (3)	2 (4)	
Streak	27 (79) *	7 (35)	9 (28)	16 (31)	
Neoplasia	5 (15)	2 (10)	-	2 (4)	

*Gr1 vs Gr2, p <0.0001

Gonadal histology in Gr2 patients with ovotesticular DSD (n 3)

Female	Gonadectomy at 1.6 years. Right ovotestes and ovarian tissue with primordial follicles in the left gonad
Female	Gonadectomy at 7 months. Right testicular dysgenesis and left ovotestes
Male	Right gonadectomy: ovarian tissue with primordial follicles. Left gonadal biopsy: testicular dysgenesis

Gonadal Neoplasia according to phenotype

Gr	Gonadal Neoplasia n (%)	Case
1	5 (15%)	Case 1: Prophylactic gonadectomy at 6 years of age revealed gonadoblastoma and dysgerminoma in the left gonad. Case 2: At the age of 15 years, virilization and bilateral aneural tumors lead to the diagnosis of Turner syndrome with bilateral gonadoblastoma-dysgerminoma-embryonal carcinoma Case 3: Prophylactic gonadectomy at 17.9 years of age revealed bilateral gonadoblastoma.
2	2 (4%)	Case 4: Prophylactic gonadectomy at 3 years of age revealed bilateral gonadoblastoma

Discussion

In our cohort of 45,X/46,XY chromosomal DSD patients atypical genitalia was the most frequent phenotype.

Even though a great variability in the gonadal histological findings was observed (probably related to different genetic balance in the mosaic gonad), all the male assigned patients that reached puberty presented preserved interstitial testicular function. A trend towards a higher gonadal malignancy risk was observed in Turner's syndrome patients and those less virilised from Gr2.

Short stature is a relevant problem to be addressed in the care of these population of patients

References

- Hughes IA, Houk C, Ahmed SF, Lee PA; LWPES1/ESPE2 Consensus Group. Consensus statement on management of intersex disorders. Arch Dis Child. 2006;91:554-62.
- Lee P, Nordenström A, Houk CP, Ahmed SF. Global Disorders of Sex Development Update since 2006: Perceptions, Approach and Care. Horm Res Paediatr. 2016
- Hughes IA. Disorders of sex development: a new definition and classification. Best Pract Res Clin Endocrinol Metab 2008;22: 119-134
- Kamel AK, El-Ghany HM, et al. Sex Chromosome Mosaicism in the Gonads of DSD Patients: A Karyotype/Phenotype Correlation. Sex Dev 2015; 9:279-288
- Fukami M, Seki A, Ogata T. *SHOX* Haploinsufficiency as a Cause of Syndromic and Nonsyndromic Short Stature. Mol Syndromol 2016;7:3-11
- Cools M, Pleskacova J., et al. Gonadal Pathology and Tumor Risk in Relation to Clinical Characteristics in Patients with 45,X/46,XY Mosaicism. J Clin Endocrinol Metab 2011; 96: E1171-E1180

