

Intratubular Large Cell Hyalinizing Sertoli Cell Tumor of the Testis Presenting with Prepubertal Gynecomastia: A Case Report

Hale Tuhan¹, Ayhan Abaci¹, Banu Sarsik², Tülay Öztürk³, Mustafa Olguner⁴, Gonul Catli¹, Ahmet Anik¹, Nur Olgun⁵, Ece Bober¹

¹ Department of Pediatric Endocrinology, Dokuz Eylul University Faculty of Medicine, Izmir, Turkey

² Department of Pathology, Ege University Faculty of Medicine, Izmir, Turkey.

³ Department of Pediatric Radiology, Dokuz Eylul University Faculty of Medicine, Izmir, Turkey

⁴ Department of Pediatric Surgery, Dokuz Eylul University Faculty of Medicine, Balçova, Izmir, Turkey.

⁵ Department of Pediatric Oncology, Dokuz Eylul University Faculty of Medicine, Izmir, Turkey.

Background

Sertoli cell tumors (SCTs) are rarely seen tumors and account for approximately 0.4-1.5% of all testicular tumors. SCT has many sub-types. One of the sub-types of SCT characterized by multifocal intratubular large hyalinizing Sertoli cells with or without associated calcification is called as intratubular large cell hyalinizing Sertoli cell neoplasia (ITLCHSCN).

Aim

We describe a patient with gynecomastia who was diagnosed with ITLCHSCN after testis biopsy and treated with anastrozole, an aromatase inhibitor.

Case Report

A six-and-a-half-year old male presented with complaint of pain, induration and enlargement of his breasts for three months.

History of trauma (-) known disease (-) drug use (-)

He was the first child of non-consanguineous parents.

On physical examination;

Weight was 28 kg (0.25 SDS)

Height was 130 cm (0.14 SDS)

Pubic hair: Tanner stage 1 with no axillary hair

Testicular volume was 6 mL bilaterally

Penile length was 7.8 cm

Clinical Progress

Clinic, radiologic and laboratory parameters of the patient were shown on the table 1. At scrotal sonography, the testicular volumes were measured to be 1.4 cc in the right testis and 1.2 cc in the left testis. It also showed hyperechogenicity consistent with testicular microlithiasis in bilateral testes. An increase in the size of his gynecomastia was detected during two years of follow-up. Annual growth velocity was determined to be 7.1 cm/year (2.1 SDS). Due to determination of increase in growth velocity, advanced bone age and progression in gynecomastia during two-years of follow-up, a testicular biopsy was performed by pediatrics surgery due to suspicion of malignancy. Pathological examination was reported to be consistent with ITLCHSCN (Figure 1). To reduce gynecomastia and growth velocity, and to delay skeletal maturation Anastrozole treatment [an aromatase inhibitor (1x1mg, peroral)], was started to the patient. After 12 months, growth velocity and gynecomastia decreased.

Table 1. Clinic, radiologic and laboratory parameters of the patient

Parameter	Before Treatment			After Treatment
	6.5	7.5	8.5	9.5
Chronologic Age (year)	6.5	7.5	8.5	9.5
Physical Examination				
Weight	21.8 kg (-0.05 SDS)	23 kg (-0.08 SDS)	28 kg (+0.27 SDS)	29 kg (-0.26 SDS)
Height	118 cm (-0.10 SDS)	123 cm (-0.07 SDS)	130.5 cm (+0.14 SDS)	135 cm (-0.27 SDS)
Testicular volume (R/L)	6 mL/6 mL	6 mL/8mL	6 mL/8 mL	6 mL/8 mL
Gynecomastia	+/+	+/+ (Stable)	+/+ diameter and volume ↑	+/+ diameter and volume ↓
Laboratory evaluation				
FSH (mIU/mL)	<0.05	<0.05	<0.02	0.2
LH (mIU/mL)	0.02	0.02	1.76	2.57
E2 (pg/mL)	<10	<20	<20	<20
T.Testosterone (ng/dL)	<20	<0.08	<0.1	<0.1
AFP (ng/mL)	1.99			
hCG	<0.1			
PRL (ng/mL)	4.3			
E1 (pg/mL)			<10	
SHBG (nmol/L)			73.5	
AS (ng/mL)	0.93			
DHEAS (ug/dL)	6.7			
Radiological Evaluation				
Bone Age (year)	6	7	9	9.5

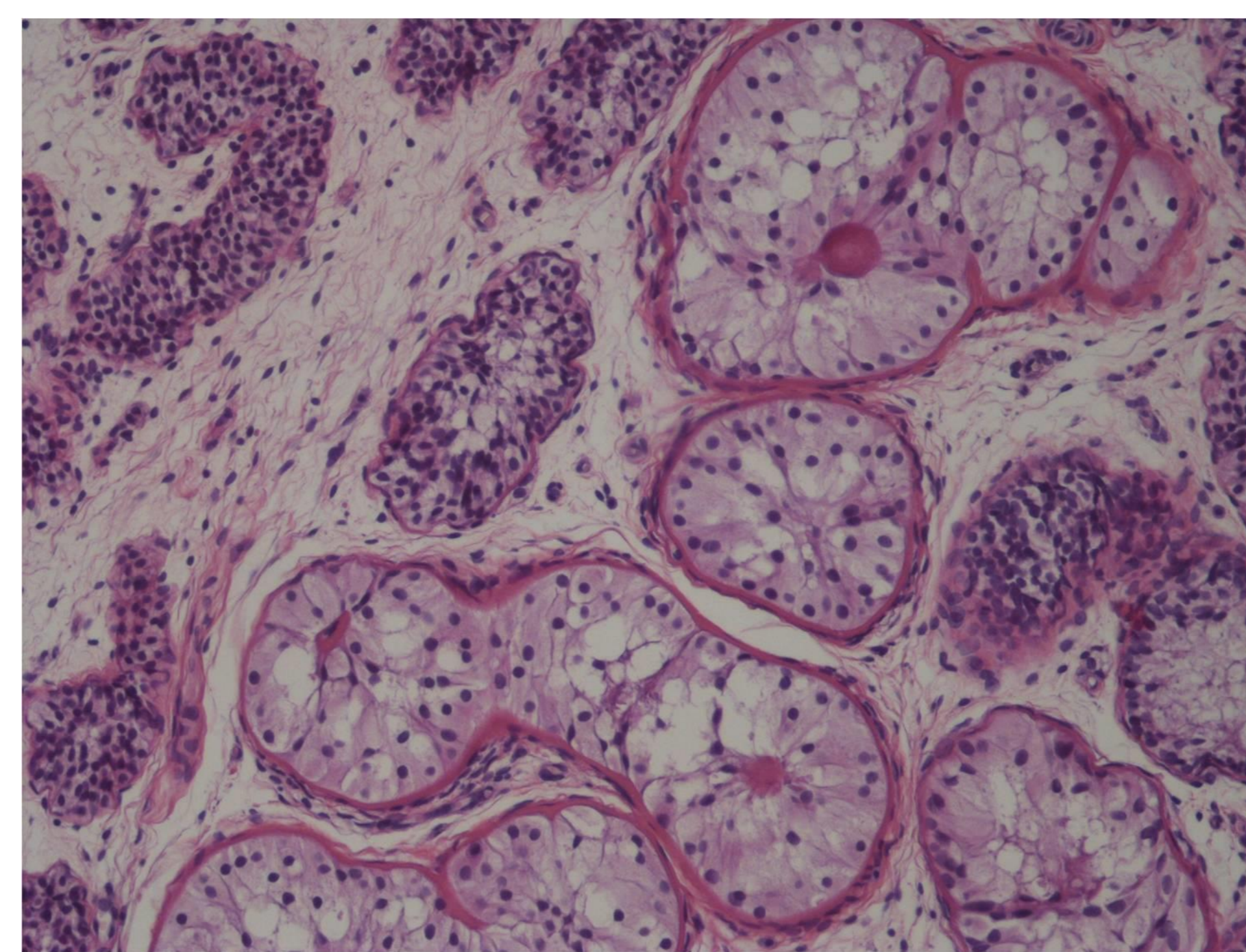


Figure 1. The neoplastic seminiferous tubules were filled by large Sertoli cells with eosinophilic cytoplasm and uniform oval nuclei (HE; X200)

Discussion

- It should be kept in mind that clinical follow-up, radiological and histopathological findings play an important role during the diagnostic period of SCTs.
- Progression of gynecomastia in a boy with increase in growth velocity, advanced bone age, increase in testicular volume as well as presence of microlithiasis in the testicles should suggest SCTs.
- Aromatase inhibitors, particularly anastrozole, provide a benefit to patients with SCTs.

