

Özlem Korkmaz<sup>1</sup>, Samim Özen<sup>1</sup>, Nurhan Özcan<sup>1</sup>, Petek Bayındır<sup>2</sup>, Sait Şen<sup>3</sup>, Hüseyin Onay<sup>4</sup>, Damla Gökşen<sup>1</sup>, Ali Avanoğlu<sup>5</sup>,  
Ferda Ozkınay<sup>4</sup>, Şükran Darcan<sup>1</sup>

<sup>1</sup>Ege University School of Medicine, Department of Pediatric Endocrinology and Diabetes, Izmir

<sup>2</sup>Ege University School of Medicine, Department of Radiology, Izmir

<sup>3</sup>Ege University School of Medicine, Department of Pathology, Izmir

<sup>4</sup>Ege University School of Medicine, Department of Genetics, Izmir

<sup>5</sup>Ege University School of Medicine, Department of Pediatric Surgery, Izmir

- Persistent Müllerian duct syndrome occurs due to anti-Müllerian hormone (AMH) deficiency or AMH receptor resistance.
- While the external genital structure is a normal virilized male, fallopian tubes and a uterus are observed in the internal genital structure

**Case :** 13 months old male

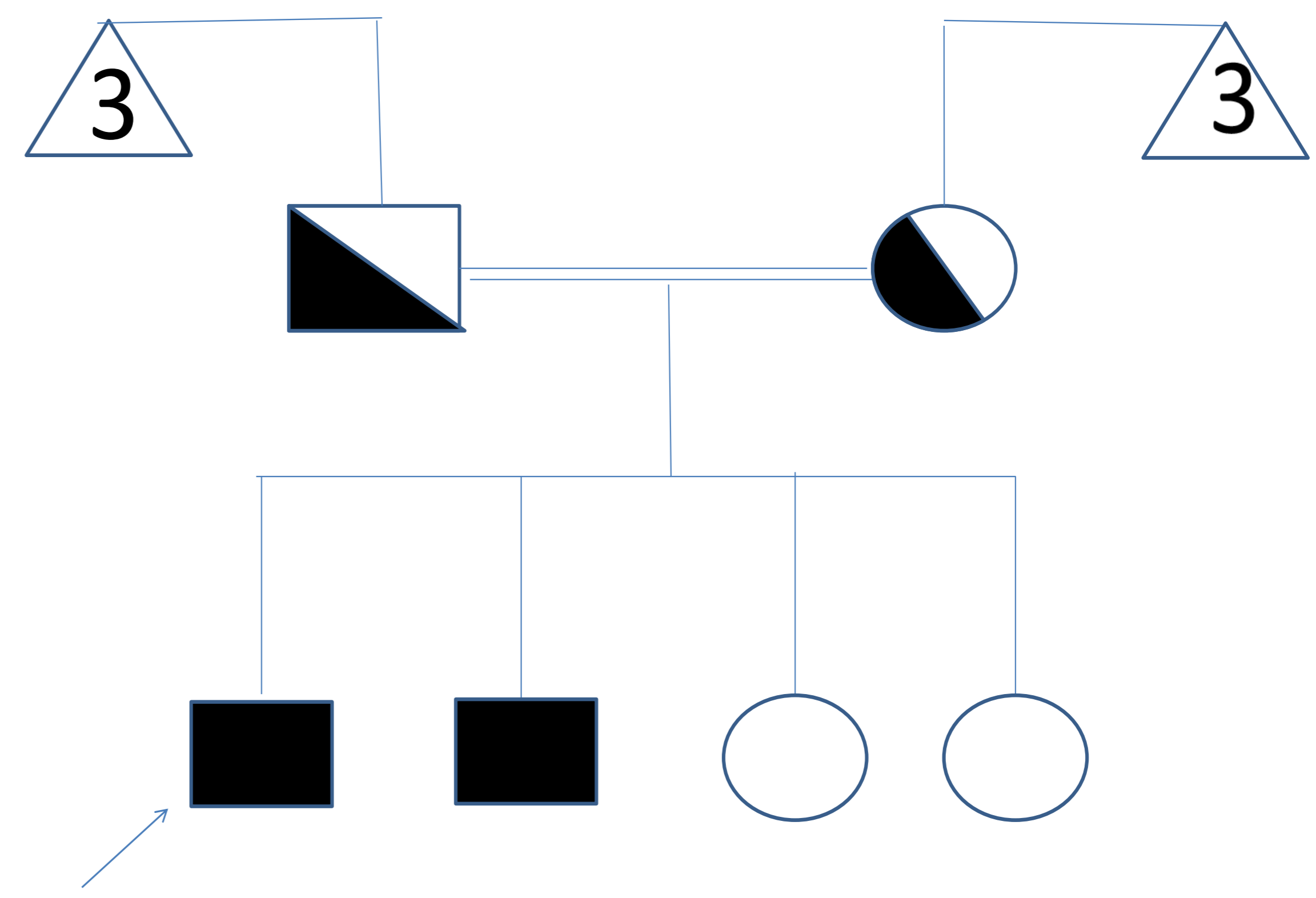
- Bilateral undescended testis: Department of Pediatric Surgery
- The mother and father were first-degree relatives

**Physical examination:** Tubular structure (testis/testes?) was palpated within the canal

**Ultrasonography:** On the right, two structures thought to be testes 12x8 mm and 11x7 mm in size were found in the proximal and middle part of the inguinal canal and were interpreted as transverse testicular ectopia.

**Laparoscopy:** Ectopic testis, tissues suggestive of a uterus, fallopian structures and ovaries were observed inside the abdomen

## Pedigree



## Physical examination:

Weight: 10.2 kg (SDS:-1.06), height: 81 cm (SDS:-0.39) BP: 98/60 mm/Hg, Prader stage 5, phallus 3.5 cm, bilateral unpalpable testis

## Laboratory examination:

FSH: 0.44 mIU/l (0.26-3)

LH: 0.27 mIU/l (0.02-0.3)

Free testosterone: 0.3 pg/ml (0.15-0.6)

Total testosterone: 0.1 ng/dl (0.2-1.3)

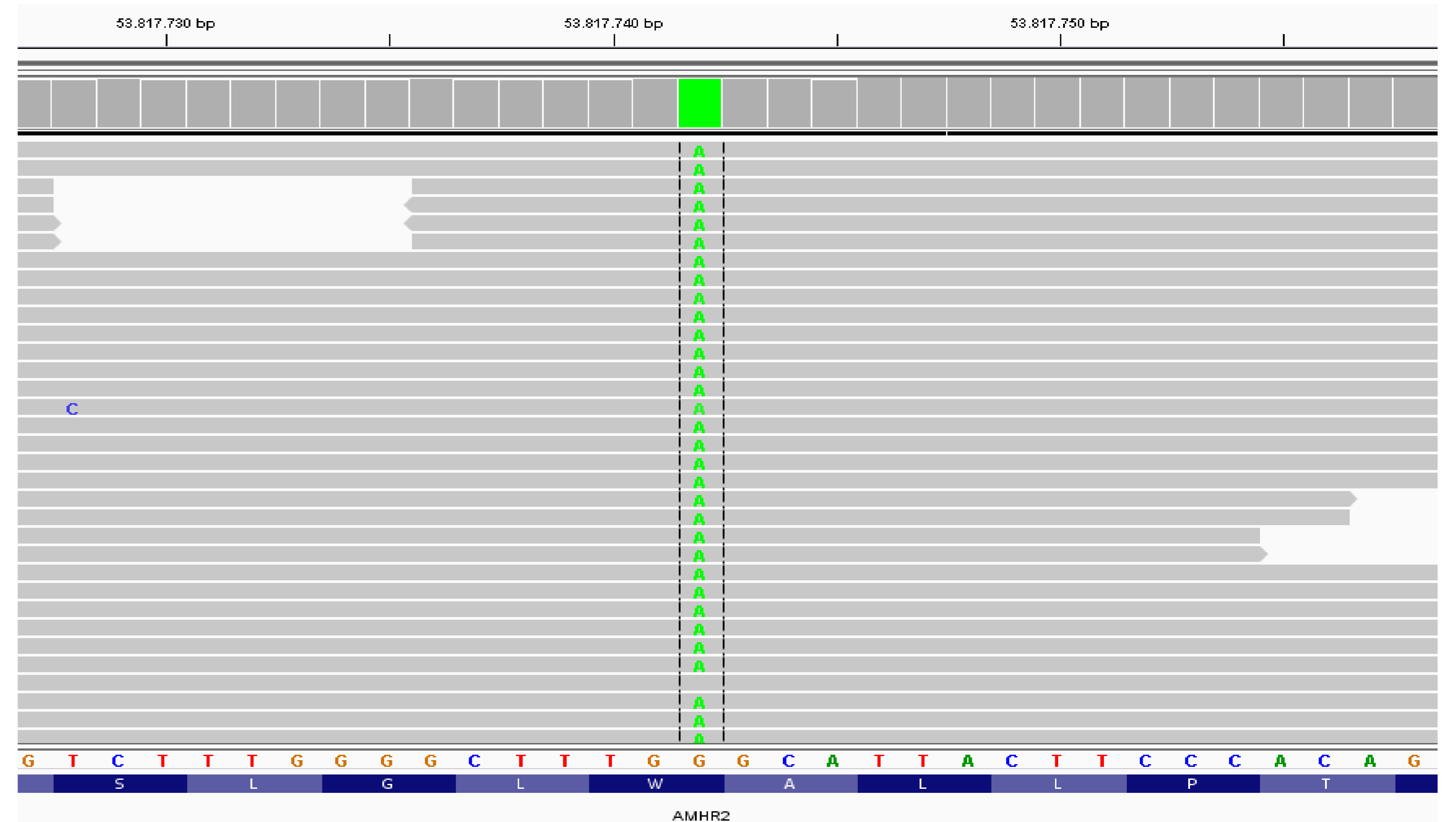
E2:<20 ng/ml (<15)

**AMH:> 22 ng/ml**

QF-PCR: XY, SRY(+)

Karyotype analysis 46XY

**Gonad biopsy:** Immature seminiferous tubular structures were observed



AMHR2 gene sequence analysis revealed a homozygous c.24G>A ( p.W8X) mutation of AMH receptor which was previously undescribed. The parents had the same mutation in heterozygous form. The case was discussed at the sex development disorder council, and orchiopexy was performed.

AMH receptor defect is a rare cause of 46 XY sex development disorder. The condition should be considered when persistent Mullerian structures are observed, particularly in virilized males with a normal external genital.