

## Background

Klinefelter's syndrome (KS) is the most prevalent chromosomal abnormality and clinically characterized by oligo-azospermia, hypergonadotropic hypogonadism, gynecomastia and infertility in adults.

Genital malformations in Klinefelter's syndrome have rarely been reported.. While external genital structures are expected to be normal at birth in patients with Klinefelter syndrome, genital malformations of varying severity have rarely been reported.

## Cases

A 14-month-old male was first referred to our department due to penoscrotal malformation.

### ❖ Physical examination ;

- Height 82 cm (SD score 1.50),
- Weight 16.2 kg(SD score 3.4),
- Penoscrotal hypospadias, and ventral chordee abnormality with bilateral normal testes (2/2 ml).
- Stretched penile length was 2.6 cm (<-2 SDS).

### ❖ Laboratory studies;

- Normal biochemistry and thyroid function test
- FSH 1,37 mIU/mL (normal: 0,3-4,6 mIU/mL)
- LH<0,2 mIU/mL (normal: 0,04-0,42 mIU/mL)
- Total testosterone<0,1 ng/mL (normal >0,2 ng/ml)
- 17-hydroxyprogesterone <0.3 ng/ml (normal <1.8 ng/ml),
- Androstenedione <0.3 ng/mL (normal <0.9 ng/ml).

### ❖ Pelvic ultrasonography revealed no ovarian and uterine tissue.

### ❖ Following three days of human chorionic gonadotropin administration (1000 U/day) total testosterone increased to 1.32 ng/mL, indicating normal androgen synthesis.

## Methods

Peripheral blood DNA was extracted from the case. The coding exons, 5' UTR and the 3' UTR regions, and exon-intron boundaries of the *AR* gene were sequenced with MiSeq NGS system using V2 chemistry (Illumina, San Diego, CA, USA) according to the manufacturer's instructions.

## Results

- Chromosomal analysis revealed 47, XXY karyotype.
- We detected a previously reported heterozygous missense mutation in exon 1 of the *AR* gene (p.P392S, c.1174C>T)

## Figures




Figure 1. Heterozygous p.P392S mutation detected in the patient

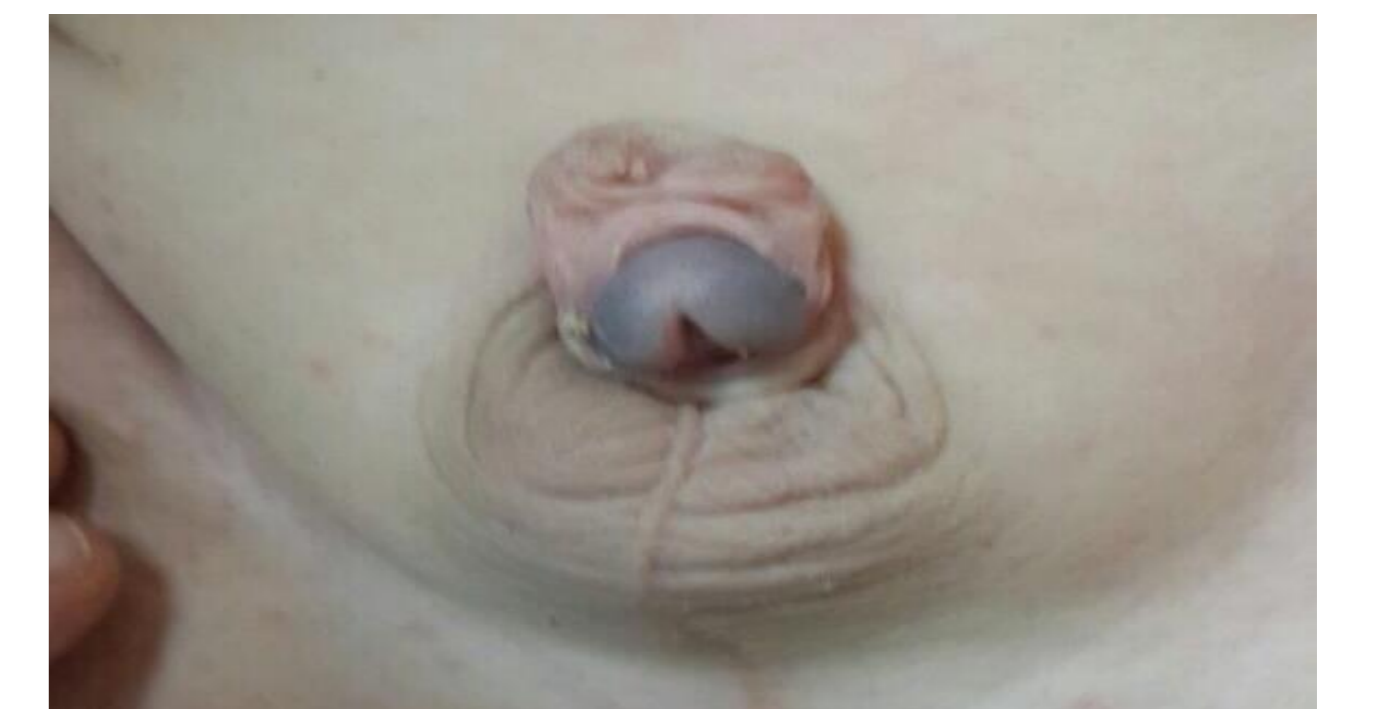

Figure 2. Penoscrotal hypospadias and ventral chordee

## Discussion

- To date, the p.P392S mutation has been described in 8 cases (4 penile hypospadias, 1 penoscrotal hypospadias, 1 isolated micropenis, and 2 isolated infertility), which indicate that this mutation, in line with current case is mostly leading a mild phenotype in patients with AIS.
- Partial androgen insensitivity syndrome (AIS) can occur in XXY when non-mutant X is inactivated or mutant allele is preferentially expressed
- The reported patients with both 47, XXY and AIS had all complete AIS phenotype to date

## Conclusion

- ✓ This is the first case with the combination of 47, XXY and PAIS phenotype described herein.
- ✓ Although KS is suggested to be considered in the differential diagnosis of penoscrotal abnormalities, the most common cause of *AR* gene mutation must be excluded in undervirilized male even in KS.

