

Lipoid congenital adrenal hyperplasia in a 30-year-old female with a tall stature

Yasunori Wada¹, Tatsuya Miyoshi², Yukihiro Hasegawa³, Shoichi Chida¹

¹Iwate Medical University, Department of Pediatrics, Iwate, Japan

²Shikoku Medical Center for Children and Adults, Division of Pediatric Endocrinology and Metabolism, Kagawa, Japan

³Tokyo Metropolitan Children's Medical Center, Endocrinology and Metabolism, Tokyo, Japan

The authors have no conflict of interest to declare



INTRODUCTION

Lipoid congenital adrenal hyperplasia (LCAH) is an autosomal recessive adrenal and gonadal steroidogenesis disorder usually caused by a genetic abnormality in the *STAR* gene encoding the steroidogenic acute regulatory protein (StAR). LCAH is the most severe form, characterized by severe defects in the adrenal and the gonadal conversion of cholesterol to pregnenolone, the precursor of all steroids. For 46, XY cases, sex steroid hormone replacement therapy must be initiated together with glucocorticoid and mineralocorticoid treatment. Adult cases, perhaps due to steroid hormone therapy, appear to be short stature. LCAH presenting with tall stature has not been reported thus far.

OBJECTIVES

We present the case of a 30-year-old woman with a tall stature and 46, XY lipoid congenital adrenal hyperplasia.

PATIENT AND METHODS

A 30-year old female complaining of tall stature was referred to a pediatric endocrinology clinic. A second child of non consanguineous parents, she was born at full term via normal delivery and weighed 4000 g. The baby presented with normal female external genitalia, including the absence of gonads in the labial folds. She had hyperpigmented areolas, labia majora, and skin.

She experienced spasms due to low plasma glucose levels 24 hours after birth, with sodium levels of 139 mEq/L. Although a chromosome study revealed a 46, XY pattern, she was determined to be female because of female-type external genitalia.

At 2 months of age, an ACTH-Z loading test revealed no reaction with 17-hydroxycorticosteroid (OHCS) and 17-ketosteroid (KS). Therefore, the patient was diagnosed with LCAH and began receiving corticosteroid replacement therapy. A gonadectomy was performed at 6 years of age, after which only prescribed therapy was continued. At 25 years of age, she was recommended to visit a gynecologist, but she refused because it required travelling a long distance.

When she was referred to our clinic, her height and weight were 189.5 cm and 107 kg, respectively. On physical examination, she presented with a hyperpigmented spot on her lips, Tanner stage 1 breast development, and a bone age of 12 years (Figure 1). Laboratory analysis revealed that the patient had sodium levels of 137 mEq/L and potassium levels of 4.7 mEq/L. In addition, her serum levels of adrenocorticotropic hormone (ACTH) was 6.2 pg/mL, renin was over 20 ng/mL/h, pregnenolone was <0.10 ng/mL, and deoxycorticosterone was <0.02 ng/mL. Random cortisol level was 2.3 μ g/dL. She was taking 15 mg of prednisolone as hormone replacement therapy. In addition, her luteinizing hormone level was 17.65 mIU/mL, follicle stimulating hormone was 55.77 mIU/mL, and estradiol was <5.0 pg/mL.

We identified a homozygous mutation of c.653C>T (p. A218V) at exon 6 of the *STAR* gene (Figure 2). Her parents also have a heterozygous mutation of A218V.

The ovaries and uterus could not be identified on magnetic resonance imaging. No uptake was detected on adrenocortical scintigraphy.

RESULTS

At 30 years of age, oral estrogen therapy was initiated, and 15 mg of prednisolone was replaced with 1.0 mg of dexamethasone and fludrocortisone. Meanwhile, an orthopedic physician prescribed bisphosphonate because of glucocorticoid-induced osteoporosis.

After 6 years, her height and weight were 193.5 cm and 90 kg, respectively. She presented with Tanner stage 3 breast development and Tanner stage 2 pubic hair. Closure of the epiphyseal line was confirmed, and her bone age was 17 years (Figure 3). The patient presented with a female gender identity.

Figure 1

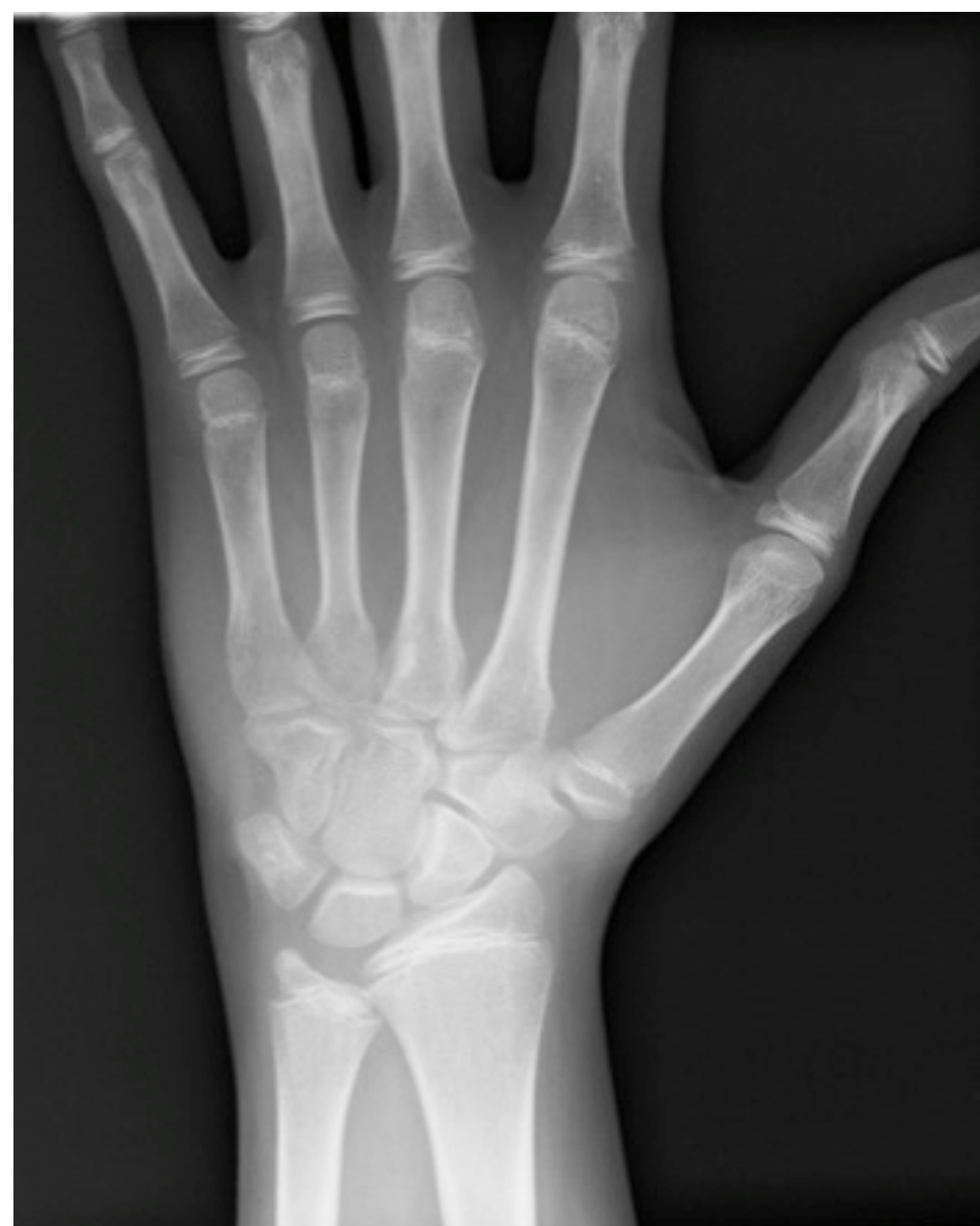

Figure 2

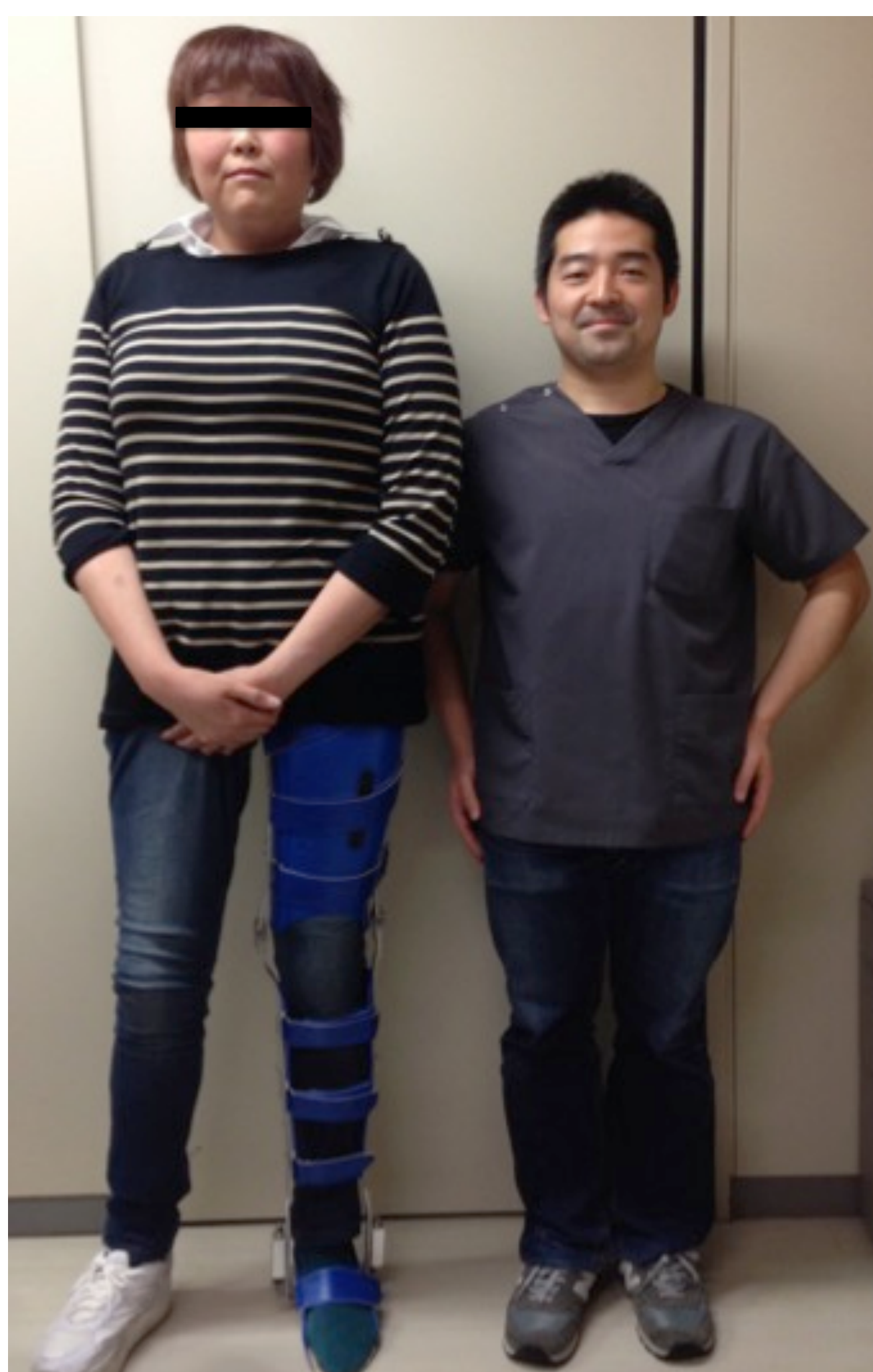
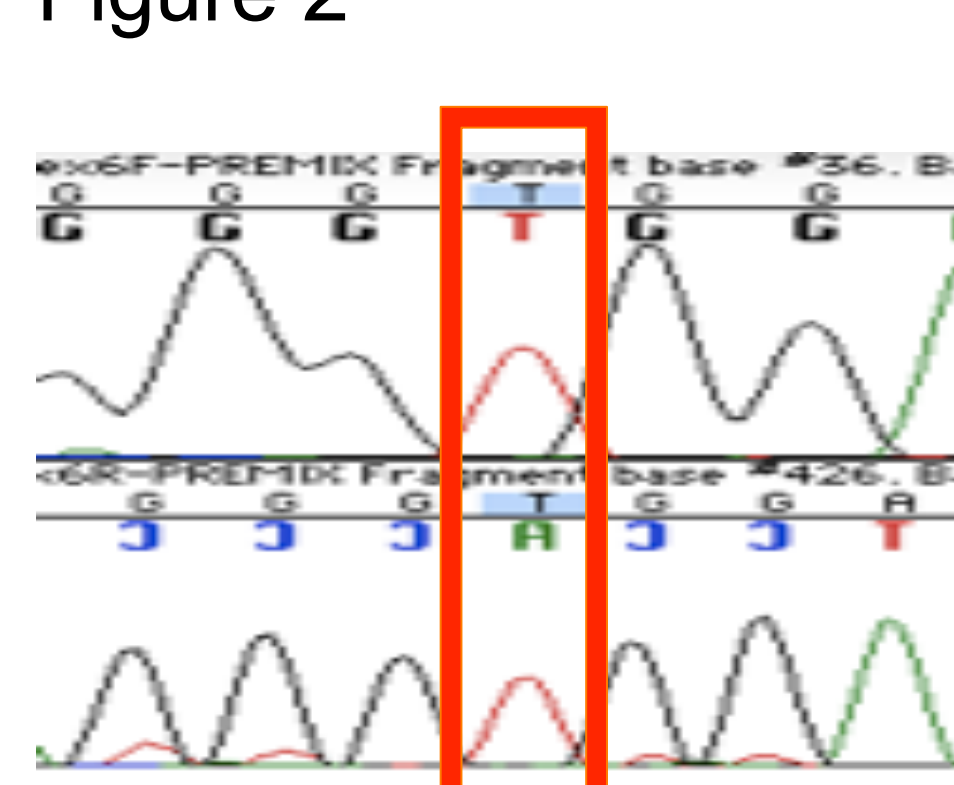
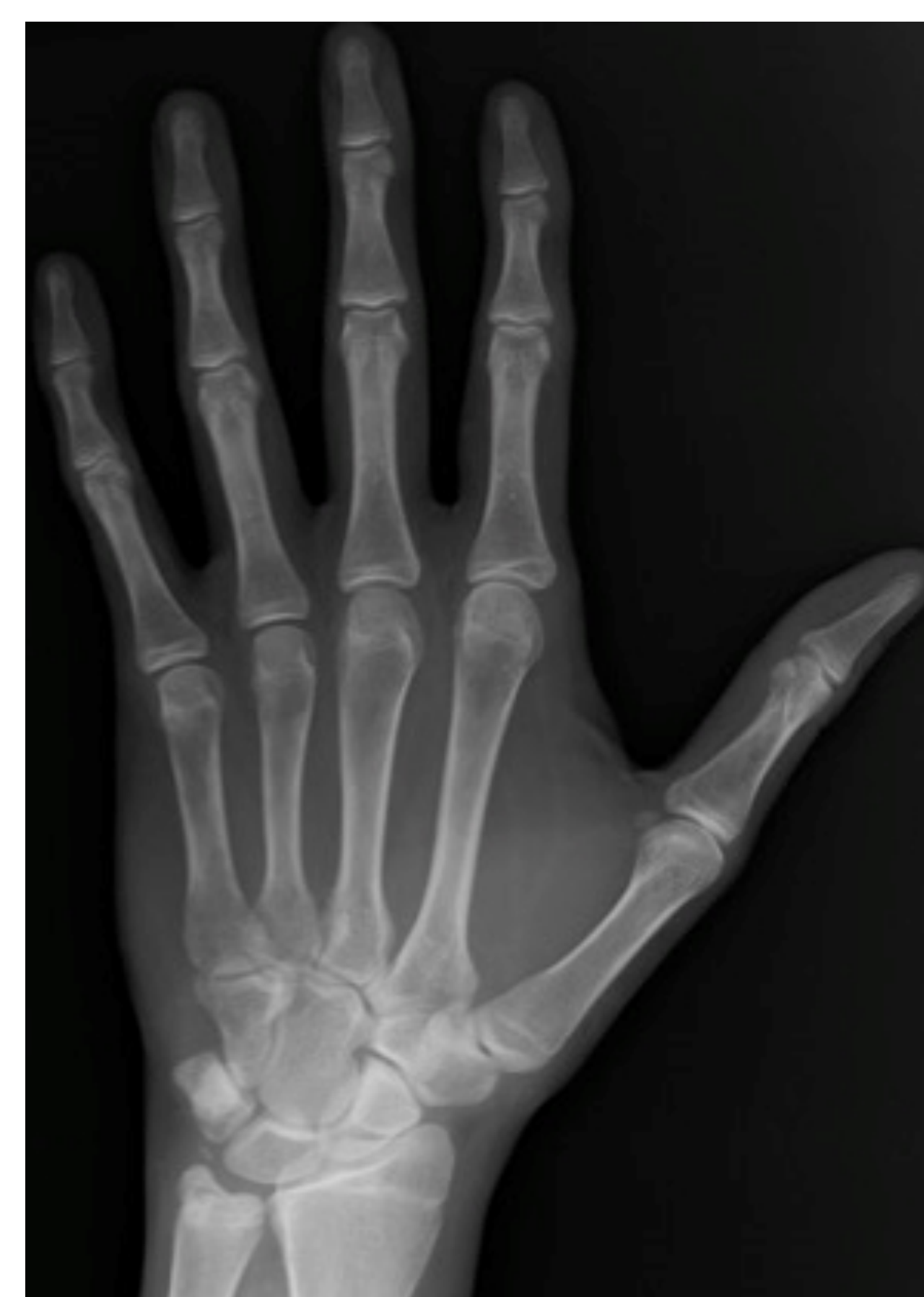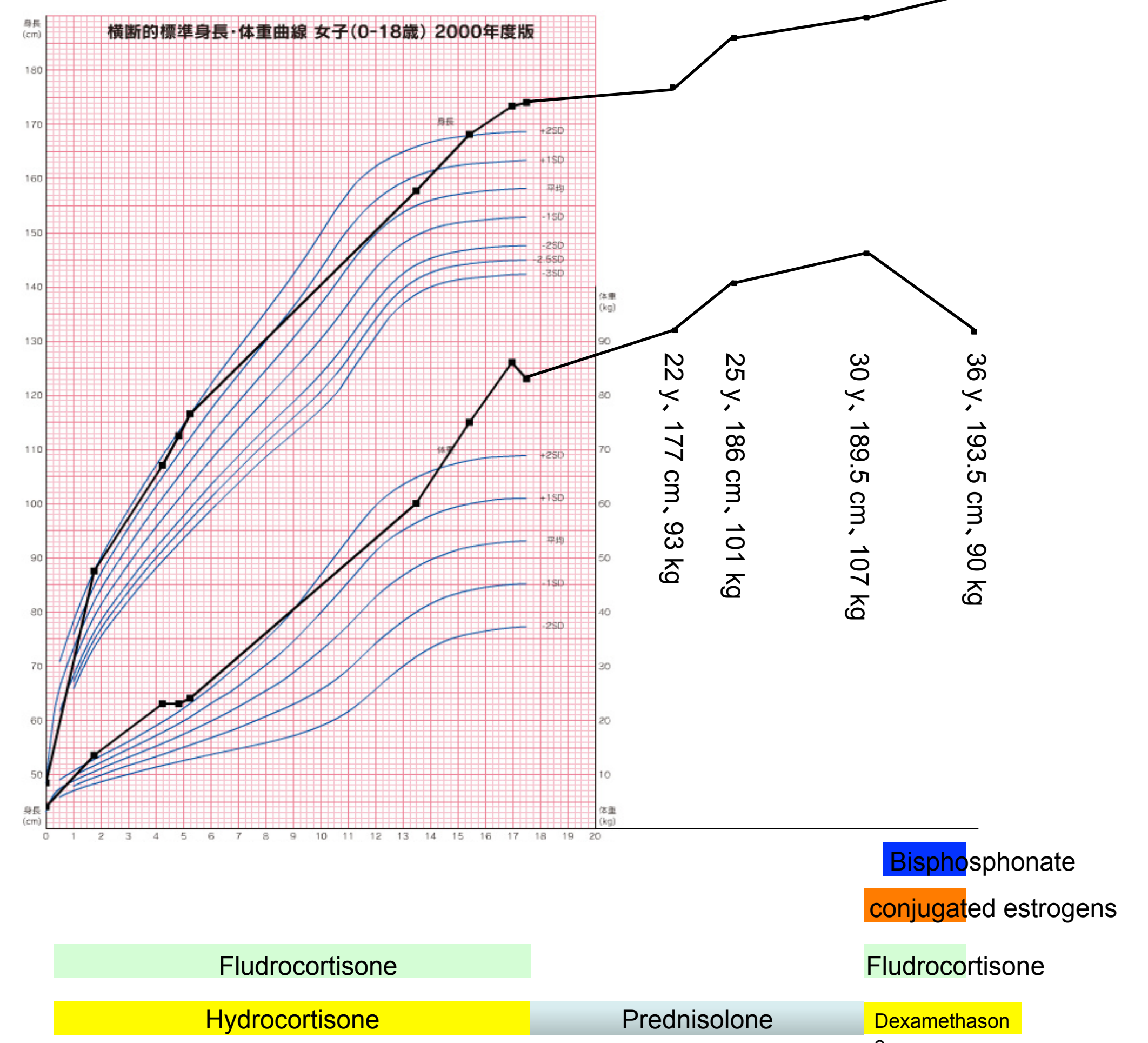


Figure 3



Growth chart



DISCUSSION

Typical adult patients with LCAH present with short stature¹. In this case, the patient presented with a previously reported² homozygous mutation of A218V and decreased expression of StAR due to a splicing mutation³. While cases of tall stature have been reported with untreated hypopituitarism and hypogonadism⁴⁻⁵, reports of LCAH cases associated with tall stature have not been described thus far.

It is necessary to initiate oestrogen replacement at an appropriate age to ensure closure of the epiphyseal line in individuals with hypogonadism. Treatment with glucocorticoids almost doubles the risk of bone fractures in patients with CAH when compared to the general population⁶. Another study speculated that a decrease in the bone mineral density of CAH patients is in part explained by the decreased height, but not by the dose of glucocorticoids⁷. Osteoporosis was attributed not only to delayed oestrogen replacement, but also to an excessive steroid dose.

References

- 1) Koh JW et al. J Korean Med Sci 2013
- 2) Nakae J et al. Hum Mol Genet, 1997
- 3) Kim J M et al. Eur Endocrinol 2011
- 4) Den Ouden DT et al. JCEM 2002
- 5) Kawamura M et al. Internal Medicine 2001
- 6) Rochira V et al. JCEM 2010
- 7) Hummel SR et al. Clin Endocrinol 2016
- 8) Ceccato F et al. Eur J Endocrinol 2016