

45,X/47,XYY chromosomal mosaicism as a cause of 46, XY Disorder of Sex Development

Ahmet Anık¹, Esmâ Tuğba Kaşıkçı¹, Suzan Şahin², Tolga Ünüvar¹, Münevver Kaynak Türkmen²

Adnan Menderes University, Faculty of Medicine, Department of

¹Pediatric Endocrinology, ²Neonatology, Aydın, Turkey

Introduction: 45,X/47,XYY mosaicism is quite rare, and, like 45,X/46,XY, it can be associated with mixed gonadal dysgenesis, Turner syndrome or apparently normal male/female phenotype.

Case Report: An infant aged 16 days, born full-term via spontaneous vaginal delivery to a 32 year-old G1P1 woman. His pregnancy and perinatal period were both uncomplicated except for maternal long QT syndrome. There was third degree cousin consanguinity between the parents. There was no any virilizing drug use and no maternal virilization during pregnancy.

Physical examination was normal except for genital examination which revealed a 3.3 cm phallic structure, with an opening on its ventral side. The labia majora were posteriorly fused and rugated, and gonads were 1 ml and palpable bilaterally (Figure 1). His height was 56 cm, weight 4600 g, and head circumference 37 cm. His pulse rate was 120/min and blood pressure 80/50 mmHg.

Laboratory examination showed normal gonadotropin levels consistent with mini-puberty as follicle stimulating hormone (FSH): 3.9 mIU/ml (N, 1.37-13.5), luteinizing hormone (LH): 6.2 mIU/ml (1.14-8.75) and total testosterone: 1.8 nmol/L. His serum adrenal androgens were in normal range [androstenedione: 25.9 ng/dL (Normal, 5-45 ng/dL), 17-OH progesterone: 5.1 ng/mL (Normal, <10 ng/mL)]. There was no müllerian structure on pelvic ultrasonography. Chromosome analysis from peripheral blood cells revealed 45,X/47,XYY (80%-20%, respectively) karyotype. Fluorescence In Situ Hybridization (FISH) revealed a similar karyotype as 45,X (77%)/47,XYY (223%) in 200 cell (Figure 2).

Because of the 45,X/47,XYY karyotype, the patient was evaluated for Turner syndrome features and no any abnormalities could not be demonstrated. The patient was reared as male.

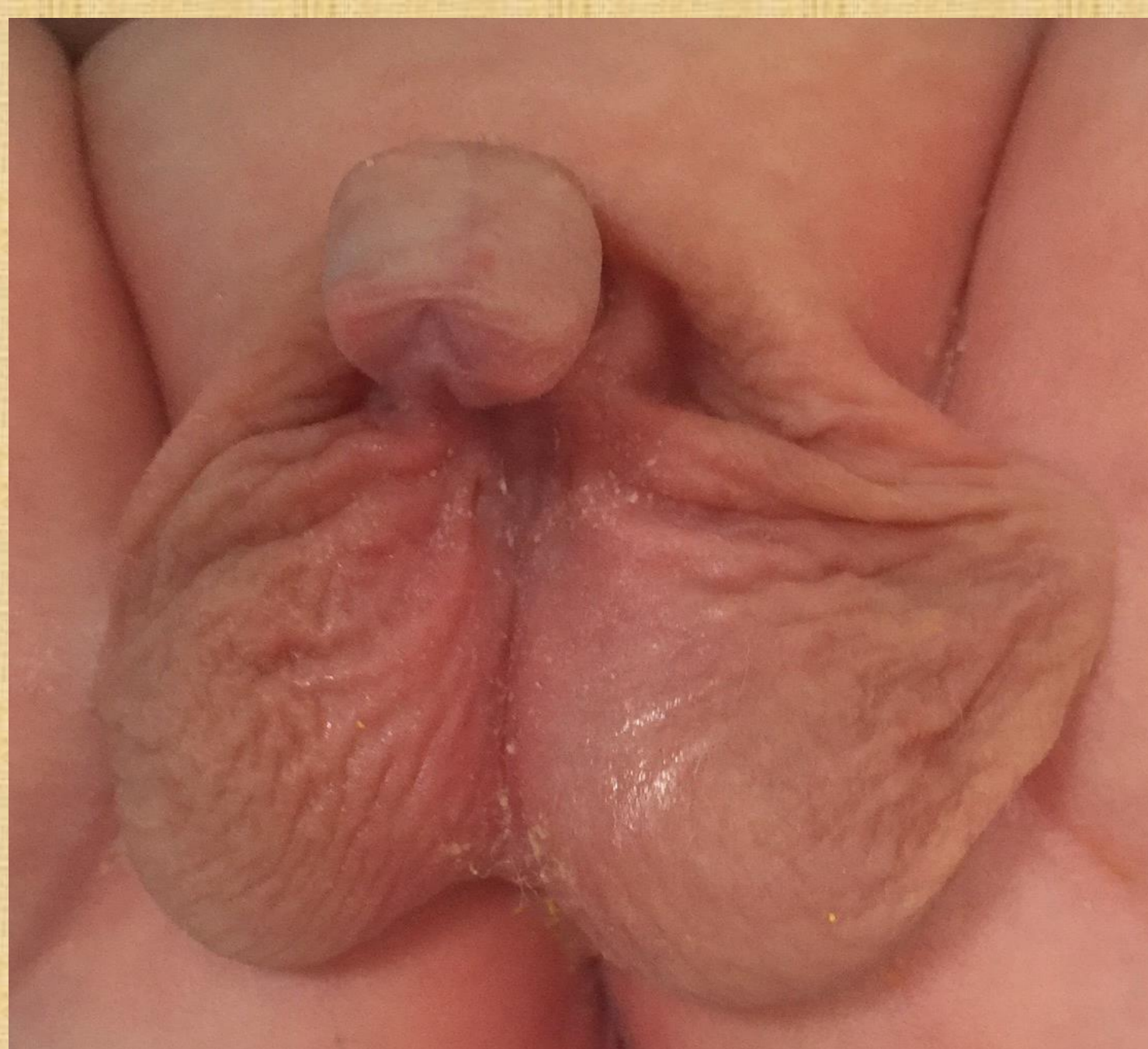

Figure 1: External genital appearance of the patient

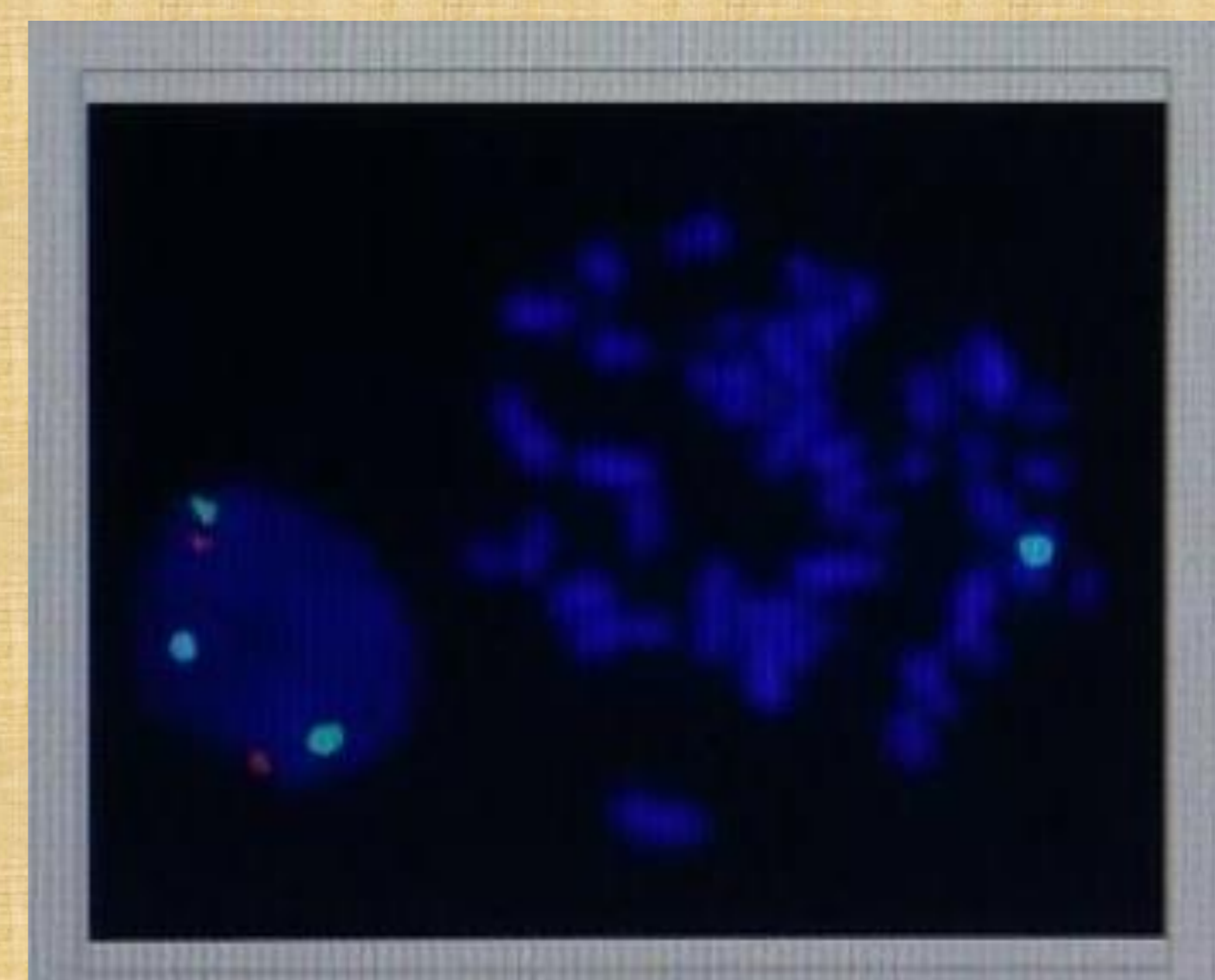


Figure 2: FISH analysis of the patient

Discussion: Mosaic chromosomal constitution 45,X/47,XYY has been rarely reported in fetuses, children, and adults. The first case was published by Jacobs et al in 1961. The phenotypes of 45,X/47,XYY mosaicism are widely variable, ranging from Turner stigmata to apparent normal male characteristics.

In conclusion, karyotype analysis is an important diagnostic tool in DSD patients. A 45,X/47,XYY mosaicism should be kept in mind in DSD patients and needs a careful evaluation because of its phenotypic heterogeneity.