

# An Infant with 49XXXXY Syndrome; A case report from Sri Lanka

Atapattu N<sup>1</sup>, Liyanage C<sup>2</sup>, Naotunna C<sup>1</sup>

<sup>1</sup>Endocrinology and Diabetic Unit, Lady Ridgeway Hospital, Colombo

<sup>2</sup>Paediatric unit, Provincial General Hospital, Badulla

## INTRODUCTION

49XXXXY Syndrome is a rare chromosomal aneuploidy with few hundred case reports published all over the world. The classic triad of symptoms includes mental retardation, hypogonadism and radioulnar synostosis with several other congenital malformations, associated medical conditions and psychological impact.

To the best of our knowledge it has never been reported in Sri Lanka previously.

## PRESENTING CONCERNS

This, day 10 old neonate who was born in a tertiary care center was referred due to detection of ambiguous genitalia at birth.

He was the 1<sup>st</sup> child born to healthy non consanguineous Tamil parents from Badulla district. At the time of conception mother was 31 years and she had an uneventful antenatal period with normal antenatal scans except for a low estimated foetal weight.

He was born at term via normal vaginal delivery with a birth weight of 2.385kg, length 47 cm and OFC 32cm. APGAR score at birth was 1<sup>5</sup>10<sup>10</sup>.

No documented evidences of neonatal hypoglycaemia and baby didn't have jaundice. During the hospital stay baby was well fed and his serum electrolyte levels, serum calcium levels remained normal throughout.

## CLINICAL FINDINGS

On day 10 of examination

•body weight: 2.190kg (8% weight loss)

•length: 48cm

•OFC: 32 cm

•Hypertelorism

•Upslanting palpebral fissures

•Flat occiput

•Mild webbing of neck

•No midline defects

•No generalized pigmentation of body

•System examination: normal

•Genitalia examination : bifid scrotum

perineal urethra

2cm phallus

bilateral testis insitu.

## INVESTIGATIONS

•Serum Electrolytes: Normal

•Thyroid function tests: Normal

•DHEAS: 1.26mmol/L level (normal)

• Serum testosterone: 6.3nmol/l level ( normal)

• 17-OHP: 12.352nmol/L level (normal)

•Serum FSH level: 22.59 IU/L (elevated)

• Serum LH level: 12.69 IU/L (normal)

•Ultrasound abdomen,scrotum: normal adrenal glands, no persistent mullerian structures

•X-ray forearm and wrist: no radiological evidences of radio ulnar synostosis

•Karyotype: chromosomal aneuploidy of 49XXXXY syndrome

•2D echocardiogram: an insignificantly small patent foramen ovale with otherwise normal heart

## DISCUSSION

In 1960 Fraccaro et al reported the first case of 49XXXXY Syndrome. It is the rarest X chromosome aneuploidy with an approximate incidence of 1: 85,000 – 100,000 male births. Non-disjunction of X chromosomes during both meiosis I and II is the probable chromosomal anomaly leading to 49XXXXY syndrome.

Initially this was considered as a variant of Klinefelter syndrome, but the prevalence of moderate to severe mental retardation with a low Intelligence Quotient and multiple associated malformations in 49XXXXY syndrome demarcates the differences between these 2 clinical entities.

The classic triad of symptoms include mental retardation, hypogonadism and radioulnar synostosis though our patient did not have the latter finding. Other clinical manifestations include microcephaly with short stature, distinct facial features such as round face, ocular hypertelorism, upslanting palpebral fissures and flat nasal bridge, cleft palate, musculoskeletal defects such as genu valgum, pes cavus or planus, clinodactyly, scoliosis, hip dysplasia and hypotonia, congenital heart defects; patent ductus arteriosus being the commonest; and delayed neurocognitive development with low IQ levels. Also they are more susceptible to infections and immunodeficiency.

Only one case reported the presence of diabetes in an 18 year old 49XXXXY patient though diabetes is common among Klinefelter syndrome.

Behavioural and development aspects in view of 49XXXXY has been studied widely and many elderly patients with this syndrome had emotional lability, low frustration level and shyness, occasionally irritable, temper tantrums and resistance to change routine. Marked delay was noted in language and speech development with a marked discrepancy between language expression and comprehension. Our presenting child already had speech delay and he needs further follow up for assessment.

Hypergonadotrophic hypogonadism needs to be evaluate at the age of puberty and hormone replacement therapy with IM testosterone should be initiated granting endocrinology follow up.

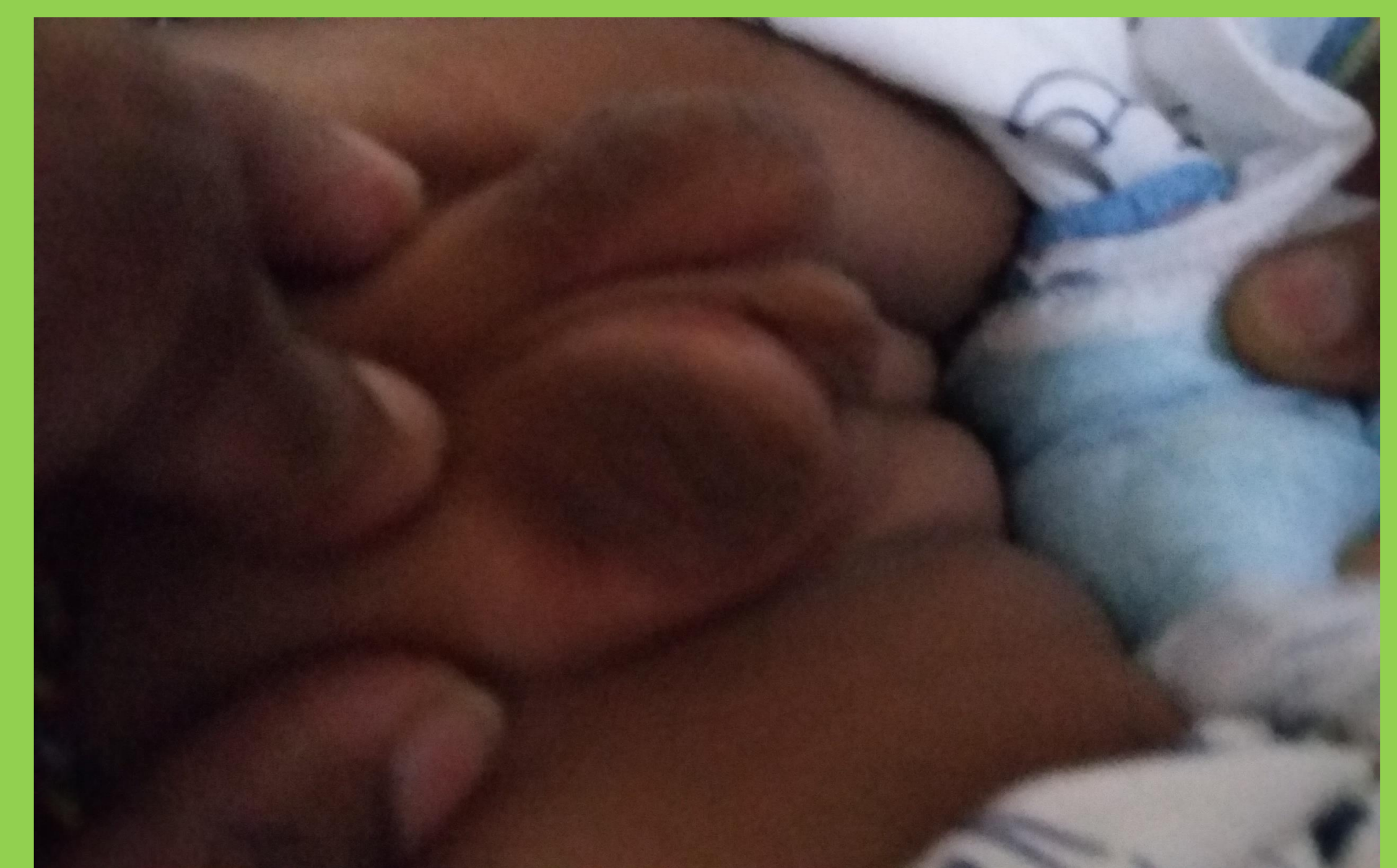


Figure1: Genitalia of index case

## References

- <sup>1</sup>Fraccaro M, Kaijser K, Lindsten GJA. Child with 49 chromosomes. Lancet 1960;2:899-902.
- <sup>2</sup>Tartaglia N, Ayari N, Howell S et al. 48,XXYY, 48,XXXY and 49,XXXXY syndromes: not just variants of Klinefelter syndrome. Acta Paediatr . 2011 June ; 100(6): 851–860.
- <sup>3</sup> Leal CA, Belmont JW, Nachtman R, Cantu JM, Medina C. Parental origin of the extra chromosomes in polysomy X. Hum Genet 1994;94:423-6.
- <sup>4</sup>Hassold T, Pettay D, May K, Robinson A. Analysis of non-disjunction in sex chromosome tetrasomy and penta-somy. Hum Genet 1990;85:648-50.
- <sup>5</sup>Karsh R, Knapp R, Nora J et al. Congenital heart disease in 49,XXXXY Syndrome. Pediatrics 1975;56:462-64
- <sup>6</sup> Lomelino CA, Reiss AL. 49, XXXXY syndrome: behavioral and developmental profiles. J Med Genet 1991;28:609-12.
- <sup>7</sup>Kim H.J, Kim D, Shin J M et al. 49,XXXXY syndrome with Diabetes Mellitus. Horm Res 2006;65:14–17

