

MIXED GONADAL DYSGENESIS: Patients from Instituto da Criança, HC-FMUSP

Ferreira MR; Pinheiro CTC; Queiroz ES; Brigatti NL; Ito S; Steinmetz L; Cominato L; Setian N, Dichtchekian V; Menezes Filho HC; Manna TD; Damiani D

Instituto da Criança - Hospital das Clínicas da Faculdade de Medicina da Universidade de São Paulo

Disclosure statement: nothing to declare

INTRODUCTION and OBJECTIVES

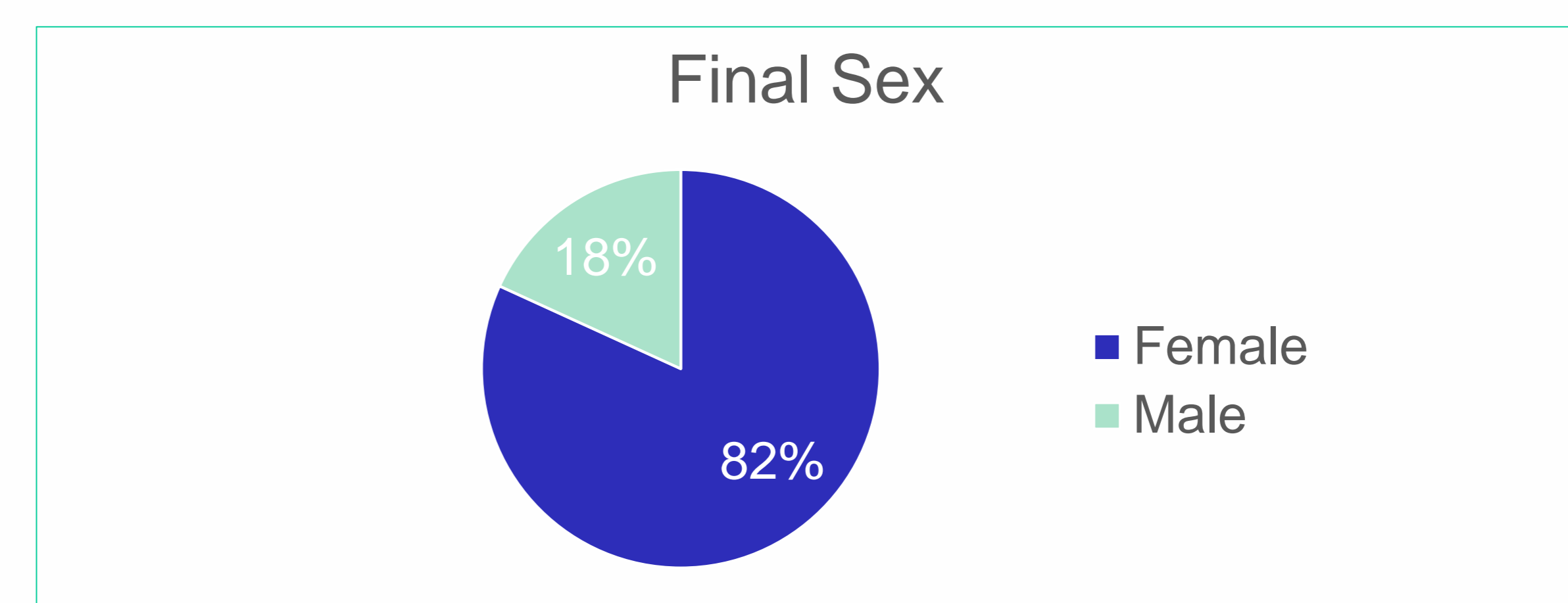
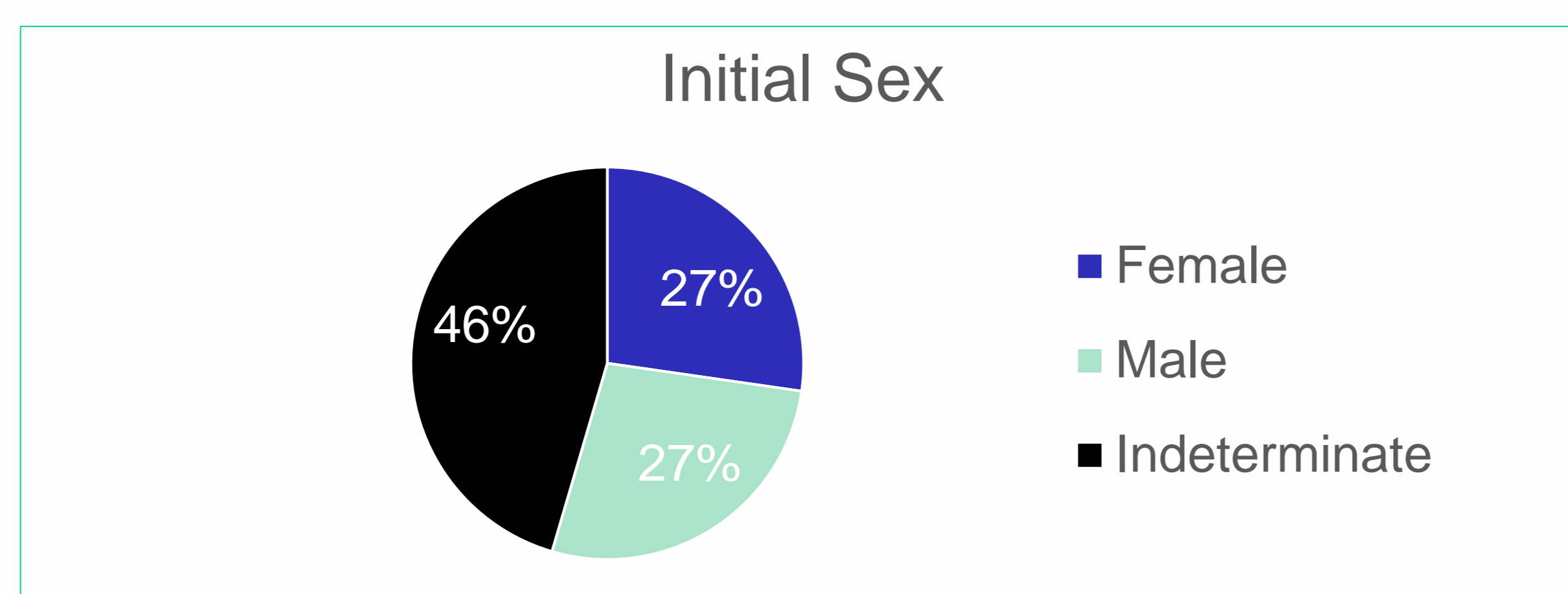
Mixed gonadal dysgenesis (MGD) is a heterogeneous group of gonadal, chromosomal and phenotypic abnormalities¹. The diagnosis is based on the presence of testicular tissue and streak. The sex chromosome mosaicism 45,X/46,XY is the most common karyotype expressed in MGD², but other karyotypes have been described. It is a condition occurring in 1.5/10,000 livebirths.³ The aim of this paper is to report a group of MGD patients followed up in our hospital.

METHODS

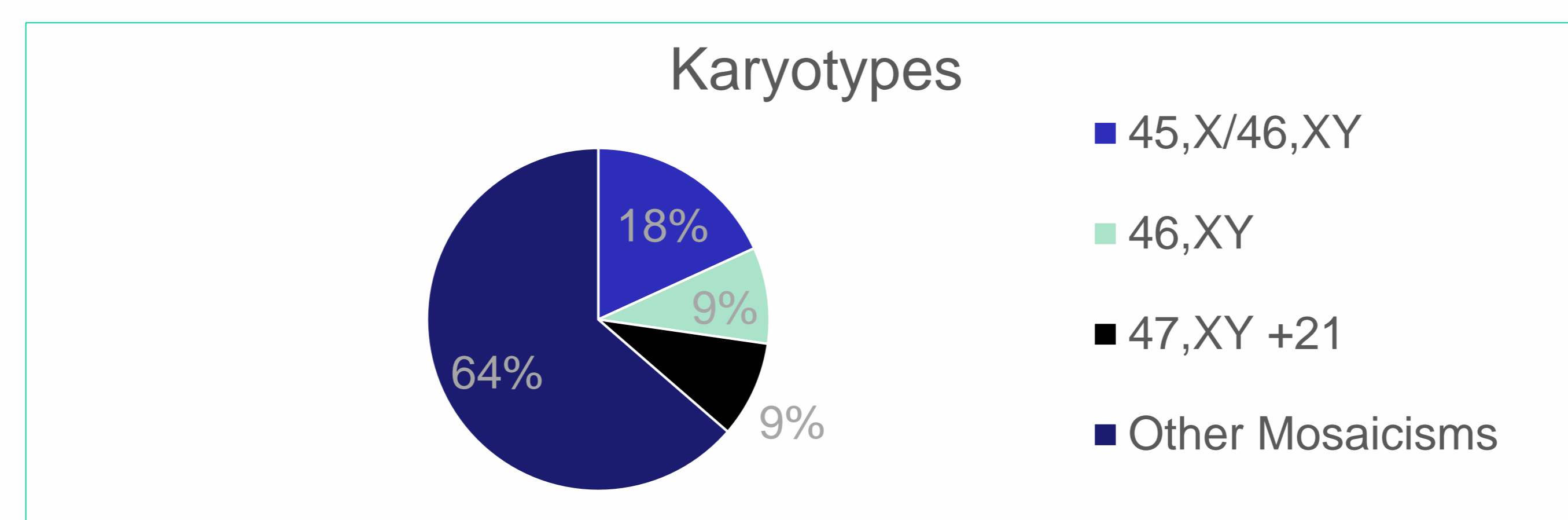
We conducted a retrospective analysis by gathering clinical data from the medical records. These data consisted on age at first evaluation, initial and final sex of rearing, characteristics of external genitalia, presence of Müllerian tissue remnants, karyotype and testosterone levels. The criteria of inclusion in the study was the presence of streak and testicular tissue (normal or dysgenetic) in gonadal biopsy.

RESULTS

From 15 patients initially suspected to have MGD, we remained with 11 patients who fulfilled the inclusion criteria. The age at first visit ranged from two weeks to 14.1 years, mean 2.3 years. Birth weights ranged from 1705g to 3400g. Five patients had no definite sex at first visit, three were female and three male. From the male patients, one was raised as female. Among those of indeterminate sex, all five were raised as females.



The karyotypes were: 45,X/46,XY in two patients, 45,X/46,X + marY in 2 patients, in addition to other mosaicisms.



The presence of Mullerian derivatives was reported in 10 patients. One of our patients did not have uterus but the histological examination showed streak on one side and testis on the other side.

Upon examination of the external genitalia, 11 patients had perineal urethra. Falus size ranged between 1.5 and 3 cm, with presence of unilateral palpable gonad in three patients. All patients had ambiguous genitalia. The average response of testosterone after hCG stimulation was 270.6 ng/dL.

CONCLUSION

The DGM should be considered among the etiologies of genital ambiguity, despite the rare occurrence. Although 45,X/46,XY is the commonest karyotype, 46,XY and other mosaicisms can be found. The range of ages at first appointment had wide variation, calling attention to the fact that many children with ambiguous genitalia have not been referred to specialized clinic in due time. As has been reported in the medical literature, most of the patients are raised as females.

REFERENCES

1. Maciel-Guerra AT, Guerra-Júnior G. Menino ou menina? Os distúrbios da diferenciação do sexo. São Paulo: Editora Manole Ltda., 2010.
2. Soheilipour, F. et al. A rare case of mixed gonadal dysgenesis with mosaicism 45, X/46, X, +mar. International Journal of Surgery Case Reports, v. 7, p. 35-38, 2015.
3. Mouafo Tambo, F. et al. Mixed gonadal dysgenesis in Yaoundé: A preliminary experience about three cases. African Journal of Paediatric Surgery, v. 13, n. 3, p. 145, 2016.
4. Lee PA, Mazur T, Danish R et al. Micropenis I: Criteria, etiologies and classification. Jphns Hopkins Med J 146:156, 1980.