

# A new case of intragenic deletion in IGF1R with very mild phenotype

Ruggero Coppola<sup>1</sup>, Anna Grandone<sup>1</sup>, Caterina Luongo<sup>1</sup>, Raffaella Nacca<sup>1</sup>, Marcella Sasso<sup>1</sup>, Emanuele Miraglia del Giudice<sup>1</sup>, Laura Perrone<sup>1</sup>

<sup>1</sup>Department of Woman, Child, General and Specialized Surgery, Second University of Naples, Naples, Italy

## Background

IGF1R mutations are characterized by IGF-1 resistance causing impaired fetal and postnatal growth. Several reports in children with heterozygous defects of IGF1R have demonstrated a variable phenotype, which can be associated to microcephaly, dysmorphic features and mild developmental delay.

## Case presentation

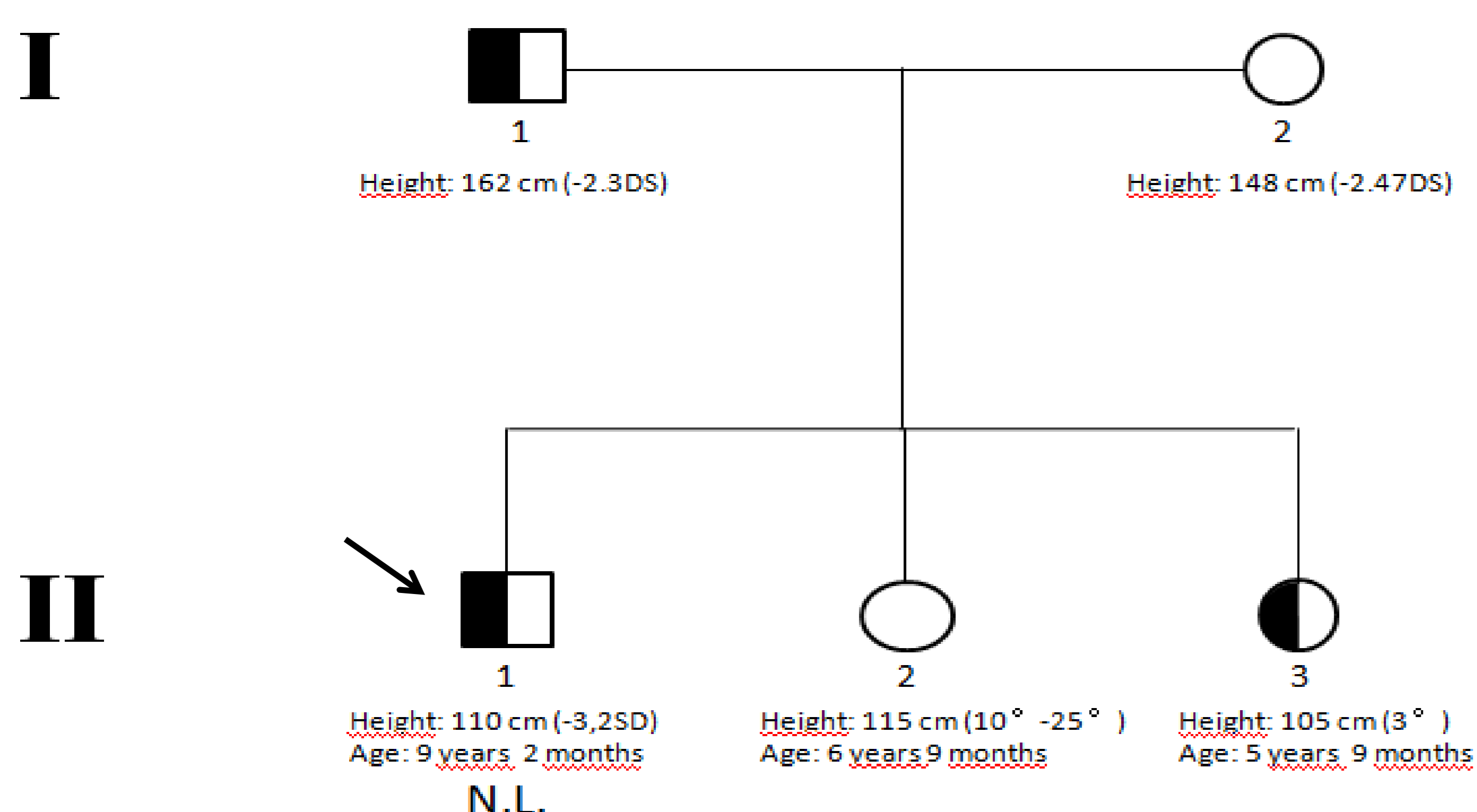
We report of an 8 years old boy, who came at our observation with short stature (- 3.2 SDS) and mild microcephaly (- 2 SDS). He was born SGA (weight - 2.05 SDS; length - 1.5 SDS; head circumference - 1.9 SDS) and familial medical history revealed short stature in both parents (target height - 2.4 SDS). Psychomotor development was normal. His bone age evaluated by TW2 method was 6 years. His basal IGF1 levels were normal (219.1 ng/mL; IGF1-RIACT Cisbio assays 95<sup>th</sup>: 261 ng/mL) and stimulation test with arginine excluded a GH deficiency (peak of GH: 16.3 ng/dL).

GH treatment (0.035 mg/Kg/die) was started, but it has been stopped after one year of therapy because of elevated IGF-1 levels (372.2 ng/mL; IGF1-RIACT Cisbio assays 95<sup>th</sup>: 261 ng/mL).

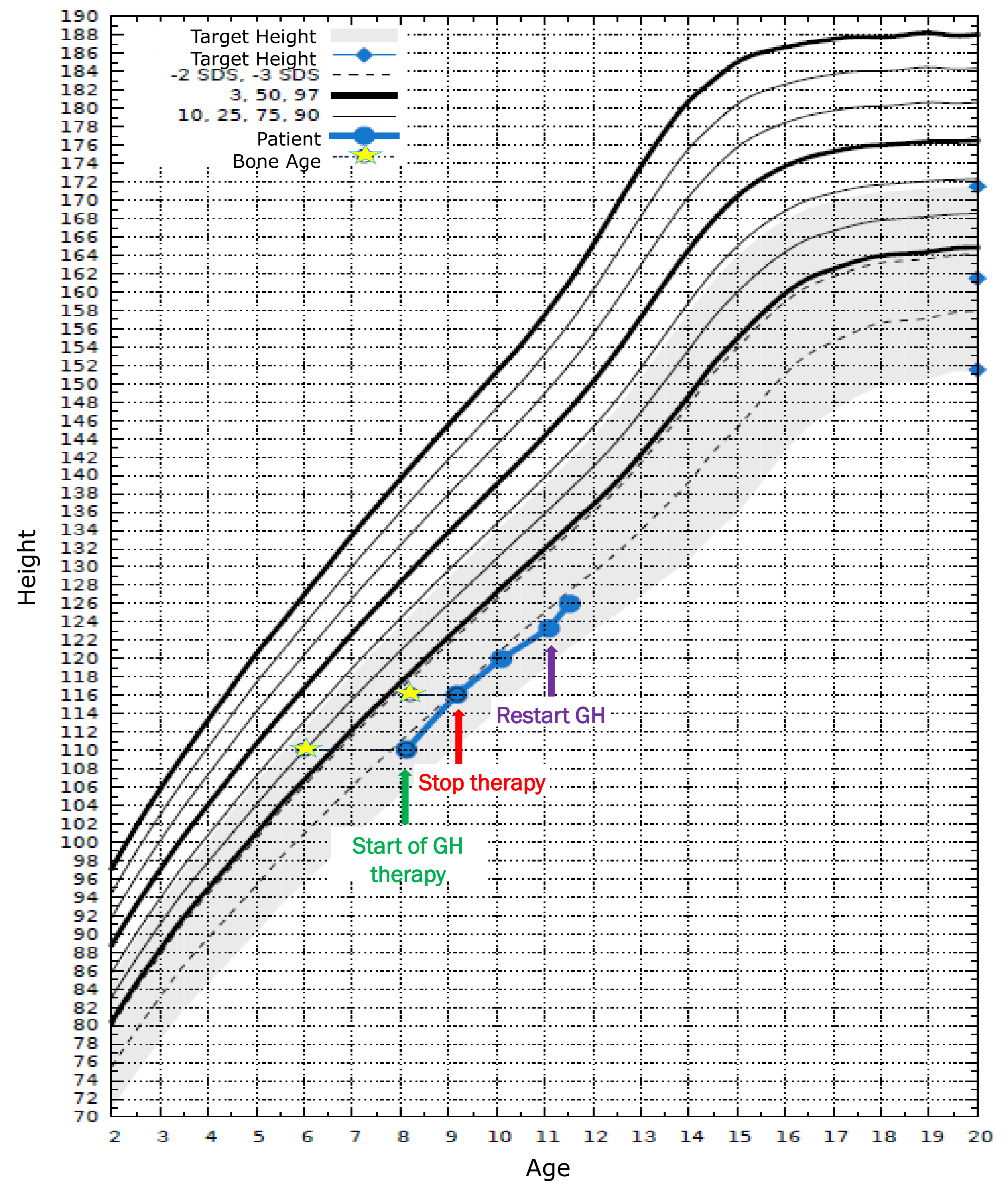
Genetic analysis through direct sequencing (DNA Analyzer Applied Biosystems) and MLPA (MRC Holland: SALSA P217-B2) of IGF1R revealed an heterozygous deletion of exon 3; the same deletion was found in the father (adult height -2.2 SDS) and in one of the two sisters (born SGA, at birth: weight - 2.7 SDS; height -2.8 SDS; head circumference -2 SDS) of the index case, as shown in Picture 1. Both affected relatives had normal psychomotor development. Our patient started GH treatment again at a higher dosage (0.040 mg/kg/die), with good response (growth velocity: +1.9 SDS in 5 months of treatment).

Growth chart of our patient is shown in Picture 2.

Picture 1. Genealogical tree of our family



Legend: half-filled symbols show affected subjects



Picture 2. Growth chart of our patient

## Discussion

We expand the phenotypic knowledge of intragenic deletions of IGF1R reporting a family with deletion of exon 3, determining a mild phenotype. Only a family with exon 3 deletion has been previously described and dysmorphic features, psychiatric phenotypes (hyperactivity, aggressive and autoaggressive behaviour) and mental delay were present in all affected members. In our family, no patient with the IGF1R mutation presented mental retardation, these psychiatric features and dysmorphisms. The explanation of these differences warrants further investigation. Moreover we confirm the importance of performing IGF1R analysis in SGA patients with short stature and microcephaly poor responsive to GH treatment.

## References

- Klammt J, Kiess W, Pfaeffle R. IGF1R mutations as a cause of SGA. *Best Pract Res Clin Endocrinol Metab.* (2011) 25: 191-206
- Jens Witsch, Przemyslaw Szafranski, Chun-An Chen, LaDonna Immken, Gayle Simpson Patel, Patricia Hixson, Sau Wai Cheung, Pawel Stankiewicz and Christian P Schaaf. Intragenic deletions of the IGF1 receptor gene in five individuals with psychiatric phenotypes and developmental delay. *European Journal of Human Genetics* (2013) 21: 1304-1307

We have no conflict of interest to declare

